

Bilateral Metachronous Osteosarcoma of the Mandibular Body: A Case Report

Faramarz Babazade, DDS; Hamed Mortazavi¹, DDS; Hamed Jalalian², DDS

Osteosarcoma of the jaw (JOS) is a rare phenomenon constituting 5% to 13% of all cases of osteosarcoma (OS). JOS has histological features similar to OS, but the biological behavior is different. The chief complaint of patients with long bone OS is pain, whereas patients with JOS usually have painless swelling as the first sign. OS may affect multiple sites. Multifocal or multicentric osteosarcoma is usually defined as metachronous (new tumors developing after initial treatment) or synchronous (multiple lesions at presentation) without pulmonary metastases. The incidence of this entity has been reported to be between 1% and 10% of all cases of OS. A 27-year-old man presented with bilateral metachronous osteosarcoma as painful swellings in the mandibular body. He was treated with a mandibulectomy and chemotherapy. Therefore, the physician should be aware that osteosarcomas can occur in different sites as true multicentric or metastatic lesions. (*Chang Gung Med J 2011;34(6 Suppl):66-9*)

Key words: osteosarcoma, bilateral, mandible, metachronous

After hematopoietic intraosseous neoplasia, osteosarcoma is the most common primary malignant bone tumor, at an estimated incidence of two cases per 1,000,000 persons per year.⁽¹⁾ However, osteosarcoma of the jaw (JOS) is a rare phenomenon constituting 5% to 13% of all cases of osteosarcoma (OS). JOS has histological features similar to OS but the biological behavior is different.⁽²⁾ Osteosarcoma may affect multiple sites. This entity (multifocal or multicentric osteosarcoma) was first described by Silverman in 1936.^(3,4) It is usually defined as metachronous (new tumors developing after initial treatment) or synchronous (multiple lesions at presentation) without pulmonary metastases.⁽³⁾ When more than one osteosarcoma lesion occurs in the skeleton it may be related to either metastases or formation of multicentric tumors. Therefore, the aim of this article was to present a case of bilateral osteosar-

coma of the mandibular body without lung metastases.

CASE REPORT

A 27-year-old man with painful swelling in the right mandibular body was referred to the Department of Oral and Maxillofacial Surgery of Mashad Dental School. The patient had noticed a slowly growing mass for two months, and also complained of paresthesia on the right side of the chin. Physical examination revealed a firm, bony, 6 x 4 cm² mass on the right cheek. The maximum mouth opening was 27 mm. Computed tomography (CT) of the head revealed a 7 x 4 x 4 cm³ osteolytic lesion over the right mandibular body region involving both the inner and outer cortices with mixed linear radiolucent and radiopaque areas forming a sunburst

From the Department of Oral and Maxillofacial Surgery Dental School, Mashhad University of Medical Sciences, Mashhad, Iran; ¹Department of Oral Medicine, Dental School, Shahid Beheshti University of Medical Sciences, Tehran, Iran; ²Department of Oral and Maxillofacial Surgery, Dental School, Zahedan University of Medical Sciences, Zahedan, Iran.

Received: Mar. 5, 2010; Accepted: Nov. 5, 2010

Correspondence to: Dr. Hamed Mortazavi, Department of Oral Medicine, Dental School, Shahid Beheshti University of Medical Sciences, Tehran, Iran; Evin, 198369411, Tehran, Iran. Tel: +98-21-22403194;

Fax: +98-8118354220; E-mail: Mortazavi@UMSHA.ac.ir; mortazavi57@yahoo.com

appearance (Fig. 1). His initial chest radiograph and blood tests showed no abnormalities except for high levels of serum alkaline phosphates. After an incisional biopsy, microscopic examination confirmed the diagnosis of chondroblastic osteosarcoma (cellular hyaline cartilage and malignant osteoid in a myxomatous stroma (Fig. 2). The patient had resection of the mass by hemimandibulectomy with an extraoral access, and the facial nerve was also preserved. The surgical plane in the tumor resection included a 2 cm safe margin. The free margin was confirmed with a frozen section intraoperatively and the jaw was reconstructed with a reconstruction plate (Fig. 3). Post-operative adjuvant chemotherapy consisting of doxorubin, cisplatin, adriamycin and high dose

methotrexate was administered. A whole body scan did not show evidence of abnormalities. Thirteen months later, the patient noticed a second rapidly growing, painful mass on the left mandibular body. An orthopantomogram did not show a diagnostic appearance but a CT scan showed a 6 x 4 x 3 cm³ lesion over the left mandibular body region without a sunburst appearance (Fig. 4). Chest radiography did not show any abnormalities. After clinical and para-clinical assessments, an incisional biopsy was obtained and the histopathologic findings confirmed a diagnosis of chondroblastic osteosarcoma. A whole body scan was negative for abnormalities. The mandibular mass was excised. In the second surgery, the previous plate was completely replaced by a

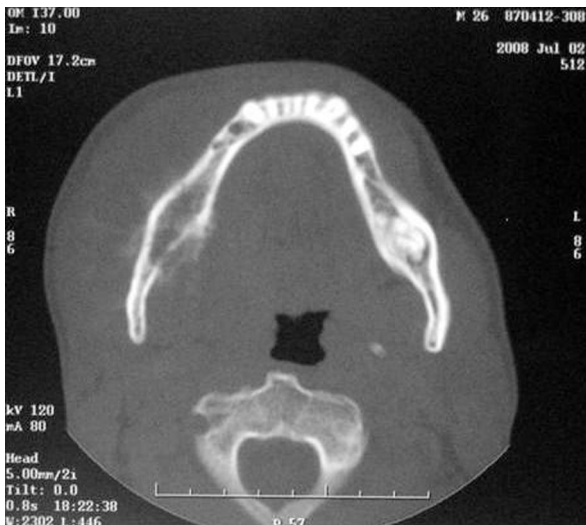

Fig. 1 Computed tomography scan shows involvement of the right side of the mandible with a sunburst appearance.

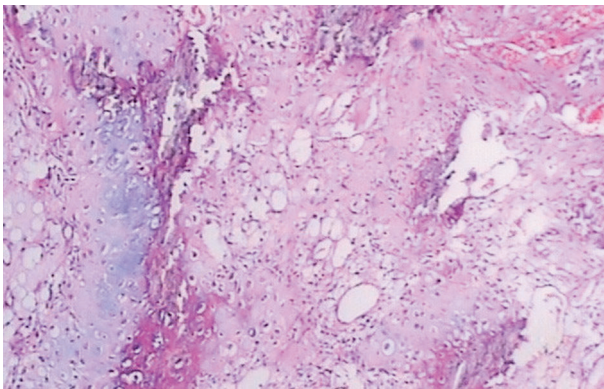


Fig. 2 Microscopic examination shows cellular hyaline cartilage and malignant osteoid in a myxomatous stroma.

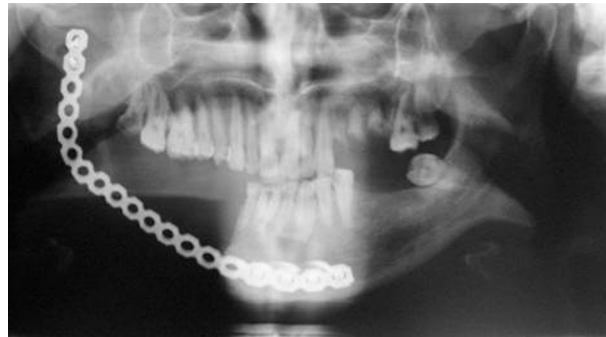

Fig. 3 Postoperative panoramic radiograph demonstrating reduction of the affected region on the right side of the mandible.

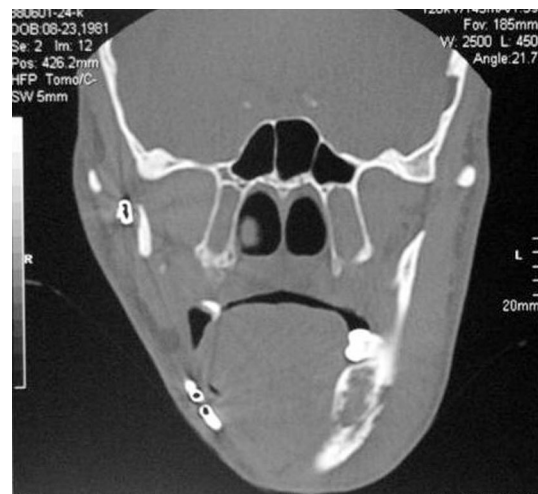


Fig. 4 Computed tomography shows intramedullary involvement of the left side of the mandible after several months.

longer reconstruction plate which included the condylar process (Fig. 5). Chemotherapy was repeated according to the previous protocol. One month after 2nd surgery, the patient is clinically well and has no radiological signs of recurrence.

DISCUSSION

The jaws represent approximately 0.86% of the total body volume and are affected by about 7 percent of all osteosarcomas. Therefore, understanding the nature of JOS is important.^(2,5,6) Long bone osteosarcoma usually occurs in the second decade whereas, JOS occurs between the third and fourth decades.^(1,6,7) The Table summarizes some differences between jaw and long bone osteosarcoma.⁽¹⁾ In Mardinger et al's study, the mean age of patients with JOS was 33 years (range 8 to 78 years).⁽²⁾ Primary osteosarcoma in patients younger than 18 is rare.⁽³⁾ A review of patients with JOS showed the peak age for mandibular lesions was in the second decade of life and for maxillary lesions, between the

third and fifth decades.⁽⁶⁾ Nissanka et al demonstrated that mandibular osteosarcoma is more common than maxillary lesions. In contrast to this finding, a higher prevalence in the maxilla was reported by Clark et al.^(6,7) Males seem to be more affected.⁽⁵⁾ In the reviews of JOS by Mardinger et al and Nissanka et al, there was a male predilection, with a male/ female ratio of 1.2: 1.0 and 1.1: 1.0, respectively.^(2,6) The chief complaint of patients with long bone osteosarcoma is pain, whereas painless swelling is usually the first sign in patients with osteosarcoma of the jaws.⁽⁸⁾ A review of the literature showed, 85% to 95.5% of patients with JOS had swelling, either painful (45.8% to 50%) or painless (35% to 49.7%).⁽⁹⁻¹¹⁾ Other complaints included paresthesia (in 21.2% of cases), displacement of teeth, epistaxis, eye problems, nasal obstruction and weight loss.^(2,5,11,12) Nakayama et al described four radiographic patterns for osteosarcomas, osteolytic, osteolytic dominant, osteogenic dominant and osteogenic.⁽¹³⁾ The sunburst appearance can be better appreciated in jaw lesions and appears in approximately 25% of cases.^(3,8) Lindquist demonstrated that widening of the inferior alveolar canal and periodontal ligament space, together with a sunburst appearance, is almost pathognomonic of JOS.⁽¹⁴⁾ Chondroblastic osteosarcoma is the most common histologic variant of JOS.⁽²⁾ This type of osteosarcoma is dominated by cellular hyaline cartilage and shows a few wisps of osteoid formation.⁽¹⁾ The pathogenesis of osteosarcoma is related to amplifications or mutations of one or more genes. Also, osteosarcoma may be associated with other bone diseases and conditions such as Paget's disease and fibrous dysplasia.^(2,6) It seems that growth has an important role as an etiologic factor in osteosarcoma of the long bones but is not a major

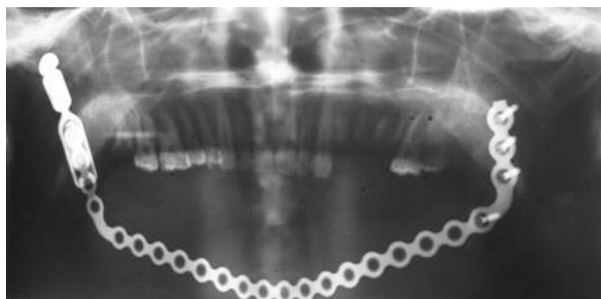


Fig. 5 Final postoperative panoramic radiograph demonstrating reduction of the newly affected region on the left side of the mandible.

Table Differences between Jaw and Long Bone Osteosarcoma

Jaw osteosarcoma	Long bone osteosarcoma
Rare malignancy constituting 5% to 13% of all osteosarcomas. ⁽²⁾	Second most common primary malignant bone tumor. ⁽⁶⁾
Occurs between third and fourth decades. ⁽⁸⁾	Peak incidence in second and third decades. ⁽¹⁾
Painless swelling is most common complaint ⁽²⁾	Pain is most common complaint. ⁽²⁾
Neurosensory disturbance more common than in skeletal osteosarcoma. ⁽²⁾	Neurosensory disturbances not a major sign or symptom. ⁽²⁾
Lower incidence of high-grade malignancy. ^(16,17)	Most cases have high-grade malignancy. ⁽¹⁸⁾
Better prognosis than long bone osteosarcoma. ^(16,17)	Poorer prognosis than jaw osteosarcoma. ^(16,17)
Distant metastasis is rare. ⁽²⁾	Distant metastasis is common. ⁽²⁾

etiologic factor in JOS because JOS usually occurs one or two decades after adolescence.⁽²⁾ Some studies have demonstrated that osteosarcoma sometimes occurs as a multifocal or multicentric lesion, called synchronous or metachronous osteosarcoma.⁽³⁻⁵⁾ The incidence of this entity has been reported to be between 1% and 10% of all cases of OS.⁽⁴⁾ In our patient, osteosarcoma occurred in the same bone on opposite sides. Reasons for this entity include 1) formation of multiple primary tumors, 2) spreading of tumor cells along the bone marrow space or mandibular canal and 3) hematogenous dissemination from a primary tumor.^(2,5,6) These can be considered etiologic factors in the bilateral osteosarcoma in our reported case. The accepted treatment for JOS is radical surgery and in the mandible, hemimandibulectomy is commonly performed. Also, if cervical lymph nodes are involved, neck dissection must be considered. Smeele et al demonstrated that survival rates of patients with craniofacial osteosarcoma significantly improve with chemotherapy.⁽¹⁵⁾ But, it was also noted that chemotherapy does not improve the prognosis of JOS. Therefore, adjuvant therapy was determined based on the experience of the oncologists and surgeons.^(2,6) In conclusion, a physician should be aware that osteosarcomas can occur in different sites as true multicentric or metastatic lesions.

REFERENCES

1. Klein MJ, Siegal GP. Osteosarcoma: anatomic and histologic variants. *Am J Clin Pathol* 2006;125:555-81.
2. Mardinger O, Givol N, Talmi YP, Taicher S. Osteosarcoma of the jaw. The Chaim Sheba Medical Center experience. *Oral Surg Oral Med Oral Pathol Oral Radiol Endod* 2001;91:445-51.
3. Behere R, Lele S. Synchronous osteosarcoma of mandible. *Oral Surg Oral Med Oral Pathol Oral Radiol Endod* 2009;107:e45-9.
4. Daffner RH, Kennedy SL, Fox KR, Crowley JJ, Sauser DD, Cooperstein LA. Synchronous multicentric osteosarcoma: the case for metastases. *Skeletal Radiol* 1997;26:569-78.
5. Stroncek GG, Dahl EC, Fonseca RJ, Benda JA. Multiosseous osteosarcoma involving the mandible: metastatic or multicentric? *Oral Surg Oral Med Oral Pathol* 1981;52:271-6.
6. Nissanka EH, Amaratunge EA, Tilakaratne WM. Clinicopathological analysis of osteosarcoma of jaw bones. *Oral Dis* 2007;13:82-7.
7. Clark JL, Unni KK, Dahlin DC, Devine KD. Osteosarcoma of the jaw. *Cancer* 1983;51:2311-6.
8. Garrington GE, Scofield HH, Cornyn J, Hooker SP. Osteosarcoma of the jaws. Analysis of 56 cases. *Cancer* 1967;20:377-91.
9. Caron AS, Hajdu SI, Strong EW. Osteogenic sarcoma of the facial and cranial bones. A review of forty-three cases. *Am J Surg* 1971;122:719-25.
10. August M, Magennis P, Dewitt D. Osteogenic sarcoma of the jaws: factors influencing prognosis. *Int J Oral Maxillofac Surg* 1997;26:198-204.
11. Givol N, Buchner A, Taicher S, Kaffe I. Radiological features of osteogenic sarcoma of the jaws. A comparative study of different radiographic modalities. *Dentomaxillofac Radiol* 1998;27:313-20.
12. Chen YK, Lin LM. Radiographic changes to mandibular canal in osteogenic sarcoma. *Oral Surg Oral Med Oral Pathol* 1992;74:128.
13. Nakayama E, Sugiura K, Ishibashi H, Oobu K, Kobayashi I, Yoshiura K. The clinical and diagnostic imaging findings of osteosarcoma of the jaw. *Dentomaxillofac Radiol* 2005;34:182-8.
14. Lindqvist C, Teppo L, Sane J, Holmström T, Wolf J. Osteosarcoma of the mandible: analysis of nine cases. *J Oral Maxillofac Surg* 1986;44:759-64.
15. Smeele LE, Kostense PJ, Van Der Waal I, Snow GB. Effect of chemotherapy on survival of craniofacial osteosarcoma: a systemic review of 201 patents. *J Clin Oncol* 1997;15:363-7.
16. Batsakis JG. Osteogenic and chondrogenic sarcomas of the jaws. *Ann Otol Rhinol Laryngol* 1987;96:474-5.
17. Agust M, Magennis P, Dewitt D. Osteogenic sarcoma of the jaws: factors influencing prognosis. *Int J Oral Maxillofac Surg* 1997;26:198-204.
18. Broders AC. The grading of carcinoma. *Minn Med* 1925;8:726-30.