

## High Origin of An Ulnar Artery – Development and Surgical Significance

Venkata Ramana Vollala, PhD; Raghu Jetty<sup>1</sup>, MSc; Simmi Soni<sup>2</sup>, MSc

Variations in the main arteries of the upper limb are common and these anomalies can be of substantial interest to orthopedic surgeons, plastic surgeons, radiologists and anatomists. We present here a case of a high origin of the ulnar artery from the brachial artery found during anatomical dissection of a right upper limb of a 50-year-old man. This superficial ulnar artery, after running over the bicipital aponeurosis in the cubital fossa superficial to the flexor muscles in the forearm terminated as the superficial palmar arch in the hand. The embryological and clinical importance of the anomalous ulnar artery is discussed. (*Chang Gung Med J 2011;34(6 Suppl):39-42*)

**Key words:** ulnar artery, upper limb, brachial artery, superficial palmar arch

The ulnar artery is the larger terminal branch of the brachial artery and is usually given off in the cubital fossa. It crosses deep under the median nerve and passes obliquely downward and medially, covered by the pronator teres, flexor carpi radialis, palmaris longus and flexor digitorum superficialis muscles in the proximal half of the forearm. In the distal half of the forearm, it proceeds between the flexor carpi ulnaris and flexor digitorum superficialis muscles, being covered by the skin and fascia. The artery ends anterior to the flexor retinaculum by dividing into two terminal branches. The superficial one forms the superficial palmar arch (SPA) with a contribution from the superficial branch of the radial artery and the deep branch anastomoses with the radial artery to form the deep palmar arch. The SPA gives palmar digital branches to the medial three fingers and also to the medial half of the index finger. The lateral aspect of the index finger and the thumb normally receive their arterial supply from the radial artery through the radialis indicis and the princeps pollicis arteries, respectively.<sup>(1)</sup> In anomalous cases of

a superficial ulnar artery, sometimes, the ulnar artery descends superficial to the forearm flexor muscles and reaches the wrist lateral to the ulnar nerve. Along with the radial artery, it supplies the structures in the forearm and hand, as well as the elbow and wrist joints.

A superficial ulnar artery (SUA) is an ulnar artery of high origin that lies superficially in the forearm. Its reported frequency ranges from 0.17% to 2%. It usually arises higher up than the SPA, either in the axilla or the arm, and runs a superficial course in the forearm before entering the hand.<sup>(2)</sup>

Although, variations of the upper limb arterial pattern are common, the presence of an ulnar artery of high origin is considered a rare anatomical variation with clinical significance.<sup>(3-6)</sup> Its clinical importance should not be underestimated as several cases of intraarterial injection of drugs and subsequent amputations have been reported.<sup>(7,8)</sup> This report presents a case of unilateral SUA, arising from the brachial artery along with its embryological explanation and clinical significance.

---

From the Department of Anatomy, Rajiv Gandhi Institute of Medical Sciences, Adilabad, Andhra Pradesh, India; <sup>1</sup>Department of Anatomy, Melaka Manipal Medical College (Manipal Campus), Manipal, India; <sup>2</sup>Department of Anatomy, Dr. VRK Women's Medical College, Aziznagar, Moinabad Mandal, RR District, A.P., India.

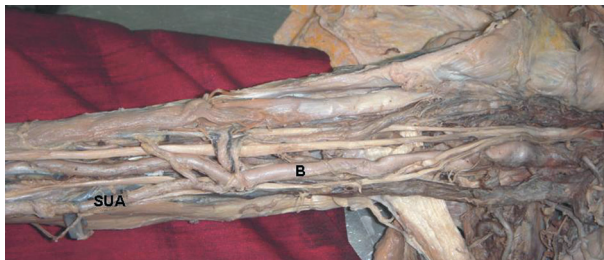
Received: Mar. 29, 2011; Accepted: July 27, 2011

Correspondence to: Dr. Venkata Ramana Vollala, Department of Anatomy, Rajiv Gandhi Institute of Medical Sciences, Adilabad, Andhra Pradesh, India. Tel: +91 9494306083; E-mail: ramana.anat@gmail.com

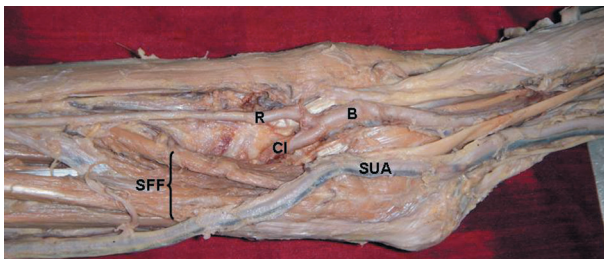
## CASE REPORT

A high origin of an ulnar artery (Fig. 1) was found in the right upper limb of a 50-year-old male cadaver during routine dissection classes for undergraduate medical students. However, the left upper limb showed no abnormalities. Dissections of both upper extremities (right and left) were carried out according to the instructions in Cunningham's Manual of Practical Anatomy.

The ulnar artery arose from the brachial artery in the middle third of the arm (Fig. 1). At the elbow level, the artery ran superficial to the bicipital aponeurosis where it was crossed by the median cubital vein. After that, the artery coursed downwards and slightly medially, superficial to the forearm flexor muscles, over the antebrachial fascia and under the superficial venous system to reach the distal third of the forearm, where it was seen on the lateral side of flexor carpi ulnaris close to the ulnar nerve (Fig. 2). The artery then passed anterior to the flexor retinaculum where it divided into two terminal branches. The superficial one formed the superficial palmar arch without any contribution from the radial



**Fig. 1** Dissection of the arm of a 50 year-old male cadaver showing a high origin of the ulnar artery. B: brachial artery; SUA: superficial ulnar artery.



**Fig. 2** Variant branching of the brachial artery and abnormal course of the superficial ulnar artery. B: brachial artery; R: radial artery; CI: common interosseous artery; SUA: superficial ulnar artery; SFF: superficial flexor muscles of the forearm.

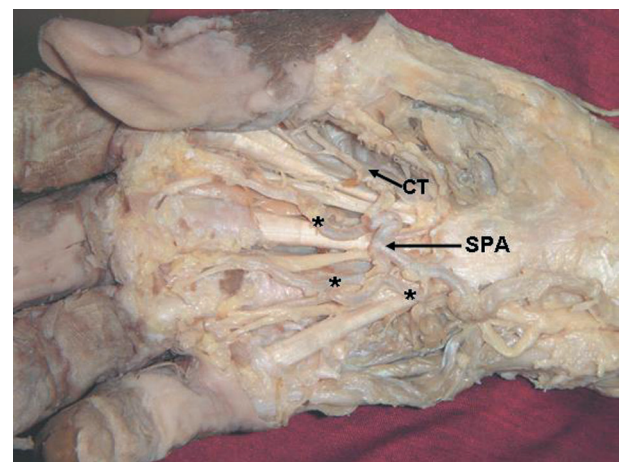
or median arteries and the deep branch anastomosed with the radial artery to form the deep palmar arch. The branching pattern of the SPA was also abnormal. The SPA provided origin to a proper palmar digital artery for the medial side of the little finger, and three common palmar digital arteries for the adjacent sides of the little, middle and ring fingers. It also provided origin to a common trunk which divided into the princeps pollicis and radialis indicis arteries (Fig. 3).

The brachial artery had a normal course in the arm but at the elbow level it divided into the radial and common interosseous arteries (Fig. 2). The superficial ulnar artery was of a larger caliber than both the radial and common interosseous arteries.

## DISCUSSION

Anomalies of the arterial system of the upper limb are not uncommon, as its development is dependent upon multiple sources as well as a precise sequential pattern of formation and regression. These anomalies may be of various types such as variations in the mode of origin or branching pattern, occupation of unusual tissue planes and unexpected relationships with surrounding structures.<sup>(9)</sup>

The superficial course of the ulnar artery described here places it at risk during trauma and intravenous cannulation. This arterial course could also lead to intraarterial injection and difficulties in



**Fig. 3** Photograph showing atypical formation and branching of the superficial palmar arch. SPA: superficial palmar arch; \*: common palmar digital arteries; CT: common trunk for princeps pollicis and radialis indicis arteries.

angiographic procedures.<sup>(10)</sup> It is also at high risk of damage during forearm surgery. Reconstructive surgeries using flaps are becoming increasingly common. Free forearm flaps based on the radial artery may damage the SUA causing ischemia of the hand. Demonstration of patency of the ulnar artery is very important before raising a free radial forearm flap. This can be accomplished by careful palpation of the cubital fossa and ulnar aspect of the forearm, or by Doppler ultrasound examination.<sup>(11)</sup> The importance of this variant is also growing with the increasing use of radial arteries as conduits in coronary bypass.<sup>(12)</sup>

Knowledge of an SUA is also important in the following clinical/surgical interventions: (1) In the present subject the ulnar artery was immediately sub-jacent to the median cubital vein. This would predispose the vessel to inadvertent penetration during attempts at venipuncture of the median cubital vein. The SUA was also closely related to the basilic vein along its course and hence was also at risk of unintended vascular puncture. (2) This is also important in patients who require surgical intervention because of a thrombosed forearm artery and poor collateral circulation. (3) When treating a rupture of the distal bicipital tendon, an orthopedic surgeon should be aware of this atypical blood vessel. (4) The presence of an SUA need not always be regarded as an adverse feature, as its presence may allow plastic surgeons to use it in a reconstructive ulnar flap.<sup>(6)</sup>

When an SUA is present, the brachial artery commonly terminates as the radial and common interosseous artery as seen in the present case. The SUA arises most frequently from the lower third of the brachial artery, less frequently from the upper third and rarely from the middle third.<sup>(3)</sup> In the present case, the SUA arose from the middle third of the brachial artery. The termination of the SUA by forming the superficial palmar arch without contribution from the radial artery is a rare finding.

Developmentally, the upper limb bud is initially supplied by a vascular plexus derived from four or five consecutive intersegmental branches of the dorsal aorta. Very early in development, the seventh cervical intersegmental branch enlarges and becomes consolidated as the main artery (axis artery) to the developing upper limb bud. This axis artery gives rise to the subclavian, axillary, brachial, and interosseous arteries and to the deep palmar arch. Other arteries of the upper limb develop as sprouts of

the axis artery.<sup>(13,14)</sup> The developmental reason for the superficial ulnar artery in the present case may be due to the ulnar artery establishing a connection with the axis artery in the arm and the bifurcation of the brachial artery into the radial artery and common interosseous artery may be due to the posterior interosseous artery arising from the axis artery just distal to the connection of the radial artery with the axis artery in the cubital fossa region and the continuation of the main trunk (axis artery) between the radial and posterior interosseous arteries being the common interosseous artery. The reason for the variant SPA may be due to the radial artery not linking up with the superficial palmar plexus in embryonic life.

The formation of an SPA by an SUA without any contribution from the radial or median arteries and the SPA providing origin to a common trunk for the princeps pollicis and radialis indicis arteries is a rare observation. In a comprehensive study of the arterial pattern of 750 hands, McCormack et al did not find an origin of the princeps pollicis and radialis indicis arteries from the SPA.<sup>(15)</sup> According to Ikeda et al. an artery arising from the SPA to supply the first web space can be called as the first common palmar digital artery.<sup>(16)</sup> So, in the current study it can be said that the SUA forming the SPA gave origin to four common palmar digital arteries. The first common palmar digital artery originating from the SUA artery is a rare anomaly.

The SPA is the center of attention for most surgical procedures and traumatic events in the hand. The hand surgeon needs to keep these variations in mind before performing surgical procedures such as arterial repairs, vascular graft applications, and free and/or pedicled flaps. During surgical procedures on the thumb in cases similar to ours, ligation of the radial artery may not be sufficient to stop profuse bleeding since the major blood supply comes from the superficial palmar arch.

### Conclusion

In summary, the presence of a superficial ulnar artery is a rare variation with immense clinical importance. Knowledge of this variation is important, not only for surgeons but also for other medical and nursing staff because they commonly perform intravascular cannulations. Knowledge of variations of the superficial palmar arch is also essential.

## REFERENCES

1. Hollinshead WH. Anatomy for Surgeons. Vol. 3. The Back and Limbs. 2nd ed. New York: Harper & Row, 1971:428-41.
2. Natsis K, Papadopoulou AL, Paraskevas G, Totlis T, Tsikaras P. High origin of a superficial ulnar artery arising from the axillary artery: anatomy, embryology, clinical significance and a review of the literature. *Folia Morphol (Warsz)* 2006;65:400-5.
3. Rodriguez-Niedenfuhr M, Vazquez T, Nearn L, Ferreira B, Parkin I, Sanudo JR. Variations of the arterial pattern in the upper limb revisited: morphological and statistical study, with a review of the literature. *J Anat* 2001;199: 547-66.
4. Jacquemin G, Lemaire V, Medot M, Fissette J. Bilateral case of superficial ulnar artery originating from axillary artery. *Surg Radiol Anat* 2001;23:139-43.
5. Nakatani T, Tanaka S, Mizukami S, Shiraishi Y, Nakamura T. The superficial ulnar artery originating from the axillary artery. *Ann Anat* 1996;178:277-9.
6. Dartnell J, Sekaran P, Ellis H. The superficial ulnar artery: incidence and caliber in 95 cadaveric specimens. *Clin Anat* 2007;20:929-32.
7. Ohana E, Sheiner E, Gurman GM. Accidental intra-arterial injection of propofol. *Eur J Anaesthesiol* 1999;16:569-70.
8. Goldberg I, Bahar A, Yosipovitch Z. Gangrene of upper extremity following intra-arterial injection of drugs. A case report and review of the literature. *Clin Orthop Relat Res* 1984;188:223-9.
9. Standring S. Gray's Anatomy. 39th ed.: City? Elsevier Churchill Livingstone Publishers, 2006:939.
10. Chin KJ, Sing K. The superficial ulnar artery - a potential hazard in patients with difficult venous access. *Br J Anaesth* 2005;94:692-3.
11. Latika A, Rima DR. Superficial ulnar artery. A case report. *Indian Journal for the Practicing Doctor* 2005;2:7-8.
12. Joseph J, Ranjit D, Jatin D. Superficial ulnar artery. *Eur J Cardiothorac Surg* 2005;28:495-6.
13. Allan FD. Arteries of the extremities. In: *Essentials of Human Embryology*. 2nd ed. London: Oxford, 1969:97.
14. Reddy S, Vollala VR. The superficial ulnar artery: development and clinical significance. *J Vasc Bras* 2007;6:285-8.
15. McCormack LJ, Cauldwell EW, Anson BJ. Brachial antibrachial arterial patterns. A study of 750 extremities. *Surg Gynecol Obstet* 1953;96:43-54.
16. Ikeda A, Ugawa A, Kazihara Y, Hamada N. Arterial patterns in the hand based on a three-dimensional analysis of 220 cadaver hands. *J Hand Surg* 1988;13:501-9.