

## Usefulness of the WuScope to Facilitate Double-lumen Endotracheal Tube Placement in A Patient with Ankylosing Spondylitis

Han-Dung Yu, MD; Angie CY Ho, MD; Yi-Cheng Wu<sup>1</sup>, MD; Ta-Sen Lin, MD

Functional separation of the lungs may be accomplished by several methods. Patients with a stiff neck and limited mouth opening restrict options to a one-lung ventilation. We report the use of the WuScope video system, a new tool for facilitating double-lumen endotracheal tube placement for one-lung ventilation, in a patient who suffered from ankylosing spondylitis with a stiff, flexed neck and limited mouth opening for his recurrent spontaneous pneumothorax. (*Chang Gung Med J* 2011;34:218-23)

**Key words:** double-lumen endotracheal tube, one-lung ventilation, ankylosing spondylitis, WuScope

Double-lumen endotracheal tube (DLT) has been used for one-lung ventilation for decades in thoracic surgeries. With the progress of science and technologies, video-assisted thoracoscopic surgery (VATS) has become the mainstream of current surgical interventions. In some circumstances, lung isolation is mandatory, but it may be difficult to achieve in limited mouth opening or critically ill patients. These anticipated difficult double-lumen endotracheal intubation complicated one-lung ventilation. We report the success of one-lung ventilation with DLT placement in a patient with a stiff, flexed neck and limited mouth opening by using the assistance of a rigid tubular fiberoptic laryngoscope (the WuScope Video System) in a Trendelenburg (head-down tilt) position.

### CASE REPORT

A 49-year-old male who had a medical history of previous pulmonary tuberculosis and ankylosing

spondylitis was admitted to undergo VATS for recurrent spontaneous pneumothorax. He had a history of progressive inability to move his spine for the last 5 years. On physical examination, he was unable to turn his head or tilt his chin because of his stiff cervical spine which was flexed toward his chest (Fig. 1A). The airway was assessed as Mallampati class IV (Fig. 1B). All preoperative laboratory values, chest radiographs and electrocardiograms were unremarkable. Isolated lung ventilation was requested by the surgeon. In the operation room, routine monitors were used. After evaluating the feasibility of face mask ventilation, the patient's neck was protected with a pillow under his occiput. Following pre-oxygenation, general anesthesia and relaxation were induced with fentanyl 150 µg, propofol 100 mg and rocuronium 50 mg intravenously. An artificial airway was prepared for assisting airway patency. We slowly adjusted the surgical table to a Trendelenburg position with a 30° downward tilt of the head in order to make the manipulation of mask ventilation

---

From the Department of Anesthesiology; <sup>1</sup>Department of Thoracic and Cardiovascular Surgery, Chang Gung Memorial Hospital at Linkou, Chang Gung University College of Medicine, Taoyuan, Taiwan.

Received: Jun. 19, 2009; Accepted: Sep. 30, 2009

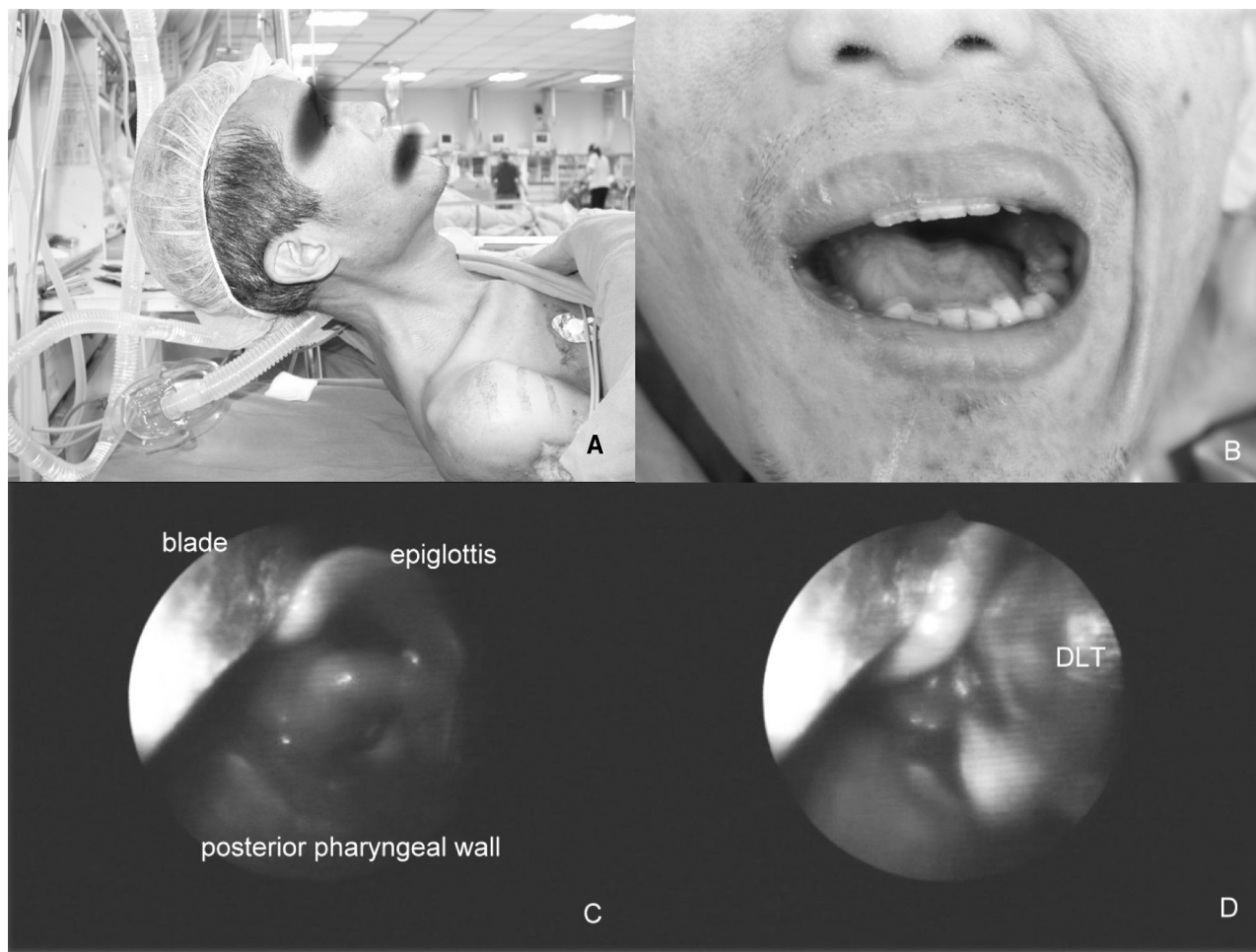Correspondence to: Dr. Ta-Sen Lin, Department of Anesthesiology, Chang Gung Memorial Hospital at Linkou, 5, Fusing St., Gueishan Township, Taoyuan County 333, Taiwan (R.O.C.) Tel.: 886-3-3281200 ext. 3624; Fax: 886-3-3281200 ext. 2787; E-mail: andersen46@cgmh.org.tw

easier for the patient. The rigid fiberoptic laryngeal WuScope with an indwelled DLT (Fig. 2A) was gently inserted into the patient's mouth under the direct vision of the video system. The WuScope blade tip was advanced gradually toward the vallecula. As the vocal cords came into sight, we moved the DLT forward into the trachea (Fig. 1C), but unfortunately, the tip of the tube was advanced toward the epiglottis instead of the entrance of the trachea. We withdrew the blade and rotated the DLT conversely inside the tubular blade (Fig. 2B) and finally endotracheal intubation succeeded after adjustment (Fig. 1D). After the cuff of the DLT passed through the vocal cords, we decomposed and withdrew the WuScope blade and turned the DLT leftward into the left main bronchus to facilitate one-lung ventilation. Lung sep-

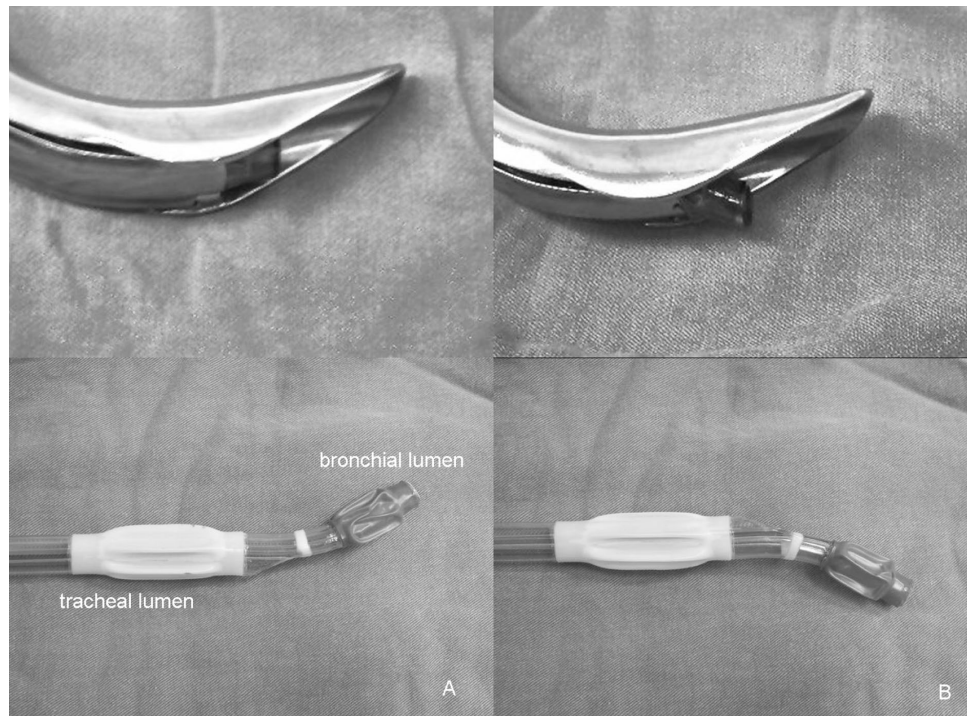
aration was accomplished without difficulty under a flexible fiberscope. Intubation was achieved without any episode of hypoxia, reflux regurgitation, or dental injury. A left VATS was performed. The airway pressure under one-lung ventilation was up to 31 cmH<sub>2</sub>O and no desaturation was noted through the whole procedure. The surgical intervention proceeded uneventfully with good visualization of the operation field. After completion of the surgery, the patient was extubated and he regained consciousness and spontaneous respiration.

## DISCUSSION

Selective ventilation of one-lung ventilation has been accomplished by several methods.<sup>(1,2)</sup> Tracheal



**Fig. 1** (A) The patient's rigid cervical spine was flexed toward his chest. (B) The range of his mouth opening was around two finger widths. (C, D) The entrance of the trachea as seen under the vision of fiberoptic laryngoscope.



**Fig. 2** (A) The bronchial curve corresponds with the blade curve. (B) The bronchial curve opposes the blade curve.

intubation of patients with a limited mouth opening may be difficult and challenging. The maximum mouth opening cannot be increased, even by administering neuromuscular blocking agents.<sup>(3)</sup> Fiberoptic intubation remains a recommended technique for airway management.<sup>(4)</sup> Nasal intubation might be advantageous for this purpose and easier to place, especially in patients with difficult airway.<sup>(4,5)</sup> This patient's restricted mouth opening limited options for one-lung ventilation. The larger outer diameter and distal curvature of the DLT would have made nasal intubation difficult, if not impossible.

We described a patient with cervical spine ankylosing with a stiff and flexed neck, and anticipated anatomical constriction of mouth opening, which disallowed passage of the DLT through the conventional method of endotracheal intubation. Compared with the single lumen endotracheal tube (ETT), the larger external diameter and the specific shape of the DLT (composed of a proximal oropharyngeal curve and a distal bronchial curve) made intubation with conventional laryngoscopy somewhat difficult. In addition to the DLT, there are substitutive devices for isolated lung ventilation of a patient with anatomic

factors predisposing to difficult intubation, such as the single-lumen endotracheal tube with an enclosed bronchial blocker (Univent) tube, Fogarty embolectomy catheter, or wire-guided endobronchial blocker (WEB, Arndt Blocker).<sup>(6)</sup> However, the major disadvantages of these devices including easy dislodgment of the blockers and disability of suctioning the secretion from the narrow blocker lumen make the DLT the first choice for one-lung ventilation nowadays in most clinical practices.

As stated by the *American Society of Anesthesiologists (ASA) Task Force*, the feasibility of ventilation should be assessed first while dealing with the difficult airway.<sup>(7)</sup> Although there were not enough evidences, we generally thought that the following factors might predict the difficulty of face mask ventilation while the patient was unconscious and paralyzed during anesthetic induction. A history of sleep disturbance because of impedance of breath in the supine position, morbid obesity with a short neck, remarkable facial anomalies, soufflé or stridor breathing sound, and an indwelled nasogastric or orogastric tube on physical examination could induce difficult mask ventilation. Since the risk factors men-

tioned above did not exist in our case, we decided to intubate the patient with a DLT while he was unconscious and paralyzed. Face mask ventilation was initially feasible following induction. However, his elevated upper trunk stretched the breathing Y-tube and made mask ventilation become more difficult. We therefore adjusted the surgical table to the Trendelenburg position to make it easier to hold the face mask. The risk of gastroesophageal regurgitation (GER) would be considered when a patient's airway is managed in such a position, and nevertheless, previous studies had demonstrated that there was little influence. Drugs commonly used during anesthesia can affect the lower esophageal sphincter, but, Roberts and Goodman did not observe any reflux episodes in patients anesthetized with propofol and fentanyl in their clinical study.<sup>(8)</sup> Any decrease in esophageal barrier pressure (BrP) during anesthesia would be expected to increase the risk of regurgitation, but Heijke et al, found that a 30° Trendelenburg position did not affect the BrP.<sup>(9)</sup> In a recent clinical study, Hans-Christian et al, also showed that specific positioning did not significantly influence the frequency of GER in awake patients even with a "full stomach".<sup>(10)</sup>

The WuScope video system (Fig. 3 and 4) is nowadays an alternative, new tool to overcome many of the pitfalls of current difficult airway. It is a combination fiberoptic laryngoscope system, and is designed to facilitate placement of the endotracheal tube with the patient's head and neck in the neutral position.<sup>(11)</sup> Although conventional rigid laryn-

goscopy demands a straight alignment of the upper anatomy, if this cannot be achieved, difficult intubation can be overcome by using the WuScope due to the curved blade and the optical guide of the fiberoptic. The WuScope system requires a minimum mouth opening of only 20-25 mm, and tongue displacement, head extension or neck movement is not necessary during intubation. This design, compared with a fiberoptic alone, reduces the impediments of soft tissue obstruction and offers continuous visualization when tubes pass through the vocal cords.<sup>(11)</sup> The WuScope has been used for difficult placement of DLTs (grade III~IV view under conventional laryngoscopy) in clinical practices.<sup>(12)</sup> Charles et al, demonstrated that although success rates or number of intubation attempts were not significantly different, tracheal intubation in patients with cervical immobilization by using the WuScope was associated with lower difficulty and better visualization of the laryngeal aperture than by using conventional laryngoscopy.<sup>(13)</sup> Although the WuScope effectively offers good visualization of a patient's larynx toward the epiglottis to the operator, specific maneuvers to accomplish the placement of the ETT in certain situations are necessary. In our clinical practices, it leads to successful intubation with fewer attempts by switching the tube conversely inside the tubular blade, inserting a catheter (suction catheter or ETT exchanging catheter) in the ETT as a guide, or lifting the epiglottis with the tip of tubular blade directly to expose the entrance of the trachea.

Intubation for one-lung ventilation is quite a dif-

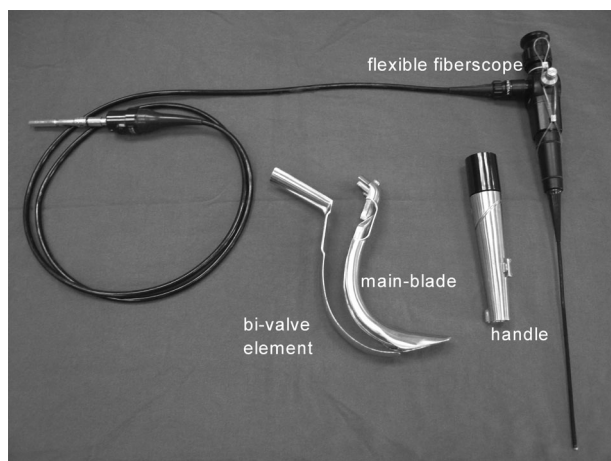


Fig. 3 The components of the WuScope.

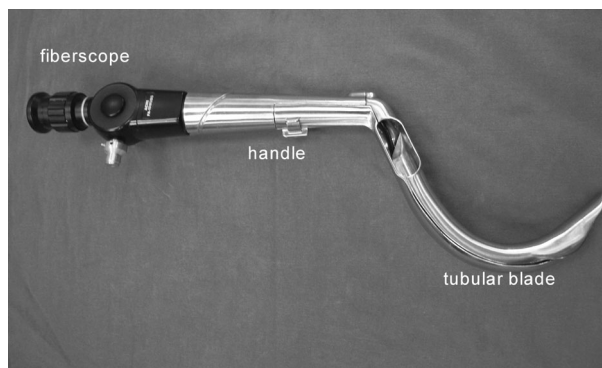


Fig. 4 The WuScope. The main-blade and the bi-valve element are positioned together to form a tubular, curved, bi-valved, rigid blade with two passageways for an endotracheal tube and fiberoptic respectively.

ferent territory in airway management. The WuScope video system offers a new tool to facilitate endobronchial DLT placement into a patient's trachea to achieve one-lung ventilation in adults. The "practice guidelines for management of the difficult airway" reported by the *ASA Task Force* may constitute an algorithm for approaching a patient with difficulties in performing one-lung ventilation.

## REFERENCES

1. Benumof JL, Partridge BL, Salvatierra C, Keating J. Margin of safety in positioning modern double-lumen endotracheal tubes. *Anesthesiology* 1987;67:729-38.
2. MacGillivray RG. Evaluation of a new tracheal tube with a movable bronchus blocker. *Anaesthesia* 1988;43:687-9.
3. Aiello G, Metcalf I. Anaesthetic implications of temporomandibular joint disease. *Can J Anaesth* 1992;39:610-6.
4. Benumof JL. Management of the difficult adult airway. With special emphasis on awake tracheal intubation. *Anesthesiology* 1991;75:1087-110.
5. Gozal Y, Lee W. Nasal intubation and one-lung ventilation. *Anesthesiology* 1996;84:477.
6. Campos JH, Hallam EA, Van Natta T, Kernstine KH. Devices for lung isolation used by anesthesiologists with limited thoracic experience: comparison of double-lumen endotracheal tube, Univent torque control blocker, and Arndt wire-guided endobronchial blocker. *Anesthesiology* 2006;104:261-6.
7. American Society of Anesthesiologists Task Force on Management of the Difficult Airway. Practice guidelines for management of the difficult airway: an updated report by the American Society of Anesthesiologists Task Force on Management of the Difficult Airway. *Anesthesiology* 2003;98:1269-77.
8. Roberts CJ, Goodman NW. Gastroesophageal reflux during elective laparoscopy. *Anaesthesia* 1990;45:1009-11.
9. Heijke SAM, Smith G, Key A. The Effect of the Trendelenburg position on lower oesophageal sphincter tone. *Anaesthesia* 1991;46:185-7.
10. Jeske HC, Borovicka J, von Goedecke A, Meyenberger C, Heidegger T, Benzer A. The influence of postural changes on gastroesophageal reflux and barrier pressure in non-fasting individuals. *Anesth Analg* 2005;101:597-600.
11. Wu TL, Chou HC. A new laryngoscope - the combination intubating device. *Anesthesiology* 1994;81:1085-7.
12. Smith CE, Kareti M. Fiberoptic laryngoscopy (WuScope) for double-lumen endobronchial tube placement in two difficult-intubation patients. *Anesthesiology* 2000;93:906-7.
13. Smith CE, Pinchak AB, Sidhu TS, Radesic BP, Pinchak AC, Hagen JF. Evaluation of tracheal intubation difficulty in patients with cervical spine immobilization - Fiberoptic (WuScope) versus conventional laryngoscopy. *Anesthesiology* 1999;91:1253-9.

## 使用 WuScope 於僵直性脊椎炎病患放置雙管徑氣管內管

余漢東 何綺月 吳怡成<sup>1</sup> 林大森

進行胸腔手術時，經常需要單肺麻醉技術，當今麻醉科醫師常使用雙管徑氣管內管 (double-lumen endotracheal tube) 來進行單肺麻醉，但是在處理屬於困難呼吸道的病患時，雙管徑氣管內管的置放常難以成功。我們報告一例患有僵直性脊椎炎的病患，因復發性氣胸，而須使用單肺麻醉來進行影像輔助式胸腔鏡手術 (video-assisted thoracoscopic surgery) 治療，但因僵直性脊椎炎的影響，病患的頸部僵硬屈曲，張口困難，屬於困難呼吸道。在麻醉誘導的過程中，因為頸部彎曲造成面罩通氣困難，於是我們將病患調整至頭低腳高的姿勢 (Trendelenburg position)，使面罩通氣能順利進行。而因張口困難限制直達式喉頭鏡插管，我們使用 WuScope 系統來協助雙管徑氣管內管的放置，在第二次嘗試時，我們將雙管徑氣管內管支氣管分支的弧度調整至與 WuScope blade 之弧度相反後，成功完成雙管徑氣管內管放置。在這篇報告中，我們討論於頭低腳高姿勢進行面罩通氣的可行性以及 WuScope 系統的應用。(長庚醫誌 2011;34:218-23)

**關鍵詞：**雙管徑氣管內管，單肺麻醉，僵直性脊椎炎，WuScope

---

長庚醫療財團法人林口長庚紀念醫院 麻醉部，<sup>1</sup>心臟血管胸腔外科；長庚大學 醫學院

受文日期：民國98年6月19日；接受刊載：民國98年9月30日

通訊作者：林大森醫師，長庚醫療財團法人林口長庚紀念醫院 麻醉部。桃園縣333龜山鄉復興街5號。

Tel.: (03)3281200轉3624; Fax: (03)3281200轉2787; E-mail: andersen46@cgmh.org.tw