Skin Grafting as A Salvage Procedure in Diabetic Foot Reconstruction to Avoid Major Limb Amputation

Jiun-Ting Yeh, MD; Chih-Hung Lin, MD, FACS; Yu-Te Lin, MD

Background: Bone and tendons exposure in diabetic patients requires flap reconstruction to avoid major limb amputation. However, for critical and unstable diabetic patients, revascularization and flap reconstruction may not be feasible. Skin grafts can be used in such a situation, and the purpose of this study is to evaluate this procedure in terms of treatment outcome.

Methods: From October 2003 to October 2006, there were 73 critical diabetic cases with bone and tendon exposure at the lower extremities. Repeated debridements were performed to remove the exposed tendon and burr the bare bone until bleeding. Some cases needed adjuvant therapy to promote granulation for skin grafting.

Results: Before skin grafting, thirty cases need toe amputation. The mean presurgical preparation period for a suitable granulation bed was 38.4 days. After skin grafting, wound healing was achieved within 4 weeks in 54 cases, and it took over 4 weeks in 9 cases. In 2 cases, a second skin graft was required. Forefoot stump revision was performed in 3 cases. Total wound healing could not be achieved within 3 months in 5 cases. The complete wound healing rate was 74% in 1 month and 86.3% in 2 months.

Conclusion: In order to preserve the feet, the skin grafting rather than major amputation is suitable for critical and unstable diabetic patients. The drawback is the relatively prolonged treatment course.

(Chang Gung Med J 2010;33:389-96)

Key words: skin graft, diabetes mellitus, foot reconstruction, critical patients

In Chinese society, preserving the foot is a major hope of diabetic patients and their families. However, lower extremity reconstruction is complicated due to the underlying diseases and poor wound healing. For foot reconstruction in unstable or critical diabetic patients, complex reconstruction procedures are not suitable and a simple and less invasive surgical intervention that is associated with low anesthesia risk is the treatment of choice. Flap reconstruction can provide better protection and good cosmetics results. For a free flap, the local tissues require good recipient vessels for flap revascularization. In diabetic patients, who have poor peripheral circulation, this will present as poor wound healing and this may progress to a larger wound. In this circumstance, the flap intervention becomes risky and unreliable. An easy and fast reconstructive technique such as skin grafting should be considered as another

From the Division of Trauma, Department of Plastic and Reconstructive Surgery, Chang Gung Memorial Hospital at Linkou, Chang Gung University College of Medicine, Taoyuan, Taiwan.
Received: May 4, 2009; Accepted: Aug. 26, 2009
Correspondence to: Dr. Jiun-Ting Yeh, Department of Plastic and Reconstructive Surgery, Chang Gung Memorial Hospital at Linkou. 5, Fusing St., Gueishan Township, Taoyuan County 333, Taiwan (R.O.C.) Tel.: 886-3-3281200 ext. 3652;
Fax: 886-3-3285878; E-mail: a12271@cgmh.org.tw

possibility. However, not all soft tissue defects can be treated with simple skin grafts. The recipient bed requires adequate wound preparation to promote more granulation, and there should be no exposed bones, tendons, or other naked vessels. After adequate debridement, the bones, tendon, and vessels are always exposed. If aggressive surgical intervention is unsuccessful in covering the tissue defects, the soft tissues will become dry and unviable. To avoid major limb amputation, the bared necrotic tendons must be excised and the exposed bones burred to bleed. Viable paratendon, periosteum, and granulation tissues are preserved as much as possible. Skin grafting is performed after granulation budding in the wound bed. To achieve this, the debridement is performed aggressively and repeatedly till the wound is clean.[1,2] Hyperbaric oxygen and vacuum assisted closure (VAC) can be used to promote wound healing. In cases where ischemia is noted, this must be treated with revascularization or angioplasty before further reconstruction.

METHODS

We present 73 cases of diabetic patients with lower extremity soft tissue defects after aggressive wound debridement. These patients were treated from October 2003 to October 2006. Forty-seven male and 26 female patients were included in this series; the mean age of the patients was 57.3 years (range, 33-86 years). The wounds were initially classified as grade 2 (28 cases), grade 3 (31 cases) and grade 4 (14 cases), according to the Wagner classification of diabetic foot ulcers (Table 1).[3] These patients had poorly controlled diabetes, and their mean glycosylated hemoglobin (HbAic) level was 9.9%. It was observed that they had poor nutrition with a mean serum albumin level of 2.92 g/dL. Arterial Duplex scans were performed and the ankle-brachial index should be above 0.8. They were diagnosed as having foot ulceration with severe infection and poor sugar control. These patients required immediate debridement and infection control. Debridement was performed as soon as possible to remove the necrotic tissues. In order to preserve soft tissue for skin grafting, many tricks were performed during the debridement. One was the use of scissors to remove the necrotic tissue rather than a curette, which destroys more healthy underlying tissue. In addition, the exposed viable tendons and bones were covered with surrounding soft tissues. If there was no soft tissue, we used wet dressings to keep the moisture in or a closed dressing system to avoid drying of the tissues. The key point with respect to subsequent wound debridement was a dependency on granulation formation and the exposure of tendons or bones. Many surgical techniques were carried out to promote granulation. The key points were to remove bare tendons and exposed bones. Some healthy bone was preserved and the outer cortex was ground until bleeding.

Table 1. Wagner's Classification for Diabetic Foot Disease (Adapted from Levin and O'Neals)[3]

Grade -0	High risk foot and no ulceration
Grade -1	Superficial ulcer
Grade -2	Deep ulcer (cellulitis)
Grade -3	Osteomylitis with ulceration or abscess
Grade -4	Gangrenous patches, Partial foot gangrene
Grade -5	Gangrene of entire foot

For grafting preparation, the waiting period was long. The skin grafting was not performed until the tissues were covered with granulation. At the same time the patient's sugar level, nutrition and infection had to be under control. Tourniquets were not applied routinely except when there was mass bleeding. The surgical interventions were performed while the patients were in the supine position and under spinal anesthesia. A meshed skin sheet was harvested from the thigh and fixed with absorbable chromatic stitches. The meshed skin graft was protected with one layer of nylon mesh sheet. Above the nylon sheet, wet cotton was used to cover the graft and it was compressed with elastic bandage. Thereafter, the patients' feet were immobilized using a short leg splint.

RESULT

The mean pre-grafting period for the formation

of the granulation bed was 38.4 days. During this period, the diet of the patients was monitored and followed-up by a dietician. The patient's blood sugar was monitored regularly and was controlled to below 200 mg/dL. Twelve patients received VAC therapy and 6 received hyperbaric oxygen therapy to promote wound healing. Prior to skin grafting, there were 30 cases whose toes were amputated [1 toe (13 cases), 2 toes (7 cases), 3 toes (3 cases), 4 toes (2 cases), 5 toes and forefoot amputation (5 cases)]. The mean skin graft area was 65.85 cm^2. In this series, toe amputation or partial forefoot amputation was required prior to skin grafting in 41.1% of patients. After skin grafting, wound healing was achieved within 2 weeks in 45 cases, between 2-4 weeks in 9 cases, and over 4 weeks in 9 cases. In 10 cases, no sign of healing was observed after the first skin graft. A second skin graft was performed in 2 cases 2 months later. The wound healing could not be achieved within 3 months in 5 cases. The forefoot stump revision was required in 3 cases.

After skin grafting, the patients were discharged 2 weeks later. The mean total hospitalization time was 53 days. The wound healing rate was 74% in 1 month and 86.3% in 2 months (Table 2).

Case Reports

Case 1:

This patient was a 35-year-old male. He was unaware of his diabetic condition until he contracted a left foot infection. The infection fulminated into a near total dorsal foot necrosis. The forefoot and toes underwent progressive wet gangrene due to pus infiltration. Finally the toes were amputated one by one. After three aggressive sessions of debridement and amputation of 5 toes, bone exposure and large skin defects could be observed. Since the patient wished to walk, we attempted to preserve the ankle joint and heel pad for ambulation. Initially, we attempted to use a free flap to cover the bare bone; however, the recipient blood vessels demonstrated severe arthrosclerosis and poor blood flow. We excised exposed bones and unviable tendons in a series of surgical procedures. Wound care was provided for 35 days in order to promote granulation. The patient received a skin graft and was discharged 1 week later. He was followed-up regularly at our clinic, and he could walk using a special prosthesis by himself about 3 months later (Fig. 1).

Case 2:

A 54 year-old female patient suffered from injury to the forefoot caused by a nail; the infection spread to the lower leg and developed into foot-necrotizing fasciitis. The second and third toes were amputated at the metatarsal bone level. The tendon and bone stump were exposed under aggressive debridement. After three sessions of debridement, we

Table 2. Summary of Results

Initial wound classification (Wagner)	Toe amputation cases	Skin grafting	
		Healing	Non healing
Grade: 0	30 cases:	Total cases: 63	10 cases:
Grade 2: 28	1 toe: 13	< 2 weeks: 45 cases	Secondary grafting:
Grade 3: 31	2 toes: 7	2~4 weeks: 9 cases	2 at 2 months
Grade 4: 14	3 toes: 3	> 4 weeks: 9 cases	Stump revision: 3
Grade 5: 0	4 toes: 2		Healing needing
	5 toes or forefoot		> 3 months: 5
	amputation: 5		
	30 cases of toe amputation		
	30/73 = 41.1%		
	Wound healing rate: 74% (1 month), 86.3% (2 months)		
	Mean pre-skin grafting days: 38.4 days		
	Mean hospitalization days: 53 days		

73 cases. Mean size of skin graft 65.85 cm^2

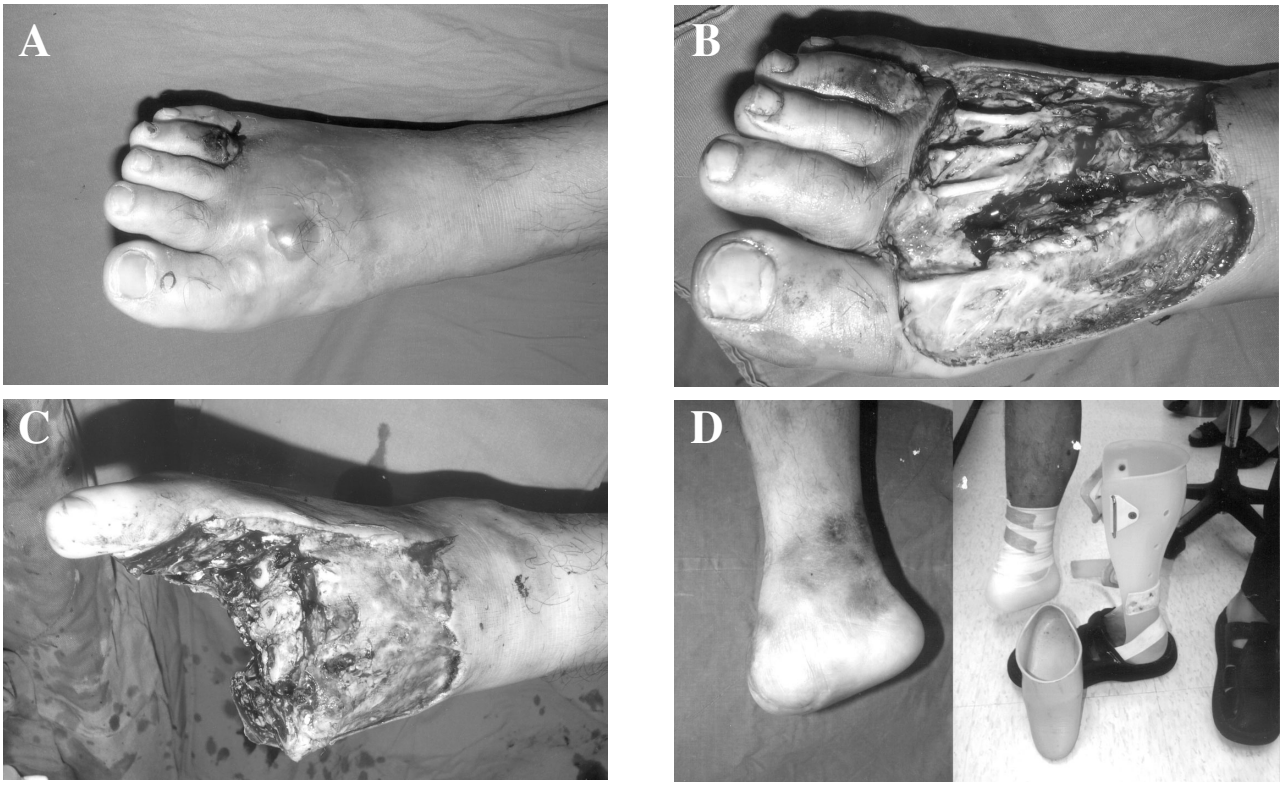

Fig. 1 (A) This 33-year-old male patient was suffering from a right foot infection with bullae formation. (B) After the first debridement, the extensor was exposed; the toes were in poor condition and ischemia developed due to progressive forefoot necrosis. (C) After repeated debridement, the toes were amputated. (D) We covered the wound with a skin graft rather than performing flap reconstruction due to poor vascular condition. Three months later he could use a partial foot prothesis for ambulation.

used the VAC technique to promote wound healing and decrease the wound size. Approximately 40 days after admission, the wound was covered with a skin graft, and the patient was discharged within 10 days. She was able to walk to work and could perform her daily activities comfortably (Fig. 2).

DISCUSSION

The loss of protective sensation in diabetic neuropathy is instrumental in skin breakdown, and it eventually develops into ulcers and infection. In addition, the patient's hyperglycemia is associated with poor clinical outcomes in surgical and critically ill patients.[4] Due to their unstable blood sugar, management of their sugar level together with wound care and infection control at the same time are required.[5,6] Many recent studies have demonstrated that strict glucose control can decrease morbidity and mortality associated with critical illness.[7-13]

To avoid major limb amputations and prevent further complications, foot ulcers with infections should be detected at an early stage. Wounds with infection alter the normal healing process by disrupting the healing and prolonging the inflammatory phase.[14] The first step toward achieving wound healing is debridement. Aggressive and repeated debridement is encouraged for contaminated or soiled wounds. Debridement of chronic wounds transforms the wounds to acute wounds, which is a prerequisite for wounds to progress through the normal phases of wound healing. When wounds are cleaned and rich in granulation tissue, they will progress towards epithelium growth. At this time skin grafts can promote wound healing and reduce the time needed for wound healing.[15]

In foot reconstructive ladders, soft tissue defects with bone or tendon exposure will require flap recon-

struction (Table 3). The local flap is the first choice when treating small wound defects; however, larger wound defects require larger flaps. Therefore free flaps are indicated for coverage. However, free flap reconstruction may not be suitable when a critical patient has many chronic diseases such as hypertension, renal disease, and diabetes mellitus. These diseases result in a weak or unstable patient with higher anesthesia risk and prolonged surgical time; this will worsen the surgical results. Flap revascularization is not possible in patients demonstrating poor peripheral vascularization since there will be a lack of good recipient vessels. Free flap transfer becomes high risk and contraindicated in these patients. For ambu-

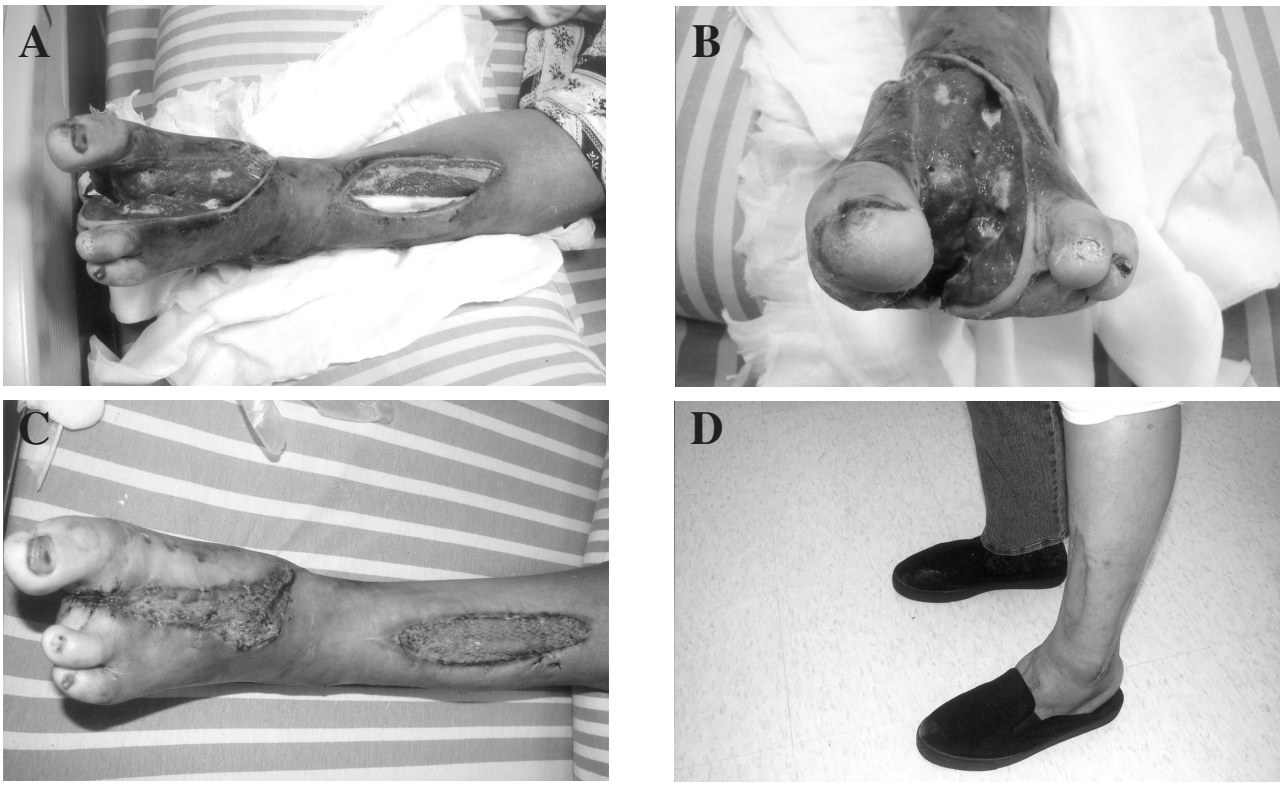

Fig. 2 (A, B) This 54-year-old female patient suffered from an injury caused by a nail; the infection spread to the foot and lower leg and developed was necrotizing fasciitis. After repeated debridement, the toes were amputated and some tendons remained exposed. (C) The wound was covered with a skin graft and there was good take at post-operative day 10. (D) The patient's foot was preserved and she is able to walk comfortably.

Table 3. Comparison of Flap and Skin Grafting

	Timing	Limitation	Preparation time	Preparation course	Benefits	Drawbacks
Skin grafting	Wound defect with granulation	Bone and tendon exposure	Long	Short	Fast skin resurfacing	Ugly, stiffness, adhesions
Flap	Wound defect with bone and tendon exposure	Poor circulation	Short	Long	Better cosmetic appearance and function	Bulky appearance, secondary revision

lation, preservation of the foot is the best hope. Therefore, surgical intervention must be revised to avoid below-knee or above-knee amputations. It is important to remove the exposed tendons and burr exposed bones to facilitate wound closure, while not preserving the paratendon and periosteum. The raw surface is prepared for skin grafting. Aggressive debridement is performed repeatedly until the wound is clean and this stage takes a long time. When the wound bed is rich in granulation, skin grafting can be performed.

Skin grafting is a basic method of the reconstruction, but we have refined the procedure. Skin sheets can be harvested from the scalp, sole, thigh, and back. We favor skin sheets from the thighs. For surgery of the lower extremities in diabetic patients, we prefer spinal anesthesia to general anesthesia. Under spinal anesthesia, the patient's condition can be monitored and the risks of general anesthesia can be reduced. In addition, the thigh region can provide a larger amount of skin grafts. The lack of delayed healing at the donor site encourages the diabetic patients to accept the skin grafting. However the drawback includes scarring and a poor cosmetic outcome on the thigh. To avoid donor site morbidity, the key point is that the harvested skin should not be thicker than 0.01 inches. The donor sites are covered with the absorbable dressing pad and heal within 2 weeks. The skin sheets are meshed (1:2). Meshed skin is beneficial to the drainage of exudates and it is easy to detect sub-graft hematomas. The skin graft is protected with a nylon mesh sheet and fixed with chromatic sutures. The chromatic stitches and the nylon sheet are removed on post-operative day 5 to 7.

Wound bed preparation is a long process, especially in diabetic patients with vascular insufficiency or poor sugar control. The first procedure involves removing the dead tissue and creating a moist environment for granulation formation. This study does not focus on the ambulation success and the cosmetic results for these critical patients, but rather targets rapid wound healing. Adjuvant therapies include hyperbaric oxygen therapy and negative pressure wound therapy, which promote wound healing and avoid major limb amputation. Thereafter, the patients can ambulate with the help of a walker or wheel chair. After discharge, care is provided at home or they are transferred to a nursing care center for rehabilitation.

The mean total hospitalization time is 53 days. This is longer than that of an ordinary diabetic patient (around 30 days in our hospital). Thus this approach requires more hospital care resources. In this context, it would be beneficial if we could improve the care method in order to reduce the hospitalization days. To this end, possibilities include aggressive debridement by a sharp instrument such as a VERSAJET (Smith & Nephew), promoting wound healing by the use of growth factors, hyperbaric oxygen, and VAC, as well as a well organized team. We have tried most of these approaches in practice, but we may need more courage and a more aggressive attitude when promoting this wound care system. Another big difference between our system and other international medical centers is that they provide outpatient care in the preparation period. However the home care concept is not well accepted by our population and they are generally admitted until wound healing or a dramatic improvement. This is a major obstacle when trying to reduce hospitalization days.

Conclusion

Foot preservation is the ultimate objective of foot reconstruction. However, flap reconstructions in critical diabetic patients with a severe foot infection or necrosis is an impossible task. Therefore, aggressive debridement should be performed and adjuvant therapy used to promote healing. The duration of wound preparation depends on the patient's condition and the surgical intervention. We attempted to preserve the patients' feet and self-image, although the feet may have poor functionality and are perhaps in some cases useless. However, the patients believe that it is worthwhile to preserve their feet.

REFERENCES

1. Attinger CE, Bulan E, Blume PA. Surgical debridement. The key to successful wound healing and reconstruction. Clin Podiatr Med Surg 2000;17:599-630.
2. Attinger CE, Bulan EJ. Debridement. The key initial first step in wound healing. Foot Ankle Clin 2001;6:627-60.
3. Brodsky JW. Classification of foot lesions in diabetic patients. In: Levin, O'Neal, eds. The Diabetic Foot. 7th edition. Philadelphia: Mosby, 2008:221-6.
4. Smiley DD, Umpierrez GE. Perioperative glucose control

in the diabetic or nondiabetic patient. South Med J 2006;99:580-9; quiz 90-1.
5. Peleg AY, Weerarathna T, McCarthy JS, Davis TM. Common infections in diabetes: pathogenesis, management and relationship to glycaemic control. Diabetes Metab Res Rev 2007;23:3-13.
6. Gearhart MM, Parbhoo SK. Hyperglycemia in the critically ill patient. AACN Clin Issues 2006;17:50-5.
7. Khoury W, Klausner JM, Ben-Abraham R, Szold O. Glucose control by insulin for critically ill surgical patients. J Trauma 2004;57:1132-8.
8. Nitiyanant W, Chetthakul T, Sang AkP, Therakiatkumjorn C, Kunsuikmengrai K, Yeo JP. A survey study on diabetes management and complication status in primary care setting in Thailand. J Med Assoc Thai 2007;90:65-71.
9. Malmstedt J, Wahlberg E, Jorneskog G, Swedenborg J. Influence of perioperative blood glucose levels on outcome after infrainguinal bypass surgery in patients with diabetes. Br J Surg 2006;93:1360-7.
10. Icks A, Rathmann W, Haastert B, Mielck A, Holle R, Lowel H, Giani G. Quality of care and extent of complications in a population-based sample of patients with type 2 diabetes mellitus. The KORA survey 2000. Dtsch Med Wochenschr 2006;131:73-8.
11. Meisinger C, Beck J, Heier M, Hormann A, Kuch B, Sietas G, Koenig W. Myocardial infarction and incidence of type 2 diabetes mellitus. Is admission blood glucose an independent predictor for future type 2 diabetes mellitus? Am Heart J 2010;159:258-63.
12. Schellhase KG, Koepsell TD, Weiss NS. Glycemic control and the risk of multiple microvascular diabetic complications. Fam Med 2005;37:125-30.
13. Yu CC, Wu MS, Wu CH, Yang CW, Huang JY, Hong JJ, Fan Chiang CY, Leu L, Huang CC. Predialysis glycemic control is an independent predictor of clinical outcome in type II diabetics on continuous ambulatory peritoneal dialysis. Perit Dial Int 1997;17:262-8.
14. Bochicchio GV, Sung J, Bochicchio K, Johnson SB, Meyer W, Scalea TM. Persistent hyperglycemia is predictive of outcome in critically ill trauma patients. J Trauma 2005;58:921-4.
15. Robson MC, Stenberg BD, Heggers JP. Wound healing alterations caused by infection. Clin Plast Surg 1990;17:485-92.
16. Zimny S, Schatz H, Pfohl M. Determinants and estimation of healing times in diabetic foot ulcers. J Diabetes Complicat 2002;16:327-32.

自體皮膚移植來挽救糖尿病足以避免大肢體的截肢手術

葉俊廷 林志鴻 林有德

背 景： 糖尿病患需要皮瓣重建，保護經清創手術後裸露出來的骨頭及肌腱，以避免膝下肢體的截肢。然而大部分的糖尿病人，特別是那些危急且不穩定的病患，是不適合接受長時間的手術，血管重建及皮瓣手術常常是不可行的。自體皮膚移植是用來重建皮膚缺損時的基本重建方式，然而卻不是適用於所有病人。

方 法： 從西元 2003 年 10 月至 2006 年 10 月，我們收集 73 例嚴重的糖尿病患有下肢骨骼及肌腱裸露。嘗試保留足部的方法是經由多次清創手術來清除裸露的肌腱及磨掉沒有骨膜的裸骨，同時促進肉芽床生長後進行植皮手術，以促使傷口早日癒合。

結 果： 進行植皮手術前的準備工作，平均的住院時間爲 38.4 天。其中有 30 位病患需要腳趾截肢。植皮術後，54 例在四週內可以達到傷口癒合，9 例超過 4 週。共有 10 例無法因爲首次植皮而痊癒。其中有 2 例需要再度植皮，有 3 例需要進行足部前端的修整手術，有 5 例在 3 個月內仍然無法癒合。整個傷口癒合率在術後第一個月爲 74%，在第二個月可以提升到 86.3%。

結 論： 對於危急的病患爲保留足以便行走，利用植皮手術以取代截肢手術是可行的方法。其缺點爲達到適合植皮的準備時間與住院期間都比一般糖尿病人住院期爲長。
(長庚醫誌 2010;33:389-96)

關鍵詞： 皮膚移植，糖尿病，足部重建，危急病人

長庚醫療財團法人林口長庚紀念醫院 重建整形外科系；長庚大學 醫學院
受文日期：民國98年5月4日；接受刊載：民國98年8月26日
通訊作者：葉俊廷醫師，長庚醫療財團法人林口長庚紀念醫院 重建整形外科系。桃園縣333龜山鄉復興街5號。
Tel.: (03)3281200轉3652; Fax: (03)3285878; E-mail: a12271@cgmh.org.tw