The Application of Miniprobe Ultrasonography in the Diagnosis of Colorectal Subepithelial Lesions

Tsung-Hsing Chen, MD; Chun-Jung Lin, MD; Ren-Chin Wu[1], MD; Yu-Pin Ho, MD; Chen-Ming Hsu, MD; Wei-Pin Lin, MD; Yu-Pin Tseng, MD; Cheng-Hsiung Chen, MD; Cheng-Tang Chiu, MD

Background: Difficulty with the proximal lesion approach and durability of endoscopic ultrasonography (EUS) instruments usually limits its application for lower gaotrointestina (GI) lesions to locoregional staging of rectal cancer. This study investigated the value of colonoscopic miniprobe ultrasonography for differential diagnosis and treatment strategy in patients with colorectal subepithelial lesions (SEL).

Methods: Miniprobe ultrasonography was Performed in 40 consecutive patients with suspected colorectal SEL or residual lesions after endoscopic resection at one medical center by the same endoscopist (C-J Lin). The EUS images and procedure records were reviewed. The final diagnosis of these lesions was confirmed by crosssection imaging, histopathologic findings, or clinical follow-up.

Results: Miniprobe EUS allowed high-resolution imaging and a successful approach to all colorectal SEL through the working channel of a sigmoidoscope or colonoscope without breakdown of the miniprobe. Thirteen patients, suspected of having rectal carcinoid tumors (mean size, 6.9 ± 3.3 mm), were treated radically by endoscopic mucosal resection using a transparent cap (EMRC) after EUS confirmation of no muscular invasion. Three patients had no residual or recurrent carcinoid tumor on EUS examination after previous empiric polypectomy or biopsy. EUS detected submucosal lipomas (mean size, 18.5 mm; range, 8.6-25.6 mm) in ten patients however, only two patients underwent endoscopic resection. Five patients had suspected rectal myogenic stromal tumors on EUS; three were transferred for surgical resection due to uterine myoma compression (N = 2) or mucinous adenocarcinoma of the appendix with rectal metastasis (N = 1), and two had uterine myoma detected by gynecologic ultrasound or CT. One appendiceal stone with orifice obstruction mimicking cecal submucosal tumor was proved by surgical resection.One patient had hemorrhoids proved by hemorrhoidectomy. One patient was proved to have proctitis cystica profunda by EMRC. The other six patients had various benign lesions, which were diagnosed and followed-up by EUS without progression. In thirty-five of forty patients (88%) colorectal SEL were managed uneventfully according to EUS interpretation.

Conclusions: Miniprobe ultrasonography can be a useful supplement to routine colonoscopy and provide treatment guidance for suspected colorectal subepithelial lesions.

(Chang Gung Med J 2010;33:380-8)

Key words: subepithelial lesion, miniprobe ultrasonography, endoscopic mucosal resection

Department of Gastroenterolgy and Hepatology; [1]Department of Pathology, Chang Gung Memorial Hospital at Taipei, Chang Gung University College of Medicine, Taoyuan, Taiwan.
Received: Mar. 4, 2009; Accepted: Aug. 13, 2009
Correspondence to: Dr. Chun-Jung Lin, Department of Gastroenterology and Hepatology, Chang Gung Memorial Hospital at Linkou. 5, Fusing St., Gueishan Township, Taoyuan County 333, Taiwan (R.O.C.) Tel.: 886-3-3281200 ext. 8107;
Fax: 886-3-3272236; E-mail: ma1249@cgmh.org.tw

Endoscopic ultrasonography (EUS) has been widely used for preoperative cancer staging of the gastrointestinal tract.[1-5] However, this technique is not widely used for other colorectal neoplasms or subepithelial lesions (SEL) because of the limitations of conventional colonoscopic endosonography including instrument rigidity and inflexible large tip diameters.[6,7] Furthermore, it is hard to examine stenotic tumors and reach tumors proximal to rectosigmoidoscopy.[1] The recent introduction of high-frequency miniprobe ultrasonography (HFUS) has overcome most of these problems. The probe can be passed through the working channel of a colonoscope and high resolution images can be obtained during the same examination session. Miniprobe EUS can also provide satisfactory accuracy in the differentiation and staging of colorectal neoplasms.[1,8]

Colorectal SEL are unusual and are occasionally found by colonoscopy performed because of lower gaotrointestina (GI) symptoms or cancer screening. Therefore, further treatment strategies may include evaluation by other cross-sectional imaging modalities, surgical or endoscopic resection, or surveillance and clinical follow-up.[8,9] However, experience and reports are limited on the application of miniprobe EUS for diagnosis, as well as for an adjuvant role, in the treatment of patients with colorectal SEL.[8,10] This study was designed to investigate the value and effectiveness of colonoscopic miniprobe EUS on differential diagnosis and treatment strategy for patients with colorectal SEL.

METHODS

From January 2001 to January 2009, miniprobe ultrasonography (Olympus UM-2R/3R 12/20 MHz, Tokyo, Japan) was performed by the same endoscopist (C-J Lin) on forty consecutive patients (twenty-four males, sixteen females; mean age, 49.4 ± 12 years) who had either suspected SEL of the colorectum or were evaluated for residual lesions after endoscopic resection at Chang Gung Memorial Hospital, Taipei. Most patients presented with abdominal pain (n = 13, 33%) or only for a medical checkup (n = 18, 45%), the others are as follow: bleeding (n = 3, 7.5%), obstruction (n = 1, 2.5%), nonspecific (n = 5, 12%). Most subepithelial lesions were located in the rectosigmoid colon (n = 28, 70%).

Endoscopic ultrasonography technique

Colon preparation was the same as for conventional colonoscopy with 2 liters polyethylene glycol (PEG)-electrolyte solution (klean-prep powder) or 90 ml Sodium phosphates soln (Fleet Phospho-Soda) taken before the procedure and the patient was put under mild sedation by administering midazolam (Dormicum) 1-3 mg intravenously and by giving hyoscine butylbromide (Butyscol) intravenously for active peristalsis. The patient was placed lying on his/her left side or in the supine position during the insertion phase. Acoustic coupling at the transducer tip was achieved by filling the colonic lumen with 100 to 400 ml of deaerated water combined with changing the patient's position as needed in order to immerse the lesion.

A sigmoidscope (Olympus CF-200S, Tokyo, Japan) was used for lesions in the rectosigmoid colon. Those lesions located in the proximal colon were examined by withdrawing and shortening the colonoscope (Olympus CF-Q240, CF-Q260 AI/AL, Tokyo, Japan) to an insertion length of 70-90 cm after passing the lesion. EUS was performed by using an endoscopic ultrasonography system (Olympus EU-M30, Tokyo, Japan) and miniprobe (Olympus UM-2R/3R 12/20 MHz, Tokyo, Japan) introduced through the working channel after water infusion to immerse the lesion.

The maximal diameter, margin character, original layer, echotexture, and probable diagnosis of the tumor were recorded.

Management strategies

Lesions thought to be benign based on EUS examination such as lipomas, cystic lesions, and vascular lesions were managed with clinical follow up. However, a biopsy of lesions was done because of wall thickness. Lesions thought to have the potential for malignant change such as carcinoid tumors were managed by performing endoscopic mucosal resection using a transparent cap (EMR-C). Gynecologic ultrasonography or CT was performed in the case of indeterminate lesions. Based on the results of the above diagnostic procedures, patients either underwent surgical intervention or were clinically followed up.

RESULTS

Endoscopic ultrasonography examination sessions focused on the following anatomic locations: ascending colon and cecum, nine patients (23%); transverse and descending colon, three patients (7%); and rectosigmoid colon, thirty-two patients (70%).

The endoscopic ultrasonographic features and histologic diagnosis of the forty patients are shown in Table 1. Sixteen patients were diagnosed with rectal carcinoid tumor. On EUS, the carcinoid tumors were seen as well-defined hypoechoic lesions arising from the mucosa and submucosal layer. Thirteen were suspected of being carcinoid tumors (mean size, 6.9 ± 3.3 mm) and treated radically by endoscopic resections after it was confirmed by EUS that there was no muscular invasion (Fig. 1). Twelve were proved to be carcinoid tumor by histology and the other one was a hyperplastic polyp. Three other patients had no residual or recurrent carcinoid tumor on EUS examination after empirical biopsy or polyectomy. In ten patients EUS detected submucosal lipomas (mean size, 18.5 mm; range 8.6-25.6 mm); five tumors were located at the ascending colon and cecum, two at the transverse and descending colon, and three at the rectosigmoid colon. Under EUS lipomas were seen as ill-defined heterogeneous hyperechoic submucosal lesions. Two of the patients had undergone endoscopic resection: one had a tumor located at the sigmoid colon which was resected by piecemeal EMR and the other had a tumor located at the transverse colon with obstruction (Fig. 2). Five patients were diagnosed with rectal myogenic stromal tumor. These tumors were seen on EUS as ill-defined hypoechoic lesions in the muscularis propria (MP) layer. Three of these patients were transferred for surgical resection. Two lesions proved to be uterine myomas and another lesion was a mucinous adenocarcinoma of the appendix with rectal metastasis. The other two lesions were diagnosed as uterine myomas by gynecologic ultrasound or CT. One appendiceal stone with orifice obstruction mimicking a cecal submucosal tumor was proved by surgical resection (Fig. 3). One patient was diagnosed with submucosal vascular plexus. The lesion proved to be hemorrhoids by hemorrhoidectomy.

Three patients were diagnosed with lymphoangioma (Fig. 4). On EUS these lesions were visualized as anechoic cystic lesions with septal structures located in the third layer and confined to the submu-

Table 1. Endoscopic Ultrasonography Features and Histologic Diagnosis of Forty Patients with Colorectal Subepithelial Lesions

EUS Diagnosis	No. of patients	Mean size/ range (mm)	No. of pathology diagnoses (%)	Imaging and F/U (%)
Carcinoid tumor	13 3*	6.9 ± 3.3	15 Carcinoid (94%) hyperplastic polyp (6%)	
Lipoma	10	18.5 8.6-25.6	2 Lipoma (20%)	8 Clinical F/U (80%)
Myogenic stromal tumor	5	20.8 8.0-26.4	2 Uterine myoma (40%); 1 Mucinous adenocarcinoma of appendix, with metastasis (20%),	2 Uterine myoma (40%)‡
Lymphoangioma	3	6.7-25.3		1 EUS F/U (33%); 2 Clinical F/U (67%)
Submucosal tumors	2	9.9, 15	1 Proctitis cystica profunda (50%)	1 Clinical F/U (50%)
Appendiceal stone	1	10.7	Appendiceal stone (100%)	
Endometriosis	1	21.2		1 Clinical F/U†
Diverticulosis	1	25.6		1 Clinical F/U
Submucosal vascular plexus	1	X§	1 Hemorrhoid (100%)	

Abbreviations: EUS: endoscopic ultrasonography; F/U: follow-up; *: Post-biopsy or polyectomy follow-up; †: Diagnosis by CT; ‡: Diagnosis by gynecologic ultrasound; §: infiltrative lesion.

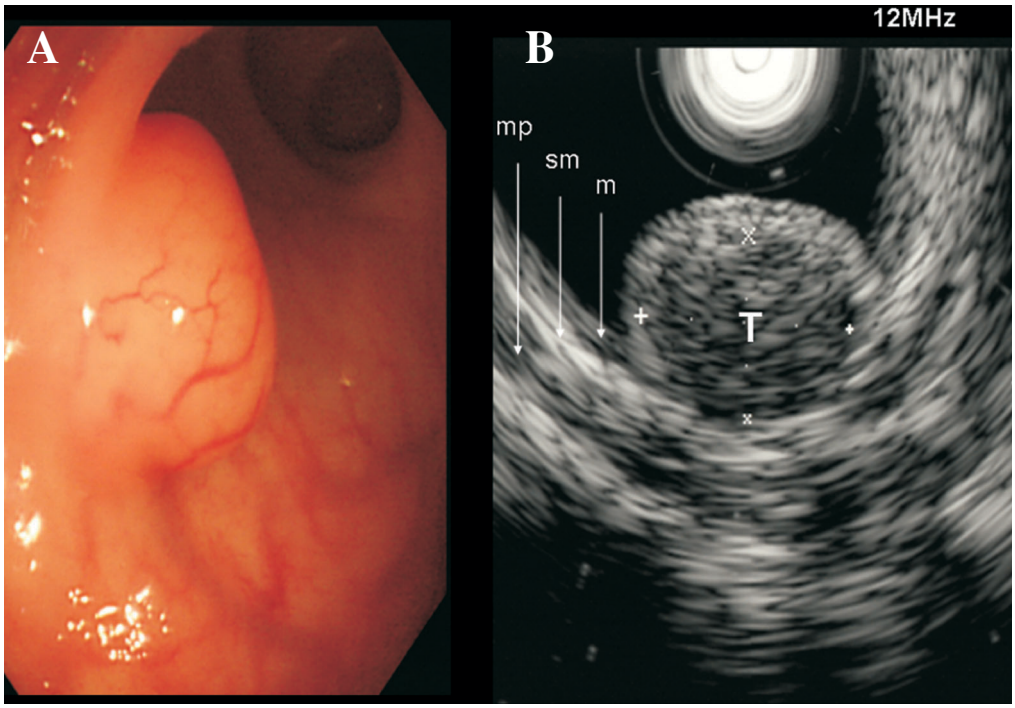

Fig. 1 (A) A 0.8 cm SEL in the rectum. (B) Miniprobe EUS (12 MHZ) was performed: a well-demarcated hypoechoic mass arising from the mucosa and deep submucosal layer was noted (T) and carcinoid tumor was suspected.

cosa and the underlying muscularis propriawas intact.[11]

The other four patients were diagnosed as follows: two had a submucosal tumor (one was proved to be proctitis cystica profunda by EMR-C), one had diverticulosis, and one had endometriosis. They were clinically followed up and there was no progression.

A total of thirty-five patients (88%) with colorectal SEL were managed uneventfully according to EUS interpretation. Our preliminary results showed that miniprobe EUS allows high-resolution imaging and a successful approach for all colorectal SEL during routine colonoscopy without breakdown of the miniprobe. The scanning time for the whole procedure was around five to thirty minutes (mean, twelve minutes).

DISCUSSION

With the wide use of colonoscopy for colonic lesion screening,more and more subepithelial lesions are being found.[12-14] Under endoscopic view they are seen as wide-based sessile lesions with an intact mucosal surface.[15] The nature of these lesions are difficult to determine based on an endoscopic view.

Previously, colorectal SEL were treated by surgical resection or managed by regular follow up with endoscopy or other type of imaging such as CT without obtaining pathologic information. For example, lipomas and cysts do not need further management and only need observation and follow-up by colonoscopy or other imaging method unless complications occur such as large intestine intussusception, obstruction, or bleeding caused by these lesions.[16] However, carcinoid tumors need further intervention by endoscopic or surgical resection due to potential malignant change.[17]

Hiroyuki reported that colorectal SEL can be easily distinguished by EUS which is helpful for formulating a subsequent management strategy based on the imaging characteristics of 46 patients.[15]

To the best of our knowledge there are only a few reports in the literature talking about the application of EUS for colorectal SEL.[17-19] Therefore, we were interested in finding out whether EUS can offer additional information about these lesions.

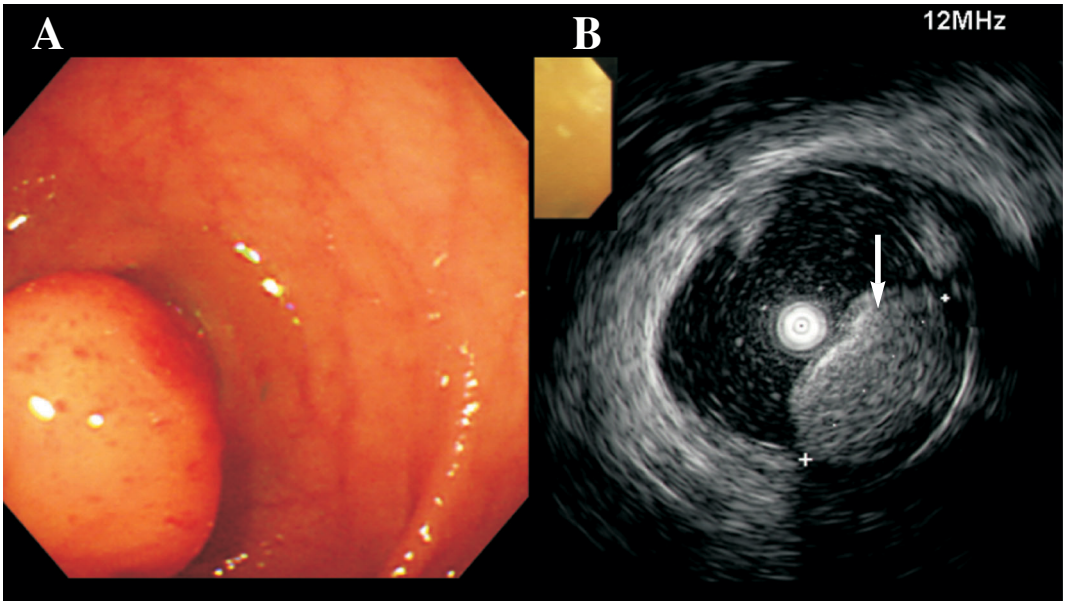

Fig. 2 (A) A 2.6 cm SEL in the sigmoid colon. (B) Miniprobe EUS (12 MHZ) was performed: a homogenous hyperechoic mass arising from the submucosal layer was noted (white arrow) and lipoma was suspected.

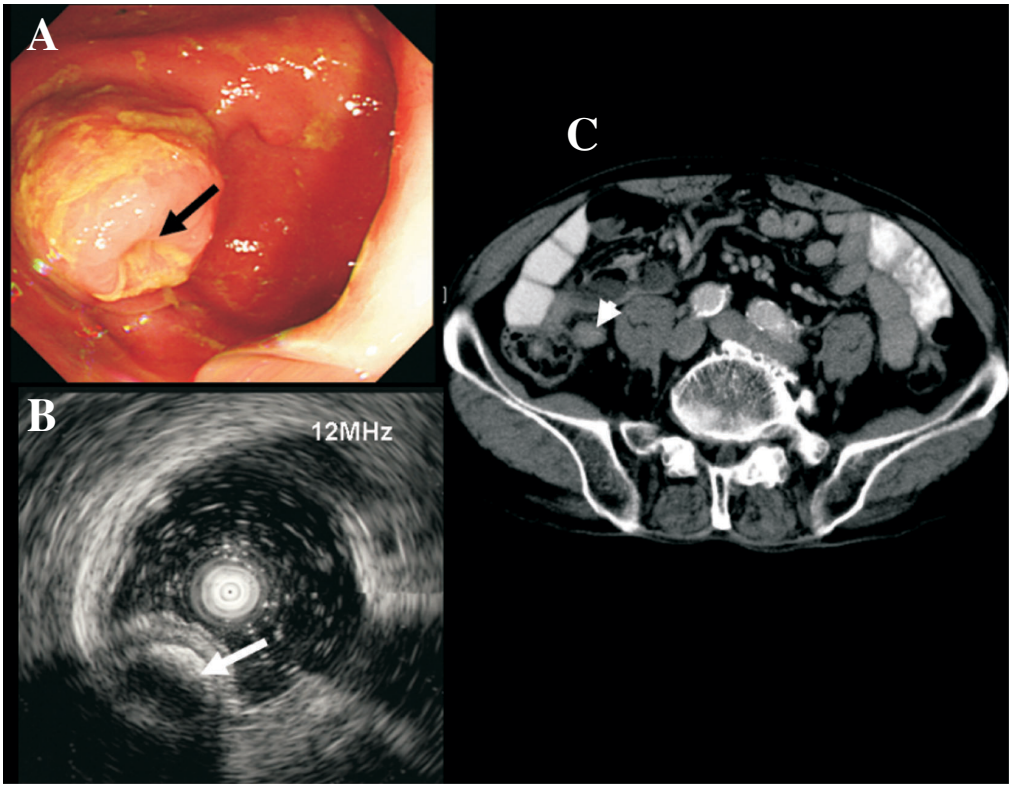

Fig. 3 (A) A protruding SEL with central umbilication suspect the orifice of appendix in the cecum (black arrow) (NOTE TO AUTHOR: please rewrite). (B) EUS (12 MHz) was performed: a calcification lesion measuring about 10.7 mm with acoustic shadow was noted (white arrow) in appendix lumen (C) In CT scan, only a swollen appendix was noted. (white arrow head).

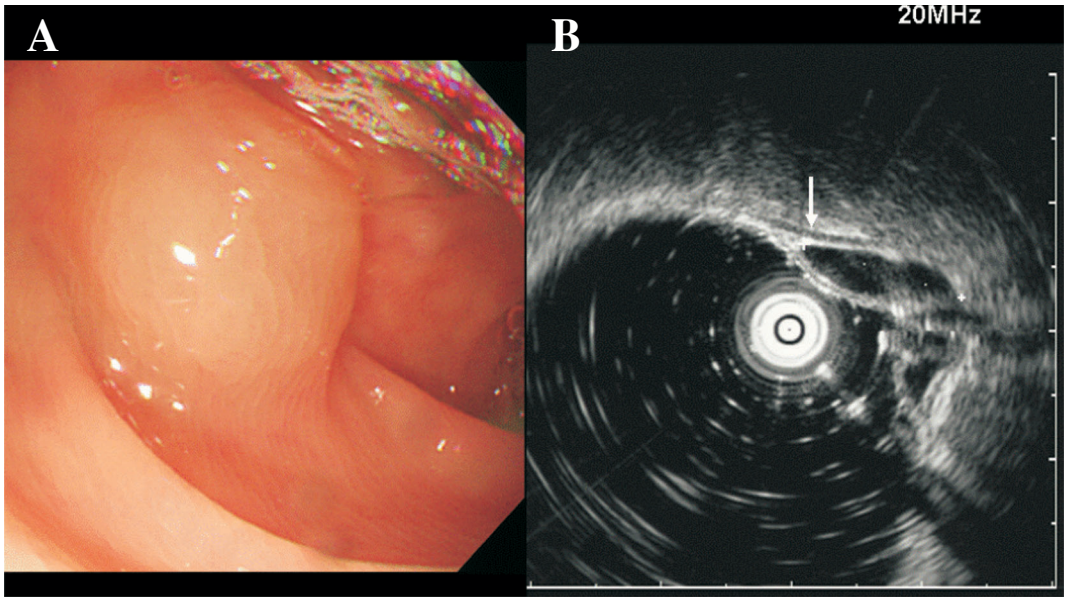

Fig. 4 (A) A 1.3 cm SEL in the descending colon. (B) Miniprobe EUS (20 MHZ) was performed: anechoic cystic lesions with septal structures located in the third layer and confined to the submucosa and the underlying muscularis propria (white arrow) is intact.

Endoscopic ultrasonography is the most sensitive technique for the preoperative staging of colorectal cancer.[1-5] This technique became widely used after the application of miniprobe EUS which overcame the limitations of conventional EUS such as instrument rigidity, inflexible large tip diameters, stenotic lesions, and difficulty with approaching lesions in the proximal colon.[6,7] However, most reports are still limited to rectosigmoid colonic lesions because of the instrument is expensive and easily breaks.

A number of techniques have been described to obtain adequate acoustic coupling between the miniprobe and the lesions. The two methods most frequently used are the condom technique and the balloon technique, both of which have advantages and disadvantages.[20-26]

In the condom technique, a latex condom is attached to the distal end of the endoscope. However, it obscures visualization and prevents air insufflation. Therefore, an endoscopy must first be performed without the condom. After advancing the endoscope to the target, the condom is filled with water through the working channel of the endoscope. Then the miniprobe is inserted through the working channel and acoustic coupling between the probe and the target area is achieved with no or minimal compression artifacts. However, air pockets between the condom and the gut wall may still be present, resulting in ultrasound image degradation.[20,23,24]

In the balloon technique, the catheter is inserted into a latex sheath with a distal balloon that can be instilled with water to facilitate acoustic coupling. Although this balloon-sheathed catheter is easy to work with,[25] it still has limitations in obtaining adequate acoustic coupling. Once the miniprobe has been inserted through the working channel of the scope, air pockets between the balloon and the gut wall are difficult to suction, leading to less than optimal image quality.[26]

In our study the immersion technique was used. This technique can be used in any location where the water will not migrate. The miniprobe was passed through to the lesion from the working channel of the scope after instilling water into the lumen to permit acoustic coupling as mentioned above. This method is easier to perform and, unlike the condom or balloon techniques, has no disadvantages.

Our preliminary results support the view that miniprobe ultrasonography can be easily performed during routine colonoscopy by withdrawing and shortening the colonoscope and passing the miniprobe through the working channel, and may have a considerable impact on management of sus-

pected colorectal SEL (e.g., carcinoid tumor, lipoma, extramural lesion) while only taking minutes in one intubation. Thus, the patient who has large intestine SEL detected by CT or lower GI barium examination and needs correlation with colonoscopy or routine colonoscopy can have EUS performed at the same time. Also, this technique can also be used in patients who need further follow-up after EMR for rectocolonic submucosal tumors such as carcinoid tumors. This decreases the discomfort of the patient and increases the patient's willingness to receive another examination session.

However, miniprobe ultrasonography still has some limitations. For example, some of our patients who were thought to have a rectal myogenic stromal tumor in the muscularis propria layer based on EUS were finally diagnosed with uterine myoma based on finding a metastatic lesion by pathology, gynecologic ultrasound, or CT scan. The limitations can be attributed to the suboptimal scanning quality of large (>2 cm) colonic lesions because of poor imaging of the deepest part of the tumor caused by attenuation of the ultrasound signal,[27] a lack serosa in the rectum, angulation of a portion of the colon, and lack of operator's experience.

Nevertheless, EUS is still better than CT or lower GI series for detection of small (<2 cm) colonic lipomas, cystic lesions, and hemorrhoids. This may be related to peristalsis of the intestine during CT scanning or lower GI series examination. For example, one of our patients who had a cecal submucosal tumor was suspected of having an appendiceal stone by EUS but only showed swelling of the appendix on CT (Fig. 3).

In our patients who underwent endoscopic resection for, for example, carcinoid tumor there was no lesion recurrence on regular follow-up.

Based on our findings we suggest that miniprobe ultrasonography can be a useful supplement to routine colonoscopy and be used for treatment guidance for suspected colorectal SEL.

REFERENCES

1. Hünerbein M, Totkas S, Ghadimi BM, Peter M, Schlag PM. Preoperative evaluation of colorectal neoplasms by colonoscopic miniprobe ultrasonography. Ann Surg 2000;232:46-50.
2. Beart RW, Steele GD Jr, Menck HR, Chmiel JS, Ocwieja KE, Winchester DP. Management and survival of patients with adenocarcinoma of the colon and rectum: a national survey of the Commission on Cancer. J Am Coll Surg 1995;181:225-36.
3. Zaheer S, Pemberton JH, Farouk R, Dozois RR, Wolff BG, Ilstrup D. Surgical treatment of adenocarcinoma of the rectum. Ann Surg 1998;227:800-11.
4. Heimann TM, Oh C, Steinhagen RM, Greenstein AJ, Perez C, Aufses AH Jr. Surgical treatment of tumors of the distal rectum with sphincter preservation. Ann Surg 1992;216:432-6.
5. Huang CH, Yan YH, Yeun Tarl Fresner Ng Jao, Fang SM, Lin YL, Chen CY. Preoperative staging of colorectal carcinoma by a 20 MHz minprobe endoscopic ultrasonography. Gastroenterol J Taiwan 2008;25:236-41.
6. Kuntz C, Kienle P, Buhl K, Glaser F, Herfarth C. Flexible endoscopic ultrasonography of colonic tumors: indications and results. Endoscopy 1997;29:865-70.
7. Rifkin MD, Ehrlich SM, Marks G. Staging of rectal carcinoma: prospective comparison of endorectal US and CT. Radiology 1989;170:319-22.
8. Hurlstone DP, Cross SS, Sanders DS. 20-MHz high-frequency endoscopic ultrasound-assisted endoscopic mucosal resection for colorectal submucosal lesions: a prospective analysis. J Clin Gastroenterol 2005;39:596-9.
9. Waxman I, Saitoh Y. Clinical outcome of endoscopic mucosal resection for superficial GI lesions and the role of high-frequency US probe sonography in an American population. Gastrointest Endosc 2000;52:322-7.
10. Chak A, Canto M, Stevens PD, Lightdale CJ, Van DE, Mierop F, Cooper G, Pollack BJ, Sivak MV. Clinical application of a new through-the-scope probe: prospective comparison with an ultrasound endoscope. Gastrointest Endosc 1997;45:291-5.
11. Atsushi Irisawa, Manoop S, Bhutani. Cystic lymphoanginoma of the colon: endosonographic diagnosis with through-the-scope catheter miniprobe and determination of further management: report of a case. Dis Colon Rectum 2001:44;1040-2.
12. Kawamoto K, Eyama T, Iwashi I, Utsunomiya T, Honda H, Onitsuka H, Haraguchi Y, Kojima N, Takano H, Masuda K. Colonic submucosal tumors: comparison of endoscopic US and target air-enema CT with barium enema study and colonoscopy. Radiology 1994;192:697-702.
13. Shimizu S, Tada M, Kawai K. Use of endoscopic ultrasonography for the diagnosis of colorectal tumors. Endoscopy 1990;22:31-4.
14. Skaane P, Sandbaek G. Ultrasound and CT evaluation of pedunculated gastrointestinal lipomas. Radiology 1990;30:12-4.
15. Kameyama H, Niwa Y, Arisawa T, Goto H, Hayakawa T. Endoscopic ultrasonography in the diagnosis of submucosal lesions of the large intestine. Gastrointest Endosc 1997;46:406-11.

16. Ananya D, Amitabh C. Endoscopic ultrasound-guided fine-needle aspiration of gastrointestinal submucosal masses. Techniques Gastrointest Endosc 2000;2:155-8.
17. Mashimo Y, Matsuda T, Uraoka T, Yutaka S, Sano Y, Kuangi FU, Kozu T, Ono A, Fujii T, Saito D. Endoscopic submucosal resection with a ligation device is an effective and safe treatment for carcinoid tumors in the lower rectum. J Gastroenterol Hepatol 2008;23:218-21.
18. Waxman I, Saitoh Y, Raju GS, Watari J, Yokota K, reeves AL, Kohgo Y. High-frequency probe EUS-assisted endoscopic mucosal resection: a therapeutic strategy for submucosal tumours of the GI tract. Gastrointest Endosc 2002;55:44-9.
19. Zhou PH, Yao LQ, Zhong YS, He GJ, Xu MD, Qin XY. Role of endoscopic miniprobe ultrasonography in diagnosis of submucosal tumor of large intestine. World J Gastroenterol 2004;10:2444-6.
20. Kawamoto K, Yamada Y, Furukawa N, Utsunomiya T, Haraguchi Y, Mizuguchi M, Oiwa T, Takano H, Masuda K. Endoscopic submucosal tumorectomy for gastrointestinal tumors restricted to the submucosa: a new form of endoscopic minimal surgery. Gastrointest Endosc 1997;46:311-7.
21. Norton ID, Bruce CJ, Seward JB, Vazquez-Sequeiros E. Initial experience with a steerable, phased vector array ultrasound catheter in the GI tract. Gastrointest Endosc 2001;53:496-9.
22. Shamoun DK, Norton ID, Levy MJ, Vazquez-Sequeiros E. Use of a phased vector array US catheter for EUS. Gastrointest Endosc 2002;56:430-5.
23. Inoue H, Kawano T, Takeshita K, Iwai T. Modified soft-balloon methods during ultrasonic probe examination for superficial esophageal cancer. Endoscopy 1998;30 Suppl 1:A41-3.
24. Wallace MB, Hoffman BJ, Sahai AS, Inoue H. Imaging of esophageal tumors with a water-filled condom and a catheter US probe. Gastrointest Endosc 2000;51:597-600.
25. Tseng LJ, Jao YT, Mo LR. Preoperative staging of colorectal cancer with a balloon-sheathed miniprobe. Endoscopy 2002;34:564-8.
26. Fockens P, van Dullemen HM, Tytgat GN. Endosonography of stenotic esophageal carcinomas: preliminary experience with an ultra-thin, balloon-fitted ultrasound probe in four patients. Gastrointest Endosc 1994;40:226-8.
27. Waxman I. Endosonography-assisted endoscopic mucosal resection of submucosal tumors of the gastrointestinal tract. Techniques Gastrointest Endosc 2002;4:47-50.

細徑探頭內視鏡超音波在大腸直腸上皮下病灶診斷之應用

陳聰興 林淳榮 吳仁欽[1] 何玉彬 許振銘 林偉彬 曾育彬 陳正雄 邱正堂

背 景： 內視鏡超音波對於腸胃道上皮下病灶的診斷是一種很有用的工具。然而，受限於傳統器械本身的耐用度及不易達到病灶的位置，此種診斷方法除了應用於遠端的大腸直腸癌的分期，並不被廣泛應用於其他病灶的診斷。此研究的目的是評估細徑探頭大腸內視鏡超音波在大腸上皮下病灶之鑑別診斷及治療方針的價值。

方 法： 四十位疑似有大腸上皮下病灶或是經過內視鏡切除術後來追蹤是否有殘餘病灶的病患接受細徑探頭內視鏡超音波的檢查。內視鏡超音波檢查的影像及報告重新檢視後再跟最後的病理報告，其他影像檢查或臨床追蹤來做確認。

結 果： 經由大腸鏡或乙狀結腸鏡工作管腔實施細徑探頭內視鏡超音波檢查術，不但可以成功的完成所有大腸上皮下病灶的檢查，並可以提供高解析度的影像而不會造成器械的損傷。在 40 例病人中，16 例診斷爲類癌，其中 13 例 (平均大小 6.9 ± 3.3 mm) 經內視鏡超音波檢查確定沒有侵犯到肌肉層後接受完整內視鏡黏膜切除術；另外 3 例爲經過切片或內視鏡黏膜切除術後以內視鏡超音波檢查確認沒有復發或有殘餘病灶。10 例診斷爲脂肪瘤 (平均大小 18.5 mm，範圍 8.6-25.6 mm)，其中兩例接受內視鏡切除。疑似肌質瘤有 5 例：3 例接受開刀，其中 2 例證實爲子宮肌瘤壓迫，一例爲闌尾腺癌合併直腸轉移，剩下 2 例經婦科超音波或電腦斷層診斷爲子宮肌瘤。1 例闌尾結石造成開口阻塞表現類似盲腸黏膜下腫瘤經開刀證實。1 例經開刀證實爲痔瘡。1 例經內視鏡內視鏡黏膜切除術證實爲 Proctitis cystica profunda。其餘 6 例爲各種良性病灶，經內視超音波診斷及追蹤沒有更進一步變化。40 個病人中有 35 個 (88%) 病人的上皮下病灶可以依據內視超音波結果得到準確的處置。

結 論： 我們的初步結果顯示細徑探頭內視鏡超音波在一般大腸鏡檢時，對於疑似有大腸上皮下病灶的病患，可以提供良好的輔助診斷及治療的方針。

(長庚醫誌 2010;33:380-8)

關鍵詞： 上皮下病灶，細徑探頭內視鏡超音波，內視鏡黏膜切除術

長庚醫療財團法人林口長庚紀念醫院 胃腸肝膽科，[1]病理科；長庚大學 醫學院
受文日期：民國98年3月4日；接受刊載：民國98年8月13日
通訊作者：林淳榮醫師，長庚醫療財團法人林口長庚紀念醫院 胃腸肝膽科。桃園縣333龜山鄉復興街5號。
Tel.: (03)3281200轉8107; Fax: (03)3272236; E-mail: ma1249@cgmh.org.tw