

## The Role of Endoscopic Ultrasonography Examination for Evaluation and Surveillance of Gastric Subepithelial Masses

Cheng-Hung Chien, MD; Rong-Nan Chien, MD; Cho-Li Yen, MD; Kua-Meen Fang, MD; Ching-Jung Liu, MD; Chih Lang Lin, MD; Jia-Jang Chang, MD; Li-Wei Chen, MD; Tsung-Shih Lee, MD; Shuo-Wei Chen, MD; Ching-Chih Hu, MD; Liang-Che Chang<sup>1</sup>, MD

**Background:** Endoscopic ultrasonography (EUS) has often been used to evaluate gastric subepithelial masses (SEM) and their malignant potential. Information on the use of EUS to survey small gastric SEM is limited.

**Methods:** A total of 125 consecutive patients referred for evaluation of a suspected gastric SEM were evaluated by EUS from February 2002 to February 2008. Periodic surveillance using EUS or upper gastrointestinal endoscopy was routinely advised. Surgical treatment was considered if a malignant tumor was suspected or symptomatic.

**Results:** In the 125 patients, EUS found 23 (18.4%) cases of extraluminal compression, 70 (56%) gastrointestinal stromal tumors (GISTs), 9 (7.2%) cases of ectopic pancreas, 5 (4.0%) mucosal tumors, 3 (2.4%) cases of varices, 2 (1.6%) cysts, 2 (1.6%) lipomas, 1 (0.8%) mucosal polyp, 1 (0.8%) submucosal tumor, 6 (4.8%) patients with no abnormality, and 3 (2.4%) unidentified lesions. Surgery was performed in 15 patients, revealing GISTs in 10 patients, and gastrointestinal autonomic nervous tumors (GANTs) in 2 patients as well as other malignant lesions in 3 patients. The pathological findings confirmed that 11 (73.3%) of 15 larger tumors (>30 mm) were accurately diagnosed. Only 1 of 9 suspected GIST (mean initial tumor size  $13.4 \pm 8.3$  mm, mean follow-up period 23 months), in the EUS surveillance group significantly increased in size, and surgical pathology disclosed a GIST with intermediate malignant potential.

**Conclusions:** For evaluating gastric SEM, EUS is able to accurately differentiate intramural from extramural lesions and aid in narrowing the differential diagnosis. In this limited case study, most small gastric SEM (<30 mm) did not exhibit size changes during follow-up. If the tumor size increases or the ultrasonographic features of a tumor suggest malignant possibility during EUS surveillance, surgical resection should be considered.

(*Chang Gung Med J* 2010;33:73-81)

**Key words:** subepithelial mass, gastrointestinal stromal tumor, endoscopic ultrasonography

---

From the Department of Hepato-Gastroenterology; <sup>1</sup>Department of Pathology, Chang Gung Memorial Hospital at Keelung, Chang Gung University College of Medicine, Taoyuan, Taiwan.

Received: Aug. 4, 2008; Accepted: Apr. 15, 2009

Correspondence to: Dr. Rong-Nan Chien, Department of Hepato-Gastroenterology, Chang Gung Memorial Hospital at Keelung, 222, Maijin Rd., Anle District, Keelung City 204, Taiwan (R.O.C.) Tel.: 886-2-24313131 ext. 3171; Fax: 886-2-24335342; E-mail: ronald@cgmh.org.tw

**S**ubepithelial masses (SEM) in the stomach are relatively common findings in patients undergoing an upper gastrointestinal (UGI) endoscopy. Protrusion of the gastric wall can be caused by intramural as well as extraluminal compression. The entities responsible for protrusion include lipomas, vascular structures, cysts, an ectopic pancreas, extramural structures, and neoplastic lesions. These entities are occasionally large and may outgrow their blood supply, resulting in ulceration or hemorrhage.<sup>(1)</sup> Accurate differentiation of these types of lesions is crucial, because previous studies have shown that up to 1 of 5 subepithelial lesions neoplastic.<sup>(2)</sup> An endoscopic ultrasonography (EUS) can reliably enable the differentiation of intramural lesions from extrinsic compression. Further, if an intramural lesion is identified, EUS can be performed to ascertain the exact size of the lesion, identify the layer of its origin, and observe additional morphological features in the lesion that could aid diagnosis. Mesenchymal tumors, which are traditionally termed gastrointestinal smooth muscle or myogenic tumors, account for a significant proportion of all SEM. In a recent study, 1869 tumors that were originally classified as smooth muscle tumors of the stomach were reevaluated, and the results revealed that 1765 (94%) of these were in fact gastrointestinal stromal tumors (GISTs).<sup>(3)</sup> Following recent advances that have improved the general understanding of the pathogenesis and biology of GISTs, a National Institutes of Health consensus conference in the United States issued a proposal that all GISTs should be considered to have malignant potential.<sup>(4)</sup> GISTs with a diameter of > 3 cm should be treated by complete tumor resection.<sup>(5)</sup> However, no guidelines are currently available for the management of small GISTs that are not accompanied by symptoms and that exhibit features indicating a low malignant potential on EUS. The percentage of small GISTs that grow larger during specific surveillance periods remains uncertain. Here, we report our results of EUS performed to evaluate the status of gastric SEM over a 6-year period. We propose strategies, including EUS surveillance and surgical resection, for the presumptive diagnosis and management of GISTs.

## METHODS

Our study involved all patients who were con-

secutively referred to our hospital from February 2002 to February 2008 for an EUS to examine a SEM that was previously identified during an UGI endoscopy. The EUS examinations were performed by a single investigator (RNC), using a radial-scanning echoendoscope (Olympus GF-UMQ240 7.5 MHz, Tokyo, Japan) and an endoscopic ultrasound system (Olympus EU-M30, Tokyo, Japan). A presumptive EUS assessment was made on the origin of the lesion (intramural lesion or extraluminal compression). If the lesion was identified as extraluminal compression, we recorded whether the compression was caused by a normal organ or by some other pathological lesion. If the lesion was identified as an intramural lesion, the examiner recorded its echotexture (whether it was inhomogeneous or homogeneous and exhibited hyperechoic, hypoechoic, or mixed echoic patterns), layer of origin, and outer-margin regularity (regular or irregular) as well as whether adjacent lymph nodes were affected. To determine the tumor size, 2 dimensions of the lesion were measured, and the larger measurement was considered the maximal diameter of the lesion. In addition, the examiner recorded a presumptive or possible differential diagnosis. On the basis of the EUS findings, we considered a tumor potentially malignant if it was > 30 mm, had an irregular or poorly defined margin, or had a heterogeneous echotexture.<sup>(5-7)</sup> Surgery was considered if the lesion had 2 or more the above characteristics or exhibited repeated bleeding. If surveillance was considered necessary, EUS or UGI endoscopy was performed at various intervals, subject to the presumptive diagnosis of the examiner and the patient's consent. If UGI endoscopy surveillance was selected, the tumor size was measured by the forceps opening method. The final histopathological diagnosis was made following surgery, and in a few cases, samples were retrieved from biopsy.

## Statistical analysis

Stepwise logistic regression model was performed to determine whether the malignant potential of the GIST was related to the following EUS features: tumor size, echo texture, and margin irregularity. The tumor size was fitted as a continuous variable. A stepwise logistic regression model was used with generous *p* values for entry (*p* = 0.10) and exit (*p* = 0.20) criteria so that the study was controlled for

characteristics with a marginal association. Statistical significance was tested by the maximum likelihood function. The analysis software was the Statistical Package for the Social Sciences (SPSS Inc. Chicago, Illinois.) version 11.5.

## RESULTS

In total, 125 patients (54 men and 71 women; mean age, 56 years; range, 17–83 years), who were suspected to have gastric SEM on the basis of UGI endoscopic findings, underwent EUS evaluations. Of the 125 patients, the lesions were identified by EUS as extraluminal compression in 23 (18%), GIST in 70 (56%), ectopic pancreas in 9 (7%), mucosal tumors in 5 (4%), and other findings in 9 (7%) patients. The lesions could not be identified by EUS in 3 (2%) patients. Further, in 6 (5%) cases, the EUS findings could not explain the GI wall protrusion that was noted during UGI endoscopy. Histopathological confirmation was available in 21 patients (18 with surgery, 1 with endoscopic submucosal resection, 2 with mucosal deep biopsy) (Table 1).

### Extraluminal compression

Twenty-three patients exhibited extragastric

compression. In 12 of these patients, the compression was caused by healthy organs, including the liver (n = 6), spleen (n = 2), splenic vessels (n = 2), left kidney (n = 1), and aorta (n = 1). In 6 patients, the compression was caused by benign pathological lesions such as liver cysts (n = 4), an accessory spleen (n = 1), and a cyst of an unknown origin (n = 1). In 5 patients, the causes could not be identified.

### GIST

EUS examination led to a presumptive diagnosis of GIST in 70 patients. The mean maximal tumor diameter was  $20 \pm 18$  mm (range, 3–83 mm). Sixty-two (88.6%) originated from the muscularis propria, 2 (2.9%) from the muscularis propria as well as the submucosa, 1 (1.4%) from the submucosa, and the other 5 (7.1%) from the muscularis mucosa. Forty-two (60.0%) tumors exhibited hypoechoic patterns, 24 (34.3%), mixed echoic patterns, and only 1 (1.4%), an isoechoic pattern. EUS revealed malignant patterns in the tumors of 15 (21.4%) patients (7 men and 8 women; mean age, 59 years; range, 38–80 years). The mean tumor size was  $49 \pm 13$  mm (range 35–83 mm). Central ulceration was noted in 7 of these tumors and bleeding in 4. Further, 5 (33.3%) of these tumors exhibited an irregular margin. In the

**Table 1.** EUS Findings in Gastric Subepithelial Masses

EUS initial diagnosis	Case no. (%)	Final histologic diagnosis (case no.)
GIST	70 (56)	GIST (13), GANT (2), Adenocarcinoma (2), Hepatocellular carcinoma (1), Carcinoid (1)
Ectopic pancreas	9 (7.2)	
External compression	23 (18.4)	
Cyst	2 (1.6)	
Submucosal tumor	1 (0.8)	
Varices	3 (2.4)	
Mucosal polyp	1 (0.8)	
Lipoma	2 (1.6)	
Mucosal tumor	5 (4.0)	GIST (1), Adenocarcinoma (1)
No abnormality	6 (4.8)	
Unidentified lesion	3 (2.4)	
Total	125	21

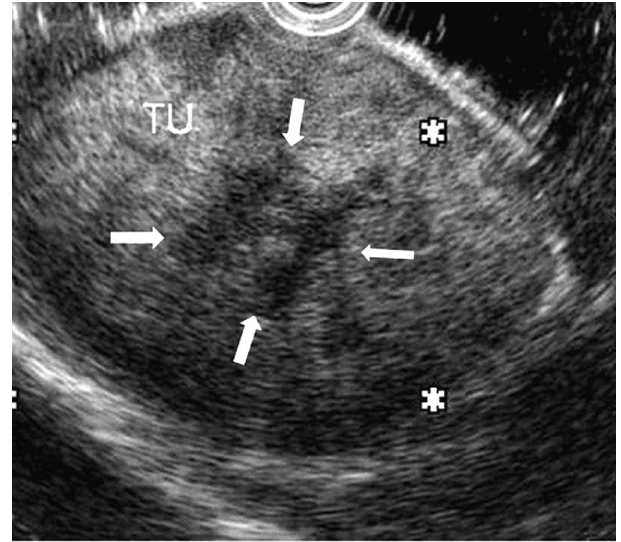
**Abbreviations:** GIST: gastrointestinal stromal tumor; GANT: gastrointestinal autonomic nervous tumor.

remaining 55 tumors (27 men and 28 women; mean age, 58 years; range, 26–83 years, mean size:  $12 \pm 7$  mm) exhibiting benign patterns, only 1 exhibited an irregular margin.

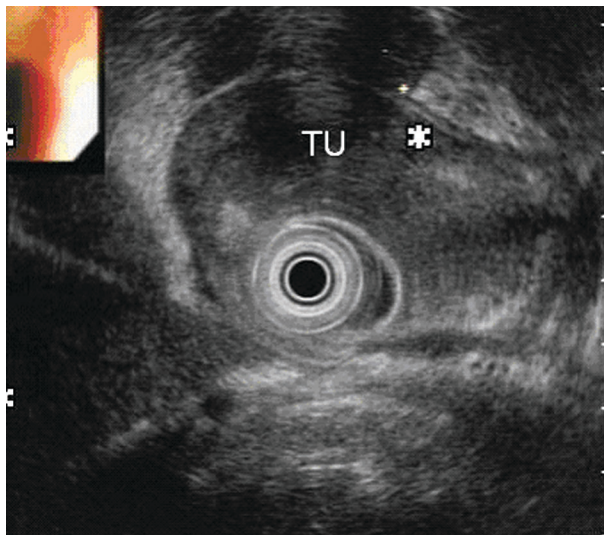
Fifteen patients underwent surgical treatment because malignancy was suspected on the basis of the EUS findings ( $n = 14$ ) or because of GI bleeding ( $n = 1$ ). On the basis of the pathological findings, 10 tumors were diagnosed as GISTs; 2, as gastrointestinal autonomic nervous tumors (GANTs); 2, as gastric adenocarcinomas, and 1 as hepatocellular carcinoma (HCC) with gastric invasion (Fig. 1 and 2). Immunohistochemical staining was performed on the tumor tissue obtained from 11 patients; positive staining for C-kit was noted in the tumor tissue of 9 GISTs and 1 GANT. Three GISTs were classified in the intermediate- or high-risk group, while 5 GISTs and 2 GANTs were classified in the low-risk group. In 2 GISTs, the malignant potential was not assessed. The EUS-based diagnosis was incorrect in 3 patients, including 2 gastric adenocarcinomas and 1 HCC with gastric invasion.

One 4-cm mixed echoic, heterogeneous tumor, which was originally diagnosed as a malignant GIST based on the EUS results (Fig. 3), was subsequently suspected to have arisen from gastric tuberculosis (TB) since disseminated TB infection was detected. A follow-up UGI endoscopy performed 1 month

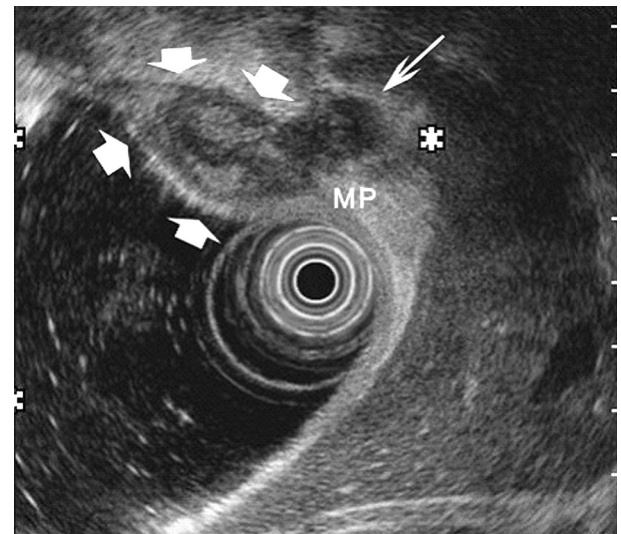
after anti-TB therapy was initiated revealed the gastric SEM had disappeared. In addition, 1 patient with a small GIST (12 mm) in the cardia underwent endoscopic submucosal resection; this patient had expressed a strong desire to undergo the procedure.



**Fig. 2** A presumed GIST at the fundus is found to be hepatocellular carcinoma with stomach involvement. The tumor (TU) appears as an 83-mm heterogeneous, mixed echoic mass with a central star sign (arrows).



**Fig. 1** A presumed GIST at the distal antrum is found to be gastric adenocarcinoma. The tumor (TU) appears as a 55-mm mixed echoic mass with a regular outer border.



**Fig. 3** A presumed GIST at the fundus is found to be gastric TB. The tumor appears as a 40-mm mixed echoic and heterogeneous mass (arrows) that is continuous with the muscularis propria (MP). A hypoechoic nodule (long arrow) is adherent to the mass.



The pathological findings confirmed the diagnosis of GIST.

The remaining 53 patients had a mean tumor size of  $12 \pm 7$  mm (range, 3–29 mm). Surveillance strategies were based on the clinical presentation, EUS features, individual risk and patient preference. During follow-up, 9 patients underwent repeated EUSs, and 16 underwent UGI endoscopy. The other patients were followed up during visits to the outpatient department or were lost to follow-up. The group that was followed by EUS surveillance comprised 9 patients (4 men and 5 women) with a mean age of 60 years (range, 28–80 years). The mean duration of follow-up was 23 months (range, 6–62 months), and the mean tumor size was  $13.4 \pm 8.3$  mm (range, 4–28 mm; Table 2). Eight of the tumors in these 9 patients remained hypoechoic masses exhibiting homogeneous echotextures and regular borders. Repeated EUS revealed that the size of these lesions had changed by less than 5 mm; one patient with a 28-mm tumor underwent surgical resection because GI bleeding was noted during follow-up at 15 months. Pathological analysis revealed a carcinoid tumor. The tumor in the remaining patient exhibited a mixed echoic and heterogeneous echotexture and a

regular border on index examination. This lesion size increased slightly, from 25 to 31 mm, by 35 months, and it increased by 23 mm 46 months after the index EUS. No relevant symptoms such as abdominal pain, GI bleeding, body weight loss, and anorexia were noted. Since the tumor size increased significantly and exhibited a greater malignant potential, surgical resection was performed. The pathological analysis, which revealed positive staining for both C-Kit and CD34, confirmed that the tumor was a GIST that had intermediate malignant potential. For the group that underwent UGI endoscopy (mean age, 66 years; range, 32–82 years), the mean duration of follow-up was 28 months (2–69 months), and the mean tumor size was  $14 \pm 8$  mm (range, 4–29 mm). During follow-up, the tumor size remained constant in 7, increased in 1, decreased in 1, and disappeared in 1 patients. Tumor disappearance could be explained by the small size of the tumors which were not visualized if there was insufficient air inflation. EUS features were analyzed to determine the malignant potential of the GIST, whereas there were no significantly independent variables predicting the risk of GISTs using multivariate analysis.

**Table 2.** Changes in GIST Features during EUS Follow-up

	Age (years) /gender	Location	EUS echotexture	Initial size (mm)	Final size (mm)	Change in size (mm)	Number of examinations	Follow-up period (months)	Outcome
1	54/F	HB	Homogeneous, hypoechoic	8	7	–1	5	62	Stable
2	60/F	Fundus	Homogeneous, hypoechoic	4	4	0	3	21	Stable
3	51/F	LB	Homogeneous, hypoechoic	4	3	–1	2	16	Stable
4	80/F	HB	Homogeneous, hypoechoic	8	9	+1	3	16	Stable
5	28/F	Cardia	Homogeneous, hypoechoic	16	13	–3	3	19	Stable
6	82/M	HB	Homogeneous, hypoechoic	18	18	0	2	6	Stable
7	62/M	Cardia	Homogeneous, hypoechoic	10	10	0	2	10	Stable
8	64/M	HB	Homogeneous, hypoechoic	28	28	0	2	14	Surgical resection carcinoid
9	61/M	MB	Mixed echoi	25	48	+23	6	46	Surgical resection GIST

**Abbreviations:** HB: high body; MB: middle body; LB: low body.

## DISCUSSION

It is clinically important to determine whether a SEM is intramural or extramural in origin and to evaluate the structural nature of a pathological lesion. Even when the endoscopist suspects that a lesion is intramural, the mass is found to arise from outside the gastrointestinal wall in up to 30% cases.<sup>(5,8)</sup> In a prospective study from the United States, Hwang et al demonstrated that EUS is an effective tool for differentiating intramural tumors from extramural subepithelial ones.<sup>(9)</sup> In our series, EUS revealed that a total of 23 (18.4%) SEM had arisen due to external compression. The external compression was most frequently caused by adjacent normal organs (9/23 or 39%), followed by benign pathological lesions (6/23 or 26%). The gastric high body is often compressed by the liver or a liver cyst. Further, previous studies have demonstrated that normal organs are the most common causes of external compression.<sup>(10,11)</sup>

Several studies have examined the utility of EUS for the evaluation of SEM and their subsequent management. In our study, 5 tumors suspected to be GISTs based on EUS results were subsequently found to be other types of tumors, 2 adenocarcinomas; 1 HCC; and 1 carcinoid tumor, along with 1 gastric TB. Further, the biopsy results confirmed that the initial presumptive diagnosis of multiple mucosal tumors was inaccurate in one case and that these tumors were in fact GISTs. In this study, it was difficult to precisely assess whether EUS can be used to achieve an accurate diagnosis. This is because many SEM are very small and exhibit benign characteristics during EUS, and tissue sampling is therefore not considered essential. The pathological findings confirmed that 11 of 15 larger tumors (>30 mm) were accurately diagnosed. In a study conducted by Hwang et al, 100 patients with SEM in the GI tract (including 54 gastric lesions) were enrolled.<sup>(9)</sup> The presumptive diagnosis based on the EUS findings was found to be inaccurate in 13 of 23 cases (57%) for which histological data were available. All the incorrect diagnoses corresponded to hypoechoic lesions located in the third and fourth EUS layers. Further, in a previous multicenter study, Rosch et al reported that EUS enabled an accurate diagnosis in 80% of all patients with benign submucosal tumors

and 64% of those with malignant submucosal tumors.<sup>(8)</sup> Brand et al observed that the sensitivity and specificity of EUS for the accurate diagnosis of 44 GISTs were 95% and 72%, respectively; however, only 56% of non-GIST lesions were accurately diagnosed using this technique.<sup>(12)</sup> The accuracy of EUS alone for the differential diagnosis of SEM has been disappointing. However, EUS allows for improved characterization of SEM, aiding the clinician in narrowing the differential diagnosis. In cases where EUS is not entirely conclusive, it is necessary to obtain tissue samples from the tumor in order to make a reliable diagnosis.

Patients with a vessel, ectopic pancreas, cyst or lipoma on EUS require no further follow-up. Recommended management of gastric carcinoid in patients with normal gastrin levels is aggressive surgical resection.<sup>(13)</sup> For hypergastrinemic patients, primary treatment options include endoscopic resection, local excision, or observation. If mucosal tumors such as carcinomas, carcinoid tumors and various rare conditions are excluded, GISTs account for most malignant or potentially malignant SEM. A published series on GISTs has described the tumor size and its mitotic index as the 2 most important prognostic features of a primary tumor.<sup>(14-19)</sup> Fine-needle aspiration biopsy (FNB) or cutting biopsy (trucut biopsy) can be safely performed for subepithelial lesions using linear-array echoendoscopes, wherein the puncture needle can be monitored in real time. However, this equipment was unavailable for the present study. Various studies have reported that EUS-guided FNB can be safely performed for SEM and can provide sufficient data for diagnosis in approximately 80% of cases.<sup>(20)</sup> However, GISTs may be soft and fragile, and biopsy may cause hemorrhage and increase the risk of tumor dissemination. Further, many pathologists cannot make a definitive diagnosis solely by evaluating the fine-needle aspirate.<sup>(21)</sup> The most significant drawback of EUS-guided FNB is that it is typically impossible to obtain a sufficient amount of tissue for histological analysis and immunohistochemical staining.<sup>(22)</sup> Usually, only resection can provide sufficient tissue material for determining the mitotic count. In clinical practice, patients who exhibit symptoms that can be attributed to the tumor should undergo endoscopic or surgical tumor resection. On the other hand, the appropriate management strategy for incidentally encountered

small GISTs less than 2 cm remains controversial. For many decades, such small tumors incidentally discovered during endoscopy have been termed leiomyomas and have been regarded as harmless. Due to the potential morbidity and mortality associated with surgical resection, it remains debated whether this procedure is acceptable for removing a lesion that exhibits a low potential for malignant transformation. In fact, the natural history of such small tumors, including their growth rate and metastatic potential, remains unknown. Therefore, a primary challenge with GISTs is distinguishing whether the lesions require surgical treatment or periodic surveillance. EUS currently plays a crucial role in the evaluation, diagnosis, and management strategy of suspected GISTs.

How can features revealed by EUS be used to assess the malignant potential of a tumor? Parameters assessed by EUS, including tumor size (> 3 cm), the irregularity of the extraluminal border, the presence of cystic spaces and echogenic foci, and heterogeneity, have been reported to be associated with an increased likelihood of malignant behavior in GISTs.<sup>(5-7)</sup> Polkowski pooled the results of 7 studies that involved 117 malignant or borderline malignant tumors, most of which were GISTs, and compared the features of these tumors, as determined by EUS, with those of 224 benign submucosal tumors.<sup>(20)</sup> Large size (> 30 or 40 mm) and an irregular margin seemed to be the most indicative parameters for diagnosis. In our series, 15 tumors exhibited malignant patterns, the mean tumor size was 49 mm, all tumors exhibited a mixed echoic and heterogeneous echotexture, and one-third of all tumors exhibited irregular margins. Pathological analysis confirmed 12 (80%) of the tumors to be GISTs or GANTs. Among these, 3 (43%) of 7 tumors with very low or low malignant potential and 1 (33%) of 3 tumors with intermediate or high malignant potential exhibited irregular margins. We emphasize that the features of the benign tumors revealed by EUS significantly overlapped with those of the malignant tumors.

In addition to the features revealed by EUS, an increase in the tumor size may be a predictor of malignant transformation. Rapid tumor growth is usually regarded as an alarming sign indicative of malignancy. However, no guidelines published thus far have defined "significant growth" with regard to

GISTs or SEM. In this study, no significant changes were noted in the size of the SEM, the tumor echotexture, or the appearance of the outer margin of the lesions during the 23 month follow-up period in patients who had EUS surveillance. A tumor that grew significantly was resected and was identified as an intermediate-grade GIST. One drawback of the present study was the relatively small number of patients in follow-up. This will bias the final conclusion. A further, prospective, large-scale study is warranted.

We conclude that most small gastric SEM (< 30 mm), among which GISTs are the most common, do not exhibit changes during follow-ups of approximate 2 years. A conservative policy of periodic surveillance is an alternative strategy, but it should be done for an extended period. If the tumor size increases or the ultrasonographic features suggest malignant possibility, such as an irregular tumor margin, surgical resection should be considered.

## REFERENCES

1. Chak A. EUS in submucosal tumors. *Gastrointest Endosc* 2002;56 Supp 14:S43-8.
2. Eckardt AJ, Wassef W. Diagnosis of subepithelial tumors in the GI tract. Endoscopy, EUS, and histology: bronze, silver, and gold standard? *Gastrointest Endosc* 2005;62:209-12.
3. Miettinen M, Sobin LH, Lasota J. Gastrointestinal stromal tumors of the stomach: a clinicopathologic, immunohistochemical, and molecular genetic study of 1765 cases with long-term follow-up. *Am J Surg Pathol* 2005;29:52-68.
4. Fletcher CDM, Berman JJ, Corless C, Gorstein F, Lasota J, Longley BJ, Miettinen M, O'Leary TJ, Remotti H, Rubin BP, Shmookler B, Sobin LH, Weiss SW. Diagnosis of gastrointestinal stromal tumors: A consensus approach. *Hum Pathol* 2002;33:459-65.
5. Hwang JH, Rulyak SD, Kimmey MB; American Gastroenterological Association. American Gastroenterological Association Institute technical review on the management of gastric subepithelial masses. *Gastroenterology* 2006;130:2217-28.
6. Tsai TL, Changchien CS, Hu TH, Hsiaw CM, Hsieh KC. Differentiation of benign and malignant gastric stromal tumors using endoscopic ultrasonography. *Chang Gung Med J* 2001;24:167-73.
7. Jeon SW, Park YD, Chung YJ, Cho CM, Tak WY, Kweon YO, Kim SK, Choi YH. Gastrointestinal stromal tumors of the stomach: endosonographic differentiation in relation to histological risk. *J Gastroenterol Hepatol* 2007;22:2069-75.

8. Rosch T, Kapfer B, Will U, Baronius W, Strobel M, Lorenz R, Ulm K; German EUS Club. Endoscopic ultrasonography. Accuracy of endoscopic ultrasonography in upper gastrointestinal submucosal lesions: a prospective multicenter study. *Scand J Gastroenterol* 2002;37:856-62.
9. Hwang JH, Saunders MD, Rulyak SJ, Shaw S, Nietsch H, Kimmey MB. A prospective study comparing endoscopy and EUS in the evaluation of GI subepithelial masses. *Gastrointest Endosc* 2005;62:202-8.
10. Motoo Y, Okai, T, Ohta H, Satomura Y, Watanabe H, Yamakawa O, Yamaguchi Y, Mouri I, Sawabu N. Endoscopic ultrasonography in the diagnosis of extraluminal compressions mimicking gastric submucosal tumors. *Endoscopy* 1994;26:239-42.
11. Chen TK, Wu CH, Lee CL, Lai YC, Yang SS, Tu TC. Endoscopic ultrasonography to study the causes of extragastric compression mimicking gastric submucosal tumor. *J Formos Med Assoc* 2001;100:758-61.
12. Brand B, Oesterhelweg L, Binmoeller KF, Sriram PVJ, Bohnacker S, Seewald S, De Weerth A, Soehendra N. Impact of endoscopic ultrasound for evaluation of submucosal lesions in gastrointestinal tract. *Dig Liver Dis* 2002;34:290-7.
13. Modlin IM, Kidd M, Latich I, Zikusoka MN, Shapiro MD. Current status of gastrointestinal carcinoids. *Gastroenterology* 2005;128:1717-51.
14. Appelman HD. Mesenchymal tumors of the gut: Historical perspectives, new approaches, new results and does it make any difference? *Monogr Pathol* 1990;31:220-46.
15. Somerhausen Nde S, Fletcher CDM. Gastrointestinal stromal tumours: An update. *Sarcoma* 1998;2:133-41.
16. Miettinen M, Lasota J. Gastrointestinal stromal tumors-Definition, clinical, histological, immunohistochemical and molecular genetic features and differential diagnosis. *Virchows Arch* 2001;438:1-12.
17. Ranchod M, Kempson RL. Smooth muscle tumors of the gastrointestinal tract and retroperitoneum: A pathologic analysis of 100 cases. *Cancer* 1977;39:255-62.
18. Evans HL. Smooth muscle tumors of the gastrointestinal tract: A study of 56 cases followed for a minimum of 10 years. *Cancer* 1985;56:2242-450.
19. DeMatteo RP, Lewis JJ, Leung D, Mudan SS, Woodruff JM, Brennan MF. Two hundred gastrointestinal stromal tumors: Recurrence patterns and prognostic factors for survival. *Ann Surg* 2000;231:51-8.
20. Polkowski M. Endoscopic ultrasound and endoscopic ultrasound-guided fine-needle biopsy for the diagnosis of malignant submucosal tumors. *Endoscopy* 2005;37:635-45.
21. Demetri GD, Benjamin RS, Blanke CD, Blay JY, Casali P, Choi H, Corless CL, Debiec-Rychter M, DeMatteo RP, Ettinger DS, Fisher GA, Fletcher CDM, Gronchi A, Hohenberger P, Hughes M, Joensuu H, Judson I, Le Cesne A, Maki RG, Morse M, Pappo AS, Pisters PWT, Raut CP, Reichardt P, Tyler DS, Van den Abbeele AD, von Mehren M, Wayne JD, Zalcberg J, Force NT. NCCN Task Force report: management of patients with gastrointestinal stromal tumor (GIST)--update of the NCCN clinical practice guidelines. *J Natl Compr Canc Netw* 2007;5 Suppl 2:S1-29:quiz S30.
22. Shah R, Jonnalagadda S. The GIST of a stromal tumor. *Gastroenterology* 2005;128:2170-1.



## 內視鏡超音波在評估和監測胃表皮下腫瘤之角色

錢政弘 簡榮南 嚴卓立 方昆敏 劉競榮 林志郎 張家昌 陳立偉  
李宗實 陳碩為 胡澍之 張良慈<sup>1</sup>

- 背景：**內視鏡超音波常用來評估胃表皮下腫瘤和其惡性程度，利用內視鏡超音波來監測小型胃表皮下腫瘤所知有限。
- 方法：**在 2002 至 2008 年間，共有 125 位病例因接受上消化道內視鏡檢查而懷疑有胃表皮下腫瘤，再進一步接受內視鏡超音波檢查而確認之，並依例建議病人每 6-12 個月使用內視鏡超音波或上消化道內視鏡追蹤一次以監測病灶。若懷疑其為惡性腫瘤或發生反覆出血則考慮手術治療。
- 結果：**在 125 位病例中，內視鏡超音波檢查結果為 23 (18.4%) 例腔室外壓迫，70 (56%) 例胃腸道基質瘤，9 (7.2%) 例異位胰臟，5 (4.0%) 例黏膜腫瘤，3 (2.4%) 例胃靜脈曲張，2 (1.6%) 例囊腫，2 (1.6%) 例脂肪瘤，1 (0.8%) 例瘰癧肉，1 (0.8%) 例黏膜下腫瘤，6 (4.8%) 例無異常和 3 (2.4%) 例不明病灶。有 15 位病患接受手術治療，結果顯示有 10 位病患有胃腸道基質瘤，2 位有胃腸自律神經瘤和 3 位其他惡性病灶。對於較大的腫瘤 (> 3 公分)，組織病理檢查證實腫瘤診斷的正確性有 73.3%。在 9 位規則接受內視鏡超音波監測的病患中 (平均追蹤 23 個月，平均大小 13.4 ± 8.3 公釐)，僅 1 (11%) 位病患的腫瘤有顯著的增大，經手術切除後證實其為中等程度的惡性胃腸道基質瘤。
- 結論：**在評估胃表皮下腫瘤方面，內視鏡超音波可以準確地分辨腔室外壓迫或腔室內病灶和縮小鑑別診斷範圍。大多數小型的胃表皮下腫瘤 (大小 < 3 公分) 在追蹤中並無發生腫瘤大小的變化。若以內視鏡超音波監測過程中，發現腫瘤有增大或型態上有惡性的表徵，則必須考慮手術切除。
- (長庚醫誌 2010;33:73-81)

**關鍵詞：**表皮下腫瘤，胃腸道基質瘤，內視鏡超音波

---

長庚醫療財團法人基隆長庚紀念醫院 肝膽胃腸科，病理科；長庚大學 醫學院

受文日期：民國97年8月4日；接受刊載：民國98年4月15日

通訊作者：簡榮南醫師，長庚醫療財團法人基隆長庚紀念醫院 肝膽胃腸科。基隆市204安樂區麥金路222號。

Tel.: (02)24313131轉3171; Fax: (02)24335342; E-mail: ronald@cgmh.org.tw