Sonographic Findings in Esophageal Achalasia

Seng-Kee Chuah, MD; Tsung-Hui Hu, MD, PhD; Keng-Liang Wu, MD; Wei-Chen Tai, MD; Tai-Yi Chen[1], MD; Yi-Chun Chiu, MD; Ming-Luen Hu, MD; Chi-Sin Changchien, MD; Chuan-Mo Lee, MD

Background: There are only three reports using conventional sonography to detect the gastroesophageal junction through the left lobe liver window in patients with achalasia, and the results were inconsistent. This study further characterizes the sonographic features of achalasia and compares them to characteristics of subjects with gastroesophageal malignancies.

Methods: Conventional sonography was performed in 21 patients with achalasia (mean age 49.0 years, 11 male and 10 female, group A); 15 patients with malignancies at the gastroesophageal junction (n = 10) and cardiac of the stomach (n = 5) (mean age 55.3 years, 11 male and 4 female, group B); and 30 subjects with functional dyspepsia (mean age: 38.3 years, 15 male and 15 female, control group C).

Results: The median esophageal wall thicknesses were 5.1 ± 2.3 mm (group A), 19.5 ± 7.8 mm (group B), and 3.3 ± 1.2 mm (group C). However, there was overlap in the esophageal wall thickness in groups A and C. Sonographic features in group A were regular hypoechoic thickening of the wall at the gastroesophageal junction; in group B, we found irregular hypoechoic thickening of the wall. Control subjects had a regular hypoechoic gastroesophageal wall. Dilated lumens of the distal esophagus were seen in all achalasia patients.

Conclusion: Although conventional sonography is not a diagnostic tool for achalasia, it provides interesting sonographic information. It cannot reveal each layer of the wall of the lumen as endoscopic ultrasound does, but it may tentatively differentiate achalasia from malignancies and assists clinicians when endoscopic ultrasound is not available.

(Chang Gung Med J 2009;32:204-11)

Key words: conventional sonography, gastroesophageal junction, achalasia

Conventional transabdominal sonographic detection of the esophagus and the upper portion of the stomach and their differentiation from the body surface are limited by the lungs, sternum, and gas in the fundus of the stomach. Gastroesophageal (GE) reflux disease, esophageal varices, and the cervical esophagus have been demonstrated by conventional sonography.[1-3] Despite the fact that endoscopic and

From the Division of Hepato-gastroenterology, Department of Internal Medicine; [1]Department of Radiology, Chang Gung Memorial Hospital-Kaohsiung Medical Center, Chang Gung University College of Medicine, Kaohsiung, Taiwan.
Received: May 28, 2008; Accepted: Nov. 18, 2008
Correspondence to: Dr. Chi-Sin Changchien, Division of Hepato-gastroenterology, Chang Gung Memorial Hospital. 123, Dapi Rd., Niaosong Township, Kaohsiung County 833, Taiwan (R.O.C.) Tel.: 886-7-7317123 ext. 8301; Fax: 886-7-7322402;
E-mail: chuahsk@seed.net.tw

intra-esophageal ultrasonography can accurately define each layer of the GE junction, it is still considered invasive and is not routinely used.[4,5] Achalasia is an esophageal motor disorder not easily diagnosed, especially in its early stages.[6-8] Even endoscopy may not reveal its existence unless it has progressed to a significant stage of the disease. In routine practice, manometry and barium esophagography are used to diagnose achalasia.[9-11] Endoscopic ultrasonography and computed tomography (CT) have been used to exclude pseudoachalasia caused by malignancy.[12,13]

A report of sonographic detection of the GE junction through the left lobe liver window recommended further studies for symptomatic subjects with a significant increase in the thickness of the wall at the GE lumen.[14] There are only two original articles,[15,16] and one case report,[17] challenging the role of conventional transabdominal sonography in esophageal achalasia, and the results were inconsistent. The purposes of this prospective, observational study were to further characterize the sonographic features of achalasia and to compare patients with achalasia to those with gastroesophageal malignancies.

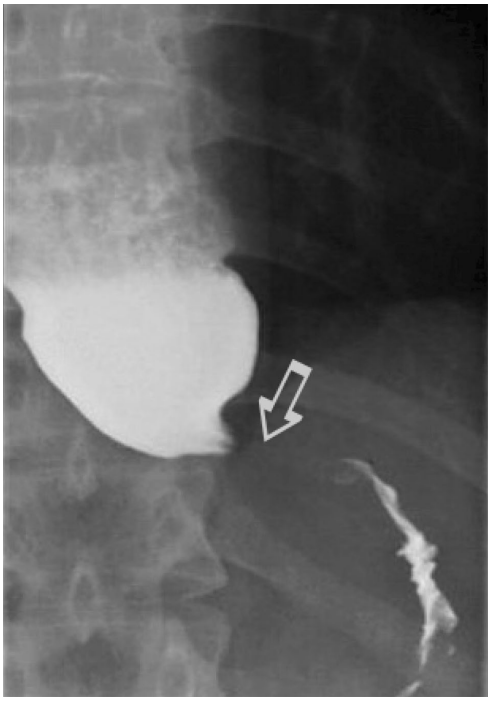

Fig. 1 Barium esophagography showing a typical narrowing of the lower esophagus with a bird-beak appearance (arrow) with some food retention in the dilated distal part of the lumen.

METHODS

All participants gave written informed consent. Conventional ultrasonic examinations were performed to measure the GE junction wall thickness, and to demonstrate the morphology and thoracic segment of the distal esophagus. Group A included 21 patients with a confirmed diagnosis of esophageal achalasia (mean age = 49.0 ± 20.7 years, 11 male and 10 female). All subjects in this group met the criteria of aperistalsis of the esophageal body and non-relaxation of the low esophageal sphincter (LES) during wet swallows in manometric studies. All barium esophagography studies demonstrated typical narrowing of the lower esophagus with a bird-beak appearance (Fig. 1). Pseudoachalasia was excluded using either one or a combination of studies such as endoscopic biopsy, endoscopic ultrasonography, and computed tomography. Group B consisted of fifteen patients (mean age 55.3 years, 11 male and 4 female) with malignancies of the lower esophagus that involved the GE junction (n = 10) and cardia of the stomach (n = 5). Ten of them had histologically confirmed squamous cell carcinoma and 5 had adenocarcinoma. Thirty subjects with functional dyspepsia (mean age: 38.3 years, 15 male s and 15 female) with negative findings on endoscopy and sonographic examinations constituted the control group, group C.

After overnight fasting and signing of informed consents, the subjects were examined in both the supine and right anterior oblique positions. We used ultrasound scanners (Toshiba SSA-340, Tokyo, Japan) with 3.75 MHz convex real-time and sector transducers (Toshiba) for these examinations. By moving the transducer over the xiphoid area of patients in the supine position during deep inspiration, the GE junction could be clearly seen. Applying the transducer sagittally and directing the sound beam cephalically through the window of the left lobe of the liver, a cross-section of the abdominal esophagus was seen as a ‘small kidney’ pattern in a healthy subject (Fig. 2).[3,14] When the transducer was slowly moved over the xiphoid area and the sound beam slightly swept from the xiphoid to the left side

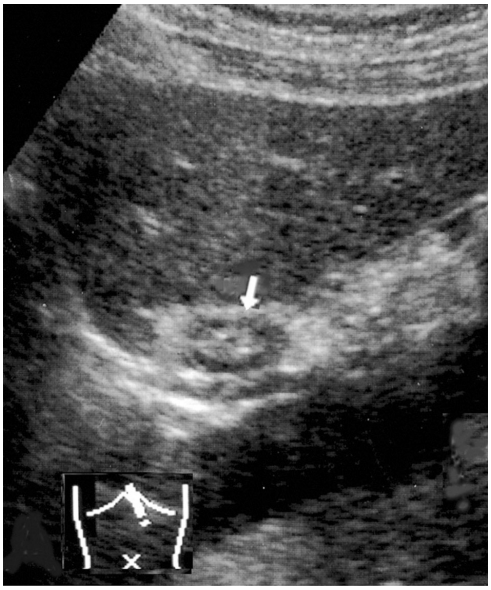

Fig. 2 Sonographic patterns of the GE junction. A cross-section of the abdominal esophagus is seen behind the left lobe of the liver as a "small kidney" pattern in a healthy subject.

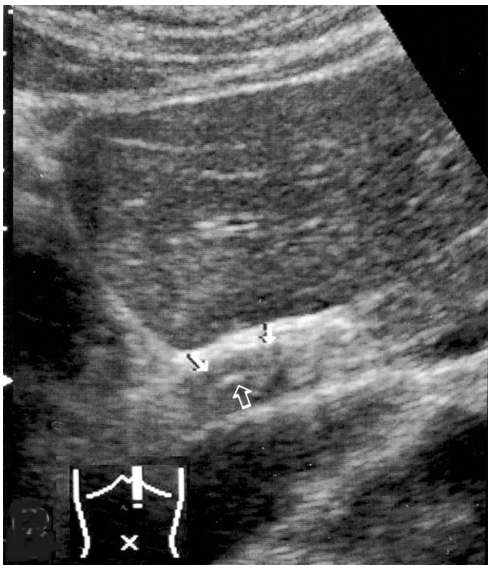

Fig. 3 Oblique or sagittal sections at the xiphoid area. The "small kidney" pattern becomes longer when the transducer is turned along the longitudinal axis of the GE junction, indicating that the outer hypoechoic rim of the "small kidney" pattern is the wall of the esophagus (muscular layers) (arrows) and the hyperechoic center is the mucosa and collapsed lumen.

of the subject, the sonographic pattern changed from a 'small kidney' pattern to an amorphous one (Fig. 3). This meant that the pattern changes from the abdominal esophagus to the gastric cardia. By aligning the transducer so that it moved along the longitudinal axis of the abdominal esophagus, the 'small kidney' pattern became longer (Fig. 3).

The thickness of the esophageal wall was defined as the total thickness of the hypoechoic layer. The measurement of esophageal wall thickness was made on a variety of slightly different cross sectional planes according to slight differences in the viewing angle and then zoomed in to measure from the 4 different quadrants of the 'small kidney'. The reported thickness was based on the median of the 4 measurements after the intra-observer coefficient of variance was attained. The appearance of hypoechoic thickness in cross sectional views was further described and classified as either regular, symmetrical thickening (Fig. 4) or irregular thickening (Fig. 5).

Also, an attempt was made to locate the distal esophagus of all subjects examined while in an erect position. For subjects with a dilated distal lumen, we aimed to demonstrate the peak narrowing with or without hypoechoic or hyperechoic retained sub-

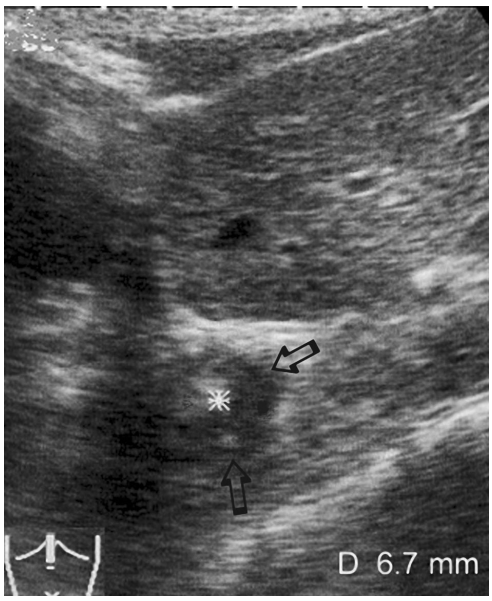

Fig. 4 The thickness of the esophageal wall is defined as the total thickness of the hypoechoic layer. This is regular, symmetrical GE wall thickening in a patient with achalasia (arrow).

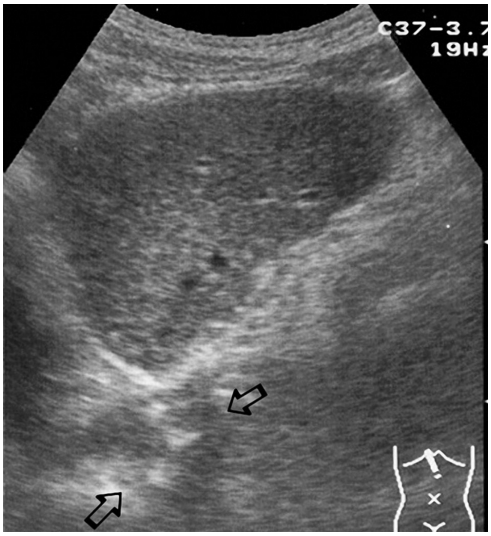

Fig. 5 Irregular, asymmetrical thickening of the GE wall (arrows) in a patient with malignancy.

stances indicating fluid or food material retention (Fig. 6). If the distal esophagus could not be demonstrated initially, we gave the subject 30 milliliters (ml) of water (providing the patient was able to drink) to record the dilated distal esophageal lumen (Fig. 7).

We used the ANOVA test followed by post-hoc comparisons in the statistical analysis for comparison of esophageal thicknesses among groups A, B, and C. A *p*-value less than 0.05 was considered significant.

RESULTS

Sonography findings in healthy subjects, and subjects with achalasia and malignancies are summarized in the Table 1. Measurements of the GE wall were attained successfully for all of our patients. The intra-observer coefficient of variance for GE wall thickness measurement was 5%. The mean body mass index (BMI) in the control group was 22.5 ± 0.6 (range: 21.6 to 23.7) in the 15 male and 19.5 ± 1.2 (range: 18.4 to 22.8) in the 15 female. The mean esophageal wall thickness was 3.3 ± 1.2 mm (range: 2.0 to 4.8 mm). The wall of the GE junction had a regular hypoechoic "small kidney" pattern (Fig. 2) in this group.

The mean BMI of the 21 patients in group A was 21.0 ± 1.9 (range: 19.0 to 25.3) in the 11 male

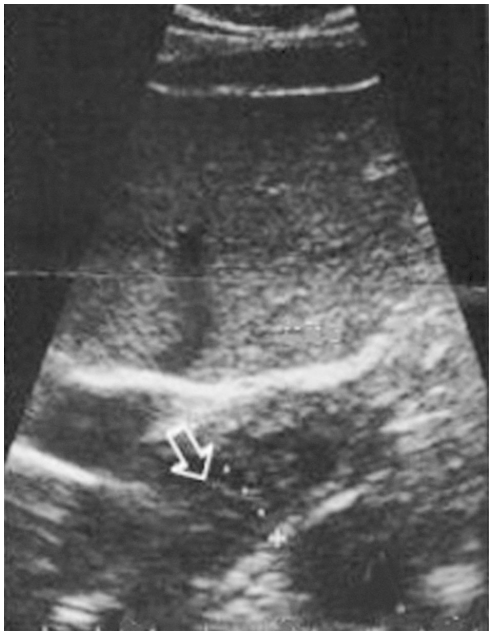

Fig. 6 Hypoechoic and hyperechoic retained substances indicating fluid or food material retention, respectively in the distal esophagus of a patient with achalasia (arrow).

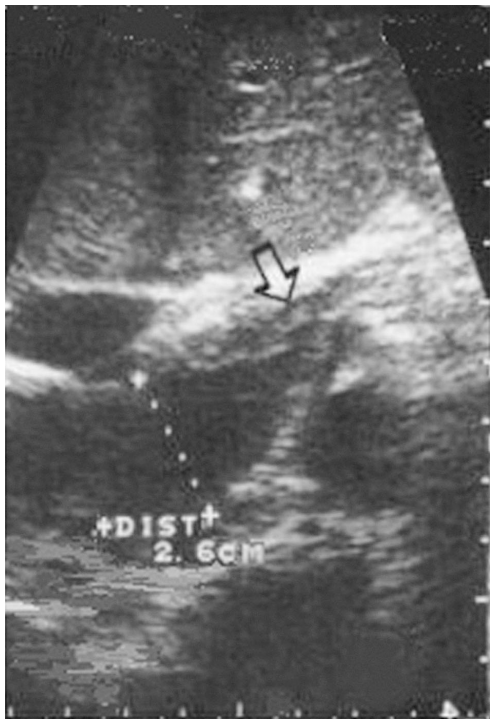

Fig. 7 A dilated distal esophageal lumen with a narrow bird-beak appearance (arrow) aided by water deglutition in a patient with achalasia.

Table 1. Sonography Characteristics of Subjects with Achalasia and Malignancies and Healthy Subjects

	Group A Achalasia (n = 21)	Group B Malignancy (n = 15)	Group C Healthy control (n = 30)
*Thickness of esophageal wall (mm)	5.1 ± 2.3	19.5 ± 7.8	3.3 ± 1.2
Range (mm)	(3.9 to 6.8)	(15.6 to 29.8)	(2.0 to 4.8)
Characteristics of GE Wall			
Non thickening	5/21	0/15	27/30
Regular thickening	16/21	0/15	3/30
Irregular thickening	0/21	15/15	0/30
Dilated distal esophagus			
Observed without water deglutination	14/21	0/9	0/30
Observed with water deglutination	7/21	2/9	0/30

*: ANOVA was used to compare esophageal thicknesses among groups A, B, and C, followed by post-hoc comparisons: Control versus group A, $p = 0.352$; control versus Group B, $p < 0.001$; group A versus group B, $p < 0.001$.

and 18.3 ± 1.2 (range: 16.4 to 20.1) in the 10 female. In the patients with achalasia, the wall of the GE junction appeared as a regular hypoechoic "small kidney" pattern (Fig. 4) but the mean thickness of the esophageal wall at the GE junction was 5.1 ± 2.3 mm (range: 3.9–6.8 mm). There was a statistically significant difference compared to the control group in the mean esophageal wall thickness ($p < 0.001$) but there was overlap between the two groups. The mean BMI of the 15 patients in group B was 16.4 ± 1.2 (range: 14.2 to 19.6) in the 10 male and 16.4 ± 0.5 (range: 16.0 to 17.1) in the 5 female. The median thickness of the esophageal wall at the GE junction was 24.9 mm (15.6-29.8 mm), ($p < 0.001$, compared to the control and the achalasia group). Imaging showed an irregular hypoechoic thickening pattern of the wall over the GE junction (Fig. 5).

In 14 of the 21 patients with achalasia, the distal end of the lower esophagus had hypoechoic or hyperechoic retained substances in the dilated lumen with peak narrowing (Figs 6, 7). Due to the limitations of the liver window, sonography was not able to show the thoracic segment fully in 7 patients with achalasia. Aided by water deglutition as tolerated by the subjects in an otherwise erect position, we managed to show the lower esophageal lumen and mild widening of the lumen with water retention in these patients.

DISCUSSION

The role of the most commonly used primary examinations for screening abdominal conditions, such as conventional sonography, may not be particularly useful in the diagnosis of patients with esophageal achalasia. However, based on our preliminary report, we believe that sonography might provide important information regarding tissue characteristics of the GE junction. Although it is well documented that endoscopic ultrasound can differentiate the different layers of the esophageal wall, it may not be available in most hospitals or clinics. Indeed, our results showed various interesting sonographic features of achalasia and their distinction from malignancies. Conventional sonography therefore may play a supporting role in these circumstances.

It may be difficult to compress the abdomen so that the sound beam is cephalically headed to the GE junction and the fat tissue behind the left lobe of the liver demonstrates a 'small kidney' pattern. Fortunately, none of our subjects in the achalasia group was obese and our study was technically successful in all of them. This could be explained by their relatively small BMI, which was caused by dysphagia. By means of water deglutition, the 'small kidney' pattern on ultrasonography could be identified as the esophagus; the peristalsis of the GE junction could also be seen by real time sonography.[14]

Sezgin et al[15] reported that conventional sonography clearly shows the regular thickening of the esophageal wall, water retention, dilatation of the distal esophagus, and a bird's beak appearance in patients with achalasia, but Eckardt's group[16] reported that the esophageal wall thickness is similar in both patients with achalasia and healthy controls. However, both groups agreed that sonography may help in differentiating achalasia from carcinoma of the GE junction, which is difficult to do with other modalities. Our results were similar to Sezgin and colleagues with a generally thicker GE wall in patients with achalasia than control subjects. This is

supported by two studies of Mittal and colleagues,[18,19] who used high-frequency intraluminal ultrasonography to confirm earlier observations in patients with spastic motor disorders and reported new findings of greater muscle thickness in patients with nonspecific motor disorders. Greater muscle thickness was associated with a greater prevalence of dysphagia, suggesting the possibility that symptoms may be related, at least in part, to alterations in the biomechanics of the esophagus.[18] Nonetheless, there was an apparent cross-over in the current study with respect to esophageal thickness in control subjects and patients with achalasia. The differentiation between normal and achalasia tissue by measurements of wall thickness using conventional sonography is therefore hampered in these situations.

Spence and Fitzgerald first published a case report on transabdominal ultrasound detection of achalasia showing a large residue in the distal oesophagus, which was seen to extend into the thorax.[17] In the current study, we clearly located the dilated lumen of the distal esophagus with peak narrowing in all of our patients with achalasia (erect position). This pattern was not seen in any control subject. We failed to show a lower esophageal lumen in 7 of the patients with achalasia before water deglutition. However, this problem was solved by repeating water deglutition (as tolerated by the patient). We gave 30 ml per trial while the patient was in an erect position and imaged the mildly dilated lower esophageal lumen with water retention.

Despite the discrepancies in the reports of GE wall thicknesses and the fact that it is hard to differentiate each layer of the wall as endoscopic ultrasound does, sonography still offers unique information. Other studies also reported that these findings are related to clinical conditions such as infiltrated malignancies, acute corrosive esophagitis, an edematous esophagus resulting from right side heart failure, esophageal ulcerations and esophagitis.[3,16] Similar to the results of Sezgin et al and Eckardt et al our results clearly showed that patients with malignancies and those with achalasia have different morphologic characteristics of the GE junction on conventional sonography, differences that may be difficult to identify using other modalities. We agree with Eckardt and colleagues that difficulties in making a definite diagnosis of neoplastic esophageal obstruction may be related to the fact that some of these tumours spread submucosally without infiltrating the mucosa of the distal esophagus and proximal stomach, and may also occur because of difficulties encountered in passing the endoscope through the obstructed GE junction.[16]

This study was limited by the subjective nature of the sonographic measurements and morphology exams, and the fact that the sonography was done only by the first author. An intra-observer agreement of the esophageal wall thickness was attained with an approximate coefficient of variance of 5%.

Although conventional sonography is not a diagnostic tool for achalasia, it offers interesting sonographic information. It cannot reveal each layer of the wall of the lumen as endoscopic ultrasound does but may tentatively differentiate achalasia from malignancies and assist clinicians when endoscopic ultrasound is not available.

REFERENCES

1. Saverymuttu SH, Wright J, Maxwell JD, Joseph AF. Ultrasound detection of esophageal varices -comparison with endoscopy. Clin Radiol 1988;39:513-5.
2. Wright LL, Baker KR, Meny RG. Ultrasound demonstration of gastroesophageal reflux. J Ultrasound Med 1988;7:471-5.
3. Gomes H, Lallemand A, Lallemand P. Ultrasound of the gastroesophageal junction. Pediatr Radiol 1993;23:94-9.
4. Nick NJ, Cotton PB. Clinical application of endoscopic ultrasonography. Am J Gastroenterol 1990;85:675-82.
5. Halvorsen RA. Imaging of the pharynx and esophagus. Curr Opin Radiol 1992;4:18-25.
6. Reynolds JC, Parkman HP. Achalasia. Gastroenterol Clin North Am 1989;18:223-55.
7. Chuah SK, Changchien CS, Hsu CC, Wu KL, Chou YP, Lu HI, Hsieh MJ. Current treatment options in esophageal achalasia. J Int Med Taiwan 2003;14:157-64.
8. Kim JH, Rhee PL, Lee SS, Lee H, Choi YS, Son HJ, Kim JJ, Rhee JC. Is aperistalsis with complete lower esophageal sphincter relaxation an early stage of classic achalasia? J Gastroenterol Hepatol 2007;22:536-41.
9. Gockell I, Eckardt VF, Junginger T. Pseudoachalasia: a case series and analysis of the literature. Scand J Gastroenterol 2005;40:378-85.
10. Chuah SK, Kuo CM, Wu KL Changchien CS, Hu TH, Wang CC, Chiu YC, Chou YP, Hsu PI, Chiu KW, Kuo CH, Chiou SS, Lee CM. Pseudoachalasia in a patient after truncal vagotomy surgery successfully treated by subsequent pneumatic dilations. World J Gastroenterol 2006;12:5087-90.
11. Chuah SK, Hu TH, Wu KL, Kuo CM, Fong TV, Lee CM, Changchien CS. Endoscope-guided pneumatic dilatation

of esophageal achalasia without fluoroscopy is another safe and effective treatment option: A report of Taiwan. Surg Laparosc Endosc Percutan Tech 2008;18:8-12.
12. Chuah SK, Changchien CS, Wu KL, Hu TH, Kuo CM, Chiu YC, Chiu KW, Kuo CH, Chiou SS, Lee CM. Esophageal motility differences among aged patients with achalasia: A Taiwan report. J Gastroenterol Hepatol 2007;22:1737-40.
13. Hashemi N, Banwait KS, DiMarino AJ, Cohen S. Manometric evaluation of achalasia in the elderly. Aliment Pharmacol Ther 2005;21:431-4.
14. Chanchien CS, Hsu CC. Use of sonography in the evaluation of the gastroesophageal junction. J Clin Ultrasound 1996;24:67-72.
15. Sezgin O, Ulker A, Temucin G. Sonographic findings in achalasia. J Clin Ultrasound 2001;29:31-40.
16. Eckardt VF, Schmitt T, Kanzler G. Transabdominal – ultrasonography in achalasia. Scand J Gastroenterol 2004;39:634-7.
17. Spence LD, Fitzgerald E. Case report: Transabdominal ultrasound detection of achalasia. Clin Radiol 1996;51:297-8.
18. Mittal RK, Kassab G, Puckett JL, Liu J. Hypertrophy of the muscularis propria of the lower esophageal sphincter and the body of the esophagus in patients with primary motility disorders of the esophagus. Am J Gastroenterol 2003;98:1705-12.
19. Mittal RK, Liu J, Puckett JL, Bhargava V, Tipnis N, Kassab G. Sensory and motor function of the esophagus: lessons from ultrasound imaging. Gastroenterology 2005;128:487-97.

下食道弛緩不能症病患之傳統超音波所見

蔡成枝 胡琮輝 吳耿良 戴維震 陳泰益[1] 邱逸群 胡銘倫 張簡吉幸 李全謨

背 景： 目前只有三篇文獻報告利用傳統超音波發現下食道弛緩不能症病患的胃食道交接處的一些特殊超音波影像，但三者所報告並不一致。本研究的目的乃是利用傳統超音波進一步探討下食道弛緩不能症患者之超音波影像，並和胃食道交接處的腫瘤比較。

方 法： 我們利用超音波針對下食道弛緩不能症的二十一位病患 (A 組)、胃食道交接處之腫瘤的十五位病患 (B 組)，和三十位健康對照組 (C 組) 來做研究。經由超音波下食道弛緩不能症測量胃食道交接處之管腔壁厚度，記錄其特徵並找出位於胸腔的下食道，進而了解不同組別的超音波特徵。

結 果： 各組的胃食道交接處之管腔壁平均厚度分別是下食道弛緩不能症組 5.1 ± 2.3 mm，腫瘤組 19.5 ± 7.8 mm 和健康對照組 3.3 ± 1.2 mm。下食道弛緩不能症組的胃食道交接處之管腔壁呈現勻稱低迴音的肥厚狀，健康對照組僅是勻稱低迴音的管腔壁而已。腫瘤組的管腔壁則是呈現不規則低迴音的異常肥厚。所有的下食道弛緩不能症患者擴張的下食道管腔皆可以在傳統超音波下呈現。

結 論： 傳統超音波無法作爲下食道弛緩不能症患者的主要診斷工具，但是我們可以發現它的一些特殊的超音波影像。傳統超音波也可以初步分辨出下食道弛緩不能症和腫瘤，即便它無法像內視鏡超音波一樣精確地分出管腔壁各個層次。然而對於沒有內視鏡超音波裝備的醫師有一定的助益。

(長庚醫誌 2009;32:204-11)

關鍵詞： 傳統超音波，胃食道交接處管腔壁的傳統超音波影像，下食道弛緩不能症

長庚紀念醫院 高雄院區 內科部 胃腸肝膽科系，[1]放射診斷科；長庚大學 醫學院
受文日期：民國97年5月28日；接受刊載：民國97年11月18日
通訊作者：張簡吉幸醫師，長庚紀念醫院 胃腸肝膽科系。高雄縣833鳥松鄉大埤路123號。Tel.: (07)7317123轉8301; Fax: (07)7322402; E-mail: chuahsk@seed.net.tw