A Successful Live Twin Birth by In Vitro Fertilization after Conservative Treatment of Recurrent Endometrial Cancer

Hsien-Ming Wu, MD; Chyong-Huey Lai, MD; Hong-Yuan Huang, MD; Hsin-Shih Wang, MD, PhD; Yung-Kuei Soong, MD

Endometrial cancer is predominately a postmenopausal disease. Endometrial cancer in women of childbearing age is relatively unusual. Endometrial cancer is typically treated with hysterectomy. After the development of endometrial cancer, successful pregnancy is rare. We present a case of recurrent stage I endometrial adenocarcinoma in a 35-year-old woman. Magnetic resonance imaging (MRI) revealed endometrial lesions without myometrium invasion and no pelvic lymph node enlargement. The patient refused surgical intervention with abdominal hysterectomy and bilateral salpingo-oophorectomy because of her essential desire for children. Fertility-preserving medical therapy with megestrol acetate for 1 year and subsequent assisted reproductive treatment (ART) were performed. Successful pregnancy occurred after in vitro fertilization-embryo transfer (IVF-ET). On the basis of these observations and the low malignant potential of well-differentiated endometrial carcinoma, fertility-preserving treatment using Megace therapy was suggested. In this case, recurrence occurred after the completion of Megace therapy and three failed attempts at artificial insemination by the husband (AIH). Recurrent endometrial adenocarcinoma was documented using hysteroscopy and direct endometrial biopsy. Another course of Megace therapy was administered due to her desire for children. A successful pregnancy occurred after long-term medical treatment and IVF-ET. *(Chang Gung Med J 2008;31:102-6)*

Key words: endometrial adenocarcinoma, recurrence, megestrol acetate, IVF, pregnancy

Endometrial cancer is predominately a postmenopausal disease with the average age at diagnosis of 58 years. The suggested treatment of stage I endometrial cancer consists of total abdominal hysterectomy and bilateral salpingo-oophorectomy. Only 2-5% of cases are diagnosed in women younger than 40 years of age. The clinical course of cancers in young women is often unfavorable, but this well known fact is not applicable to endometrial cancer in young women. Well differentiated endometrial adenocarcinoma has a favorable prognosis in women younger than 40 years, and shows a high sensitivity to progestins. Thus, patients who are affected during their reproductive years are deprived of their capability of childbearing. Although the long-term risks are not known and there is no standard regimen of medical management to allow subsequent pregnancy, it may be possible to reverse the lesions using progesterone therapy.[1,2] Early-stage endometrial cancer in association with risk factors like marked obesity and diabetes mellitus have an excessively unopposed estrogenic stimulation of the endometrium. Theoretically, progesterone should reverse the neoplastic process by removing or neu-

From the Department of Obstetrics and Gynecology, Chang Gung Memorial Hospital, Taipei, Chang Gung University College of Medicine, Taoyuan, Taiwan.
Received: Jul. 31, 2006; Accepted: May 16, 2007
Correspondence to: Dr. Yung-Kuei Soong, Department of Obstetrics and Gynecology, Chang Gung Memorial Hospital. No. 5, Fusing St., Gueishan Township, Taoyuan County 333, Taiwan (R.O.C.) Tel.: 886-3-3281200 ext. 3343; Fax: 886-3-3288252; E-mail: yks@cgmh.org.tw

tralizing the estrogenic effect.[3,4] Following regression of the lesions, patients are allowed to conceive and become pregnant. In young women wishing to bear children, however, trial treatment programs with progestins have recently been attempted, and successful pregnancies after the conservative treatment have been reported.[5,6] This is the first report of a patient with recurrent endometrial adenocarcinoma who received fertility-preserving treatment using megestrol acetate and had a successful pregnancy through in vitro fertilization-embryo transfer (IVF-ET).

CASE REPORT

The 35-year-old woman presented with a 6-year history of primary infertility. In the course of a workup panel concerning infertility, the patient underwent diagnostic laparoscopy and hysteroscopy that revealed normal pelvic organs and a 1×1 cm endometrial polyp. Transcervical resection of the endometrial polyp was performed and pathologic result revealed grade 1 endometrial adenocarcinoma. The curettage of the remainder of the endometrium was negative for carcinoma. Tumor markers were all within normal ranges. Duplex vaginal sonography showed normal adnexal and a minimal residual endometrial lesion short of Doppler flow signal without myometrial invasion. Magnetic resonance imaging (MRI) revealed an endometrial lesion without myometrium invasion and no pelvic lymph node enlargement (Fig. 1). The patient refused surgical intervention with abdominal hysterectomy and bilateral salpingo-oophorectomy because of her essential desire for children. Risks of recurrence even after fertility-preserving treatment were explained to the patient. After obtaining informed consent, medical therapy and subsequent assisted reproductive treatment (ART) were performed. The patient took 160 mg of megestrol acetate (Megace; Bristol-Myers, Evansville, IN) daily for a total of 6 months. In the mean time, hysteroscopy and endometrial curettage were performed once a month, and no further evidence of adenocarcinoma was detected. Thereafter, the patient received ovulation stimulation with human menopausal gonadotropin (hMG) and AIH for three cycles. Unfortunately, no pregnancy was achieved. Six months after stopping the megestrol acetate treatment, follow-up hysteroscopy revealed an obvious endometrial lesion (Fig. 2) and follow-up endometrial biopsy showed a recurrent grade 1 endometrial adenocarcinoma (Fig. 3). Due to her desire for children, another course of medical therapy with 160 mg of Megace daily for 6 months was started. During the period of medical treatment, follow-up hysteroscopy and endometrial curettage were done monthly with no further evidence of adenocarcinoma. Then, the patient was started on Gonadotropin-releasing hormone (GnRH) analog for

Fig. 1 Magnetic resonance imaging reveals endometrial lesion with intact junctional zone.

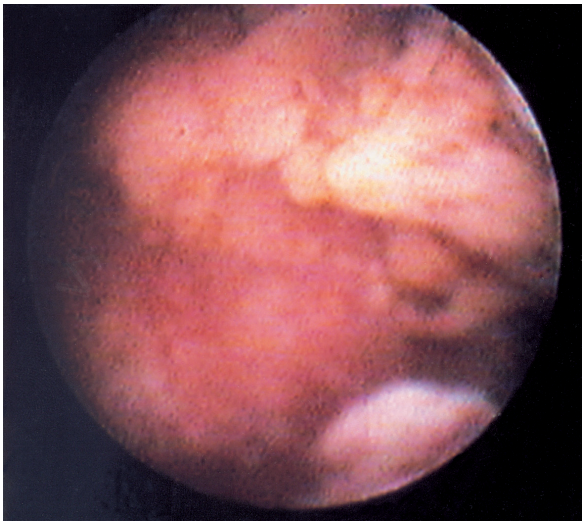

Fig. 2 Hysteroscopy demonstrates an endometrial lesion at the anterior-fundal area of the endometrium.

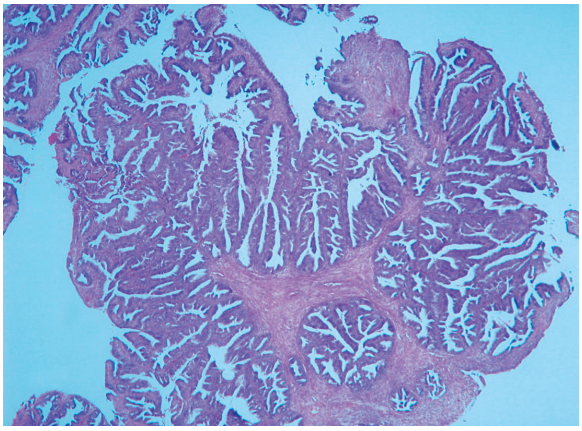

Fig. 3 This section of the endometrial biopsy shows endometrial fragments with well-differentiated adenocarcinoma (H & E stain).

pituitary down-regulation. After pituitary desensitization had been confirmed, ovarian hyperstimulation for IVF was performed using follicle-stimulating hormone (FSH) and human chorionic gonadotrophin (hCG) according to the long-protocol regimen. The IVF cycle was completed and embryos were transferred. The luteal phase was supplemented with hCG. Three weeks after the embryos were transferred, the β-hCG rose and ultrasound revealed a triplet pregnancy. One fetal demise was noted on follow-up sonography at 8 weeks of gestational age. The further course of the pregnancy was uncomplicated until 34 weeks of gestation when preterm labor occurred and tocolysis failed. The patient delivered two infants by cesarean section. Eight weeks after their delivery, follow-up endometrial curettage was done and revealed endometrial hyperplasia with atypical change. In order to prevent further malignant risk, abdominal hysterectomy and bilateral salpingo-oophorectomy was performed. Two years after surgery there is no evidence of recurrence.

DISCUSSION

Endometrial cancer is a disease that occurs primarily in postmenopausal women and is increasingly virulent with advancing age. Endometrial adenocarcinoma in young women is rare. The optimal therapy for patients with endometrial cancer, especially stage I, remains controversial. Historically, stage I endometrial cancer has been treated using intracavitary radiation followed by immediate hysterectomy and bilateral salpingo-oophorectomy in the United States. Numerous studies have documented the efficacy of using progestins in treating endometrial adenocarcinoma.[8] Successful pregnancies after hormone treatment and IVF program in stage I endometrial cancer have been reported.[5,7,9]

Table 1 describes the results of previous reports on successful births after endometrial cancer treated using Progestins. Various studies have been published. All of the studies used progestins as the initial treatment. In our report, we describe that the first case of recurrent endometrial adenocarcinoma received progestins as the initial treatment and subsequently had a successful pregnancy through IVF-ET.

In general, approximately 70% of recurrences occur within 3 years after the initial treatment. Local recurrences (pelvic wall, vagina, parametrium) are

Table 1. Review of the Reports on the Successful Births after Endometrial Cancer Treated Using Progestins

Reference	No. of cases	Mean age (years)	Mean duration of treatment (mo)	Mean follow-up of responders (mo)	Fertility outcome after treatment
Kempson[10]	2	27.5	2.5	Not available	Two live births
Eddy[11]	1	21	2	50	One live birth
Muechler[12]	1	28	6	54	One live birth
Lai[9]	1	31	6	30	One live birth
Randall[6]	12	30.5	9	35	Five live births and one early abortion
Vinker[17]	1	33	2.5	36	No pregnancy
Kimming[5]	1	28	2	22	One live birth
Lowe[1]	1	38	9	48	Two live births
Wang[14]	9	32	6	69	Two live births, two ectopic pregnancies and two early abortions

the most common in nonirradiated patients. In contrast, distant metastasis (lung, abdomen, liver, or bone) are the most frequent in patients who received radiation therapy with their primary therapy.[13]

In our case, recurrence occurred after the completion of Megace therapy and three times of failed AIH. Local and distant recurrences were ruled out after oncologic survey. In the study of fertility-preserving treatment in young patients with endometrial adenocarcinoma, four of eight responders later developed recurrence of the disease.[14] Recurrent endometrial adenocarcinoma was documented using hysteroscopy and direct endometrial biopsy. Therefore, hysteroscopy is relatively essential during the initial diagnosis and evaluation of endometrial neoplasia and early detection of tumor recurrence. Recurrence following conservative treatment using Megace for stage I well-differentiated endometrial adenocarcinoma was uncommon, especially when combined with ovulation induction for ART. Even though IVF requires controlled ovarian hyperstimulation with attendant high serum estradiol level, this exposure is believed to be of short duration and thus the additional risk to the patient of controlled ovarian hyperstimulation is small.[15,16] Another course of fertility-preserving Megace therapy was administered due to her desire for children. A successful pregnancy occurred after long-term medical treatment for recurrent low grade cancer and IVF-ET.

There is no convincing evidence that the so-called standard surgical treatment must be performed following delivery of babies in these women. However, our patient requested maximum safety after the completion of her reproductive ambition. Following initial success, various degrees of hyperplasia or reappearance of carcinoma have been observed during the follow-up period.[17,18] We are convinced that stage I well-differentiated adenocarcinoma of the endometrium may be treated conservatively with preservation of fertility in young women, including patients with recurrence of carcinoma observed during the follow-up period.

REFERENCES

1. Lowe MP, Bender D, Sood AK, Syrop CH, Sorosky JI. Two successful pregnancies after conservative treatment of endometrial cancer and assisted reproduction. Fertil Steril 2002;77:188-9.
2. Montz FJ, Bristow RE, Bovicelli A, Tomacruz R, Kurman RJ. Intrauterine progesterone treatment of early endometrial cancer. Am J Obstet Gynecol 2002;186:651-7.
3. Nieto JJ, Gornall R, Toms E, Hogston P, Woolas RP. Influence of omental biopsy on adjuvant treatment field in clinical stage I endometrial carcinoma. BJOG 2002;109:576-8.
4. Di Nezza LA, Jobling T, Salamonsen LA. Progestin suppresses matrix metalloproteinase production in endometrial cancer. Gynel Oncol 2003;89:325-33.
5. Kimmig R, Strowitzki T, Muller-Hocker J, Kurzl R, Hepp H. Conservative treatment of endometrial cancer permitting subsequent triplet pregnancy. Gynecol Oncol 1995;58:255-7.
6. Randall TC, Kurman RJ. Progestin treatment of atypical hyperplasia and well-differentiated carcinoma of the endometrium in women under age 40. Obstet Gynecol 1997;90:434-40.
7. Rackow BW, Arici A. Endometrial cancer and fertility. Curr Opin Obstet Gynecol 2006;18:245-52.
8. Vergote I, Kjorstad J, Abeler V. A randomized trial of adjuvant progestogen in early endometrial cancer. Cancer 1989;64:1011-6.
9. Lai CH, Hsueh S, Chao AS, Soong YK. Successful pregnancy after tamoxifen and megestrol acetate therapy for endometrial carcinoma. Br J Obstet Gynecol 1994;101:547-9.
10. Kempson RL, Pokorny GE. Adenocarcinoma of the endometrium in women aged forty and younger. Cancer 1968;21:650-62.
11. Eddy WA. Endometrial carcinoma in Stein-Leventhal syndrome treated with hydroxyprogesterone caproate. Am J Obstet Gynecol 1978;131:581-2.
12. Muechler EK, Bonfiglio T, Choate J, Huang KE. Pregnancy induced with menotropins in a woman with polycystic ovaries, endometrial hyperplasia, and adenocarcinoma. Fertil Steril 1986;46:973-95.
13. Aalders JG, Abeler V, Kolstad P. Recurrent adenocarcinoma of the endometrium: a clinical and histopathological study of 379 patients. Gynecol Oncol 1984;17:85-103.
14. Wang CB, Wang CJ, Huang HJ, Soong YK, Lai CH. Fertility-preserving treatment in young patients with endometrial adenocarcinoma. Cancer 2002;94:2192-8.
15. Salha O, Martin-Hirsch P, Lane G, Sharma V. Endometrial carcinoma in a young patient with polycystic ovarian syndrome: first suspected at time of embryo transfer. Hum Reprod 1997;12:959-62.
16. Yahata T, Fujita K, Aoki Y, Tanaka K. Long-term conservative therapy for endometrial adenocarcinoma in young women. Hum Reprod 2006;21:1070-5.
17. Vinker S, Shani A, Open M, Fenig E, Dgani R. Conservative treatment of adenocarcinoma of the endometrium in young patients. Is it appropriate? Eur J Obstet Gynecol Reprod Biol 1999;83:63-5.
18. Amant F, Moerman P, Neven P, Timmerman D, Vergote I. Endometrial cancer. Lancet 2005;366:491-505.

復發性子宮內膜癌經藥物保守性治療及試管嬰兒治療後成功雙胞胎懷孕

吳憲銘 賴瓊慧 黃泓淵 王馨世 宋永魁

子宮內膜癌主要發生於停經後婦女，子宮全切除手術是子宮內膜癌的標準治療方式。子宮內膜癌於生育年齡女性並不常見。一般來說，一旦罹患子宮內膜癌，能夠成功懷孕的機會並不大。子宮內膜癌的形成機轉和動情激素的過度刺激有關。所以理論上，對於早期發現的子宮內膜癌，可以使用黃體激素 (Megace) 去除或是降低動情激素對子宮內膜的刺激作用，而達到治療的效果。我們報告一位子宮內膜癌復發第一期的 35 歲病人，由於她本身是一位不孕症的病人，所以能保留住子宮及生育能力的保守性藥物治療，遂成爲治療的第一選擇。病人於接受黃體激素藥物治療後，進行試管嬰兒治療且成功懷孕產下雙胞胎。綜合以上所述，對於罹患早期子宮內膜癌的年輕婦女，且有意願生育的女性，使用黃體激素治療似乎是一項不錯的選擇。而在藥物治療後尚未懷孕以前，如果子宮內膜癌再度復發，子宮鏡檢查及追蹤，也扮演重要的角色。這個罕見的病例，經由子宮鏡檢查診斷出子宮內膜癌復發，立即進行第二次黃體激素藥物治療，控制子宮內膜癌復發，接著進行人工生殖試管嬰兒治療，最終成功雙胞胎懷孕生產。(長庚醫誌 2008;31:102-6)

關鍵詞：子宮內膜癌，復發，黃體激素，試管嬰兒，懷孕

長庚紀念醫院 台北院區 婦產部；長庚大學 醫學院
受文日期：民國95年7月31日；接受刊載：民國96年5月16日
通訊作者：宋永魁醫師，長庚紀念醫院 婦產部。桃園縣333龜山鄉復興街5號。Tel.: (03)3281200轉3343;
Fax: (03)3288252; E-mail: yks@cgmh.org.tw