

Schwannoma of the Penis: A Report of Two Cases

Chi-Ju Yeh, MD; Wen-Yu Chuang, MD; Shih-Tsung Huang¹, MD;
Shih-Ming Jung, MD

Schwannomas are benign nerve sheath tumors, which can occur sporadically or in patients with neurofibromatosis. Schwannomas of the penis are extremely rare. To our knowledge, only 18 cases of penile schwannomas have been reported previously in the English-language literature. Here we report two additional cases of penile schwannomas, including one case of multiple penile schwannomas. The first patient was a 26-year-old man presenting with a 2 x 2 cm, slowly growing, painless tumor on the dorsal penile shaft. The second patient was a 41-year-old man presenting with three painless nodules measuring up to 0.9 cm on the dorsal penile shaft. Neither patient had evidence of neurofibromatosis. Both patients received simple tumor excision, and neither experienced tumor recurrence. Penile schwannomas tend to occur on the dorsal penile shaft, the location of the penile dorsal nerves. Notably, multiple tumors are present in 30% of penile schwannoma cases, whereas most schwannomas at other locations present as a single tumor. Most penile schwannomas present as painless nodules. No reported patients had malignant transformation, but two had tumor recurrence 4 months and 7 years after excision. Despite its rarity, schwannomas should be included in the differential diagnoses of penile tumors. Simple excision with follow up should be the treatment of choice. (*Chang Gung Med J* 2007;30:555-9)

Key words: schwannoma, penis, shaft, S-100 protein, immunohistochemistry

Schwannomas (also known as neurilemmomas) are benign encapsulated nerve sheath tumors which can occur sporadically or in patients with neurofibromatosis. Despite the rich nerve supply in the penis, schwannomas of the penis are extremely rare. To our knowledge, only 18 cases of penile schwannomas have been reported in the English-language literature.⁽¹⁻¹⁴⁾ Herein, we report two more cases of penile schwannomas, including one case of multiple penile schwannomas, and review the literature.

CASE REPORTS

Case 1

A 26-year-old man presented with a painless

penile tumor, which had enlarged slowly during the last four years. Physical examination revealed a nontender, 2 x 2 cm nodule on the dorsal proximal aspect of the penile shaft. The overlying skin was smooth and intact. No evidence of neurofibromatosis was found.

Simple excision of the tumor was performed under local anesthesia. Grossly, the tumor was a well-defined, white, soft 1.8 x 1.5 x 1.3 cm nodule. Microscopically, it was a mixture of a cellular component (Antoni A areas) and a loose myxoid component (Antoni B areas) (Fig. 1). The Antoni A areas were composed of compact spindle cells arranged in fascicles or whorls with prominent nuclear palisading. The Antoni B areas contained loosely and hap-

From the Department of Pathology; ¹Department of Urology, Chang Gung Memorial Hospital, Taipei, Chang Gung University College of Medicine, Taoyuan, Taiwan.

Received: Dec. 7, 2006; Accepted: Mar. 5, 2007

Correspondence to: Dr. Shih-Ming Jung, MD, Department of Pathology, Chang Gung Memorial Hospital, 5, Fusing St., Gueishan Township, Taoyuan County 333, Taiwan (R.O.C.) Tel.: 886-3-3281200 ext. 2782; Fax: 886-3-3280147; E-mail: ming22@cgmh.org.tw

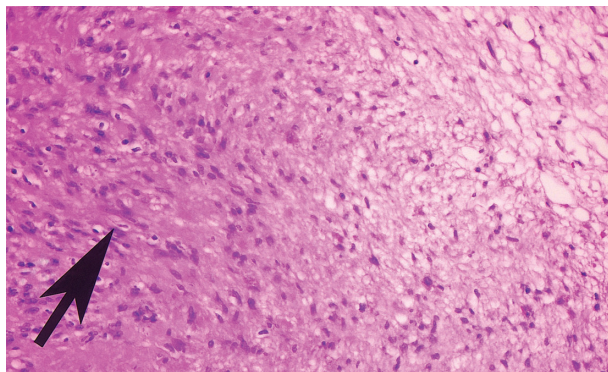


Fig. 1 A mixture of Antoni A areas (left) with nuclear palisading (arrow) and Antoni B areas (right) (hematoxylin and eosin stain, x 200).

hazardly arranged spindle cells in a myxoid stroma. The tumor cells had no prominent nuclear pleomorphism. No mitotic figures were found. Immunohistochemical study showed diffuse, strong positivity for S-100 protein (Fig. 2), which confirmed the diagnosis of a schwannoma. The patient had a smooth post-operative course, and no evidence of recurrence was noted after one year of follow up.

Case 2

A 41-year-old man presented with multiple painless penile tumors. Physical examination revealed three non-tender nodules on the dorsal aspect of the penile shaft. The overlying skin was smooth and intact. There was no evidence of neurofibromatosis.

Simple excision of the tumors was done under

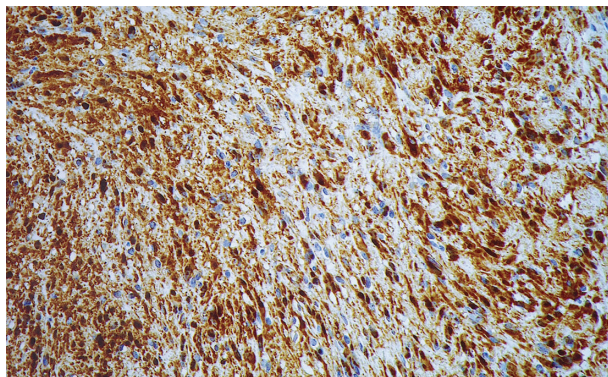


Fig. 2 Diffuse, strong positivity for S-100 protein (immunostain, x 200).

local anesthesia. Grossly, three white nodules measuring 0.5 x 0.4 x 0.4 cm to 0.9 x 0.7 x 0.5 cm were seen. Microscopically, they were composed of spindle cells with a mixture of Antoni A areas and Antoni B areas. Immunohistochemical study showed diffuse strong positivity for S-100 protein. The post-operative course was smooth, but the patient was lost to follow up after removal of the stitches.

DISCUSSION

Schwannomas are benign encapsulated nerve sheath tumors. Common locations of schwannomas include the head, neck, and flexor surfaces of the upper and lower extremities.⁽¹⁵⁾ They occur at all ages but most commonly in persons between 20 and 50 years old.⁽¹⁶⁾ In a population-based study of schwannomas, about 90% were sporadic, 3% occurred in patients with neurofibromatosis 2 (NF2), 2% in those with schwannomatosis, and 5% in association with multiple meningiomas in patients with or without NF2.⁽¹⁷⁾ Rarely, schwannomas occur as part of neurofibromatosis 1 (NF1).⁽¹⁸⁾ Because they grow slowly, schwannomas are usually present for years before diagnosis. Pain and neurological symptoms are uncommon unless the tumor becomes large.⁽¹⁹⁾

Histopathologically, the hallmark of a schwannoma is the biphasic pattern of Antoni A areas and Antoni B areas. Antoni A areas are composed of compact spindle cells with indistinct cytoplasmic borders arranged in short bundles or interlacing fascicles, with nuclear palisading being a common feature. Antoni B areas are characterized by loosely and haphazardly arranged spindle cells in a myxoid stroma. Some schwannomas have nuclear atypia due to degenerative changes, but mitotic figures are rare. Immunohistochemically, S-100 protein is strongly expressed by most tumor cells of schwannomas.⁽¹⁹⁾

Despite the rich innervation of the genital area, penile schwannomas are extremely rare. Dehner and Smith reported the first three cases of penile schwannomas in 1970.⁽¹⁾ To the best of our knowledge, only 18 cases of penile schwannomas have been reported in the English-language literature.⁽¹⁻¹⁴⁾ The clinical features of these 18 cases and our two cases are summarized in Table 1. The tumors were sporadic, since none of the patients had evidence of neurofibromatosis. The clear predilection of the tumor to occur on the dorsal penile shaft could be explained by the

Table 1. Clinical Features of the 20 Reported Penile Schwannomas (Including Present Cases) ⁽¹⁻¹⁴⁾

Age (years)	10 ~ 74 (median 32)		
Presentation	Painless nodule(s)	15 cases	(75%)
	Incidental finding	1 case	(5%)
	Occasional pain upon touch	1 case	(5%)
	Pain during ejaculation	1 case	(5%)
	Abnormal curvature during erection	1 case	(5%)
	Not available	1 case	(5%)
Duration of symptoms	4 months ~ 25 years (median 4 years)		
Site	Penile shaft	14 cases	(70%)
	Dorsum	8 cases	(40%)
	Base	1 case	(5%)
	(without mention of dorsum)		
	Details not available	5 cases	(25%)
	Glans penis	5 cases	(25%)
Number of tumor(s)	Prepuce	1 case	(5%)
	Single	14 cases	(70%)
	Multiple (3 ~ 5; median 3.5)	6 cases	(30%)
Largest tumor size	0.5 ~ 4.0 cm (median 1.6 cm)		
Recurrence	No	18 cases	(90%)
	Yes (4 months / 7 years after excision)	2 cases	(10%)

location of the penile dorsal nerves.⁽²⁰⁾ Notably, multiple tumors were present in 30% of the penile schwannoma cases, whereas most schwannomas at other locations present as a single tumor.⁽¹⁹⁾ Most penile schwannomas present as painless nodules, whereas two patients felt pain when the tumor was touched or during ejaculation.^(7,12) One patient presented with abnormal penile curvature during erection.⁽¹³⁾ Except for the rare cases with pain or abnormal curvature, none of the tumors interfered with sexual activity. Except for one patient who received a partial penectomy,⁽¹¹⁾ all patients underwent simple excision of the tumors. None of the tumors had malignant transformation, and only two patients experienced tumor recurrence 4 months and 7 years after excision.

Clinically, the differential diagnosis of penile schwannomas includes other soft tissue tumors of the penis, such as leiomyomas and neurofibromas, which are also very rare.⁽¹⁾ Malignant soft tissue tumors (sarcomas) are even rarer.⁽¹⁾ Only a few cases of penile schwannomas with imaging findings have

been reported.^(7,9,10,13) On ultrasonography, schwannomas are usually well-defined and hypoechoic on gray-scale ultrasonography and hypervascular on color Doppler ultrasonography.⁽¹³⁾ Magnetic resonance imaging has shown they have low to intermediate signal intensity on T1-weighted images and inhomogeneous high signal intensity on T2-weighted images.⁽¹³⁾ Computed tomography has revealed clear-margined, low density, and homogeneously enhanced masses.⁽⁷⁾ However, these imaging findings are non-specific and a definitive diagnosis can only be made after pathological examination of the excised tumors. Although the presence of circumscription favors a diagnosis of a benign tumor, an excisional biopsy is required to exclude the possibility of malignancy.

In conclusion, despite its extreme rarity, a schwannoma should be included in the differential diagnoses of a penile tumor. Similar to schwannomas at other sites, penile schwannomas are mostly sporadic tumors occurring in patients without neurofibromatosis. The dorsal penile shaft is the most common location. Unlike schwannomas at other locations, which most present as a single tumor, up to 30% of penile schwannomas occur as multiple tumors. Because of the encapsulation of schwannomas, simple excision with careful dissection to preserve the nerve should be the treatment of choice. Post-operative follow up is recommended due to a low incidence of recurrence.

REFERENCES

1. Dehner LP, Smith BH. Soft tissue tumors of the penis. A clinicopathologic study of 46 cases. *Cancer* 1970;25:1431-47.
2. Marsidi PJ, Winter CC. Schwannoma of penis. *Urology* 1980;16:303-4.
3. Chan WP, Chiang SS, Huang AH, Lin CN. Penile frenulum neurilemoma: a rare and unusual genitourinary tract tumor. *J Urol* 1990;144:136-7.
4. Kubota Y, Nakada T, Yaguchi H, Abe Y, Sasagawa I. Schwannoma of the penis. *Urol Int* 1993;51:111-3.
5. Mayersak JS, Viviano CJ, Babiarez JW. Schwannoma of the penis. *J Urol* 1995;153:1931-2.
6. Hamilton DL, Dare AJ, Chilton CP. Multiple neurilemmomas of the penis. *Br J Urol* 1996;78:468-9.
7. Suzuki Y, Ishigooka M, Tomaru M, Abe Y, Kubota Y, Nakada T. Schwannoma of the penis: report of a case and review of the literature. *Int Urol Nephrol* 1998;30:197-202.
8. Ghaly AF, Orange GV. Not every penile lump is a wart!

- Schwannoma of the penis. *Int J STD AIDS* 2000;11:199-200.
9. Pandit SK, Rattan KN, Gupta U, Budhiraja S, Singh Y, Sen J, Sen R. Multiple neurilemmomas of the penis. *Pediatr Surg Int* 2000;16:457.
 10. Sato D, Kase T, Tajima M, Sawamura Y, Matsushima M, Wakayama M, Kuwajima A. Penile schwannoma. *Int J Urol* 2001;8:87-9.
 11. Jiang R, Chen JH, Chen M, Li QM. Male genital schwannoma, review of 5 cases. *Asian J Androl* 2003;5:251-4.
 12. Algaba F, Chivite A, Rodriguez-Villalba R, Sarquella J, Martinez-Montelongo R, Ruiz-Castane E. Schwannoma of the penis: a report of 2 cases. *J Androl* 2003;24:651-2.
 13. Jung DC, Hwang SI, Jung SI, Kim SH, Kim SH. Neurilemmoma of the glans penis: ultrasonography and magnetic resonance imaging findings. *J Comput Assist Tomogr* 2006;30:68-9.
 14. Kumar GP, Sukumar S, Bhat SH, Nambiar A. Schwannoma of the penis: a common tumour at a rare site. *Scand J Urol Nephrol* 2006;40:166-7.
 15. Stout AP. The peripheral manifestations of the specific nerve sheath tumor (neurilemoma). *Am J Cancer* 1935;24:751-96.
 16. Geschickter CF. Tumors of the peripheral nerves. *Am J Cancer* 1935;25:377-410.
 17. Antinheimo J, Sankila R, Carpen O, Pukkala E, Sainio M, Jaaskelainen J. Population-based analysis of sporadic and type 2 neurofibromatosis-associated meningiomas and schwannomas. *Neurology* 2000;54:71-6.
 18. Izumi AK, Rosato FE, Wood MG. Von Recklinghausen's disease associated with multiple neurolemomas. *Arch Dermatol* 1971;104:172-6.
 19. Weiss SW, Goldblum JR. Benign tumors of peripheral nerves. In: Weiss SW, Goldblum JR, eds. *Enzinger and Weiss's Soft Tissue Tumors*. 4th ed. St. Louis: Mosby, 2001:1146-73.
 20. Yang CC, Bradley WE. Neuroanatomy of the penile portion of the human dorsal nerve of the penis. *Br J Urol* 1998;82:109-13.

陰莖許旺氏瘤：兩病例報告及文獻回顧

葉琦如 莊文郁 黃世聰¹ 容世明

許旺氏瘤是一種良性的神經鞘瘤，可為散發性或發生於多發性神經纖維瘤患者。發生在陰莖的許旺氏瘤極為罕見，目前為止，在英語文獻中僅報告過 18 例。我們在此報告兩例發生在陰莖的許旺氏瘤，包含一例多發性陰莖許旺氏瘤。第一例是一位 26 歲男性，他在陰莖幹部背側發現一個 2 公分大、緩慢生長，且無痛之腫瘤。第二例是一位 41 歲男性，他在陰莖幹部背側發現三個最大達 0.9 公分的無痛腫瘤。這兩人皆無多發性神經纖維瘤病史。兩人皆接受單純性腫瘤切除，且術後皆無復發。回顧文獻，陰莖許旺氏瘤好發於陰莖的幹部背側，而此處恰為陰莖背側神經所在。報告過之病例皆無多發性神經纖維瘤病史。特別的是，多發性陰莖許旺氏瘤出現在高達 30% 的陰莖許旺氏瘤患者，這與其他部位的許旺氏瘤絕大多數皆為單一腫瘤顯著不同。絕大多數的陰莖許旺氏瘤以無痛結節做為臨床表現。所有報告過的病例皆無惡性變化，但其中兩例分別在術後 4 個月及 7 年出現腫瘤再發。儘管相當罕見，許旺氏瘤仍應列入陰莖腫瘤的鑑別診斷之中。單純性切除加上術後追蹤應為首選治療。(長庚醫誌 2007;30:555-9)

關鍵詞：許旺氏瘤，陰莖，幹部，S-100 蛋白質，免疫組織化學

長庚紀念醫院 台北院區 解剖病理科，¹泌尿科；長庚大學 醫學院

受文日期：民國95年12月7日；接受刊載：民國96年3月5日

通訊作者：容世明醫師，長庚紀念醫院 解剖病理科。桃園縣333龜山鄉復興街5號。Tel.: (03)3281200轉2782;

Fax: (03)3280147; E-mail: ming22@cgmh.org.tw