

Acute Reversible Orthostatic Hypotension in A Young Woman with Systemic Lupus Erythematosus

Chung-Han Yang¹, MD; Shih-Ching Lee^{1,2}, MD; and Lieh-Bang Liou¹, MD, PhD

This paper reports the first definite case of systemic lupus erythematosus (SLE) with acute symptomatic orthostatic hypotension in a young woman. She was admitted for a flare-up of lupus. Serial examination revealed hypokalemic distal (type I) renal tubular acidosis. The treatment was complicated by acute symptomatic orthostatic hypotension, which did not improve following the correction of the patient's metabolic acidosis and hypokalemia. Magnetic resonance imaging provided no specific findings. However, magnetic resonance spectroscopy of the brain revealed a decrease in the N-acetylaspartate/Creatine (NAA/Cr) ratio of putamen. Finally, the patient's orthostatic hypotension recovered after corticosteroid treatment. Therefore, the authors suggest that, excluding the hypokalemia, metabolic acidosis, and peripheral causes of orthostatic hypotension, causes involving the central nervous system should be considered in patients with SLE. (*Chang Gung Med J* 2006;29(4 Suppl):97-102)

Key words: orthostatic hypotension, magnetic resonance spectroscopy, renal tubular acidosis, systemic lupus erythematosus.

Orthostatic hypotension is defined as the reduction in systolic blood pressure by at least 20 mmHg or in diastolic blood pressure by at least 10 mmHg within three minutes of standing in an upright posture.⁽¹⁾ It is not a disease but a combination of various medical conditions, including intravascular volume depletion, cardiovascular and endocrine-metabolic diseases and some neurological disorders associated with autonomic dysfunction. Hoyle first reported acute autonomic neuropathy in a patient with systemic lupus erythematosus (SLE).⁽²⁾ Much more attention has been paid to the autonomic function of this patient group in the last 15 years.⁽³⁻⁶⁾ Although the exact mechanism of autonomic dysfunction remains unclear, the prevalence of abnormal test results of cardiovascular autonomic function is high, ranging from 40 to 90%.⁽³⁻⁶⁾ However, the prevalence of symptoms related to such results is

low. This discrepancy probably follows from heterogeneity in the studied patient population and the criteria for a positive test result. Reports on acute reversible cases are very rare. A case of SLE presented with acute onset of orthostatic hypotension and mild cognitive dysfunction, which was reversed by corticosteroids, is reported here. Magnetic resonance imaging/magnetic resonance spectroscopy (MRI/MRS) of the patient's brain is also reported.

CASE REPORT

A 29-year-old female was admitted to our hospital on July 18, 2002 for intermittent fever. SLE according to the ACR 1997 revised criteria, was diagnosed five years earlier. And Nephrocalcinosis with renal tubular acidosis was detected two years prior admission to Chung Gung Hospital.

From the ¹Division of Rheumatology, Allergy and Immunology, Department of Internal Medicine, Chang Gung Memorial Hospital, Taipei; ²Department of Internal Medicine, St. Paul Memorial Hospital, Taoyuan.

Received: Mar. 21, 2005; Accepted: Sep. 5, 2005

Correspondence to: Dr. Lieh-bang Liou, Division of Rheumatology, Allergy and Immunology, Department of Internal Medicine, Chang Gung Memorial Hospital, 5, Fushing Street, Gueishan Shiang, Taoyuan, Taiwan 333, R.O.C. Tel.: 886-3-3281200 ext 8810; Fax: 886-3-3281200 ext 8813; E-mail: b890121@adm.cgmh.org.tw

Prednisolone (5 mg/day), bicarbonate, and potassium chloride were prescribed irregularly and the patient appeared to be well without further discomfort.

The patient had suffered an acute onset of intermittent fever with chills three weeks prior to admission. A tongue ulcer was noted without any other discomfort related to diseases of lupus. The serum titer of anti-nuclear antibody (ANA) was high (1:640, homogeneous pattern and 1:1280, speckled pattern) with decreased serum complement levels. Before presenting herself at our emergency department on July 16 she complained of a persistent fever and felt dizzy at rest and more severely so while changing position. She also complained of forgetfulness and difficulty in thinking. Blood culture results, on file from a previous hospital treatment prior to admission, were negative. Urine protein was positive at that time.

On physical examination at our hospital, body temperature was 40°C, her heart rate was 150/min, and her blood pressure (BP) was 86/56 mm Hg. She was clear-minded and oriented with mild hair loss. A painful ulcer was noted on the left lateral aspect of her tongue. Her right knee was slightly swelled with localized heat and redness. Neurological and cognitive function evaluations showed a decreased capacity for immediate memory without focal neurological signs. Laboratory evaluation revealed mild anemia (hemoglobin 11.1 mg/dL) and the patient's leukocyte count was 4500/mm³ with myelocyte 1%, band 1%, segment 84%, lymphocyte 10%, atypical lymphocyte 3% and monocyte 1%. Her platelet count, activated partial thromboplastin time, renal and liver functions were normal. Her urine protein was 1.27 g/day. Her C3 was 35.90 mg/dL (73-134) and C4 was < 5.13 mg/dL (18.2-45.5). Her anti-cardiolipin antibodies were negative for both IgG and IgM class. IgM for HSV and CMV were positive, but EB-VCA IgM was negative. Her CRP was < 5 mg/L (< 3.20). Renal echography and KUB revealed nephrocalcinosis. Follow-up biochemistry showed normal anion gap metabolic acidosis (anion gap [AG] 8.2) and mild hypokalemia (3.0 mEq/L [3.0-4.8]). Her urine AG was positive (13 mEq/L), and her urine osmotic gap was -9.82 mOsm/L. A sodium bicarbonate loading test was conducted and the fraction excretion of bicarbonate was 1.93%. These results supported the diagnosis of hypokalemic distal type (type I) renal tubular acidosis with low net distal H⁺ secretion. H⁺-

ATPase pump defects of collecting tubules were diagnosed by low urine pCO₂ (< 50 mmHg) and high urine pH (> 6.0).

Cefazolin and gentamicin were given for any bacterial infection after admission. No growth was observed on blood cultures and the patient's urine culture count was less than 1000 colonies. Antibiotics were discontinued after seven days. Hydrocortisone, 200 mg/day, was given parenterally from July 17. The fever subsided one day after the patient began the course of steroids. The steroid was tapered to 20 mg/day of prednisolone five days after admission. Hydroxychloroquine, 200 mg/qd, was also prescribed. The patient's condition improved greatly and she was prepared for discharge.

However, a sudden onset of dizziness on getting up from the bed with generalized weakness occurred on the morning of July 26. It was followed by chills and a fever (39°C). The patient's temperature dropped to 37.2°C in the evening of the same day. Her heart rate was 109/min; her BP was 80/53 mmHg. She looked tired, in acute distress and in a euvolemic state. She was neither pale nor icteric. Her pupils were oval and symmetrically responsive to light. Malar rash was present on her face. Multiple painful shallow ulcers and oral thrush were on her tongue. Her neck was supple and no lymphadenopathy was detected. Neither tenderness nor swelling of her joints was observed. Her leukocyte count became 15,700/mm³ with band 3%, segment 93.5%, lymphocyte 0% and monocyte 3.5%. Her biochemical data were normal.

Prednisolone was continued at 20 mg/day. Cefazolin and gentamicin were administered again to treat possible nosocomial infection. Drug eruption was noted on the third day, so the antibiotics were changed to oral Ciprofloxacin 250 mg q12h, which was discontinued four days later when all blood cultures were negative. Intravenous fluid was supplied during these days (normal saline 2 liters with 40 mEq KCl per day). The patient had low BP during this period with persistent severe dizziness (lasting for more than one hour) after changing position, despite parenteral fluid and potassium supply. Table 1 lists her BP and pulse rate associated with orthostatic changes, according to the method of Ewing.⁽⁷⁾ Systolic BP fell significantly on August 1st but differed only a little on August 13. Bicarbonate, 21.7 mEq/day, and potassium chloride, 75 mEq/day, were

Table 1. Changes of Blood Pressure and Pulse Rate on Standing

	SBP (mmHg)	DBP (mmHg)	PR (rates per minute)
Aug 01	-18	-10	+20
Aug 08	-10	-2	+6
Aug 13	-3	+6	-6

***Abbreviations:** SBP: systolic blood pressure; DBP: diastolic blood pressure; and PR: pulse rate.

prescribed for her renal tubular acidosis. The dizziness did not improve two days following supplement and so the prednisolone dose was increased to 45 mg/day from August 7.

Her symptoms of forgetfulness and difficulty in thinking persisted during this period, hypothalamus and brain stem lesions were then suspected; these would interfere with the autonomic regulation and thus cause dizziness and orthostatic hypotension. MRI/MRS were conducted on August 10 after the prednisolone dose was increased. No gross anatomic abnormality was found but the patient's N-acetylaspartate/Creatine (NAA/Cr) ratio of putamen was low

(Fig. 1). Minimal dizziness occurred when standing for more than 30 minutes five days following the increase in the prednisolone dose. The patient was discharged in a stable condition and followed up regularly at our outpatient department. No significant orthostatic change in blood pressure was observed on December 12 at the outpatient clinic.

DISCUSSION

In short, our patient was admitted for a flare of lupus with fever, forgetfulness, dizziness aggravated by postural change and hypotension. Hydrocortisone 200 mg/day was given after admission. Her symptoms improved, steroid treatment was tapered to prednisolone 20 mg/day on July 22. Four days later, her fever flared with malar rash, and hypotension. She did not have volume depletion or sources of infection. Her dizziness persisted despite supportive care. The dose of prednisolone was increased to 45 mg/day on August 7, and she recovered from dizziness. The patient was discharged on August 14.

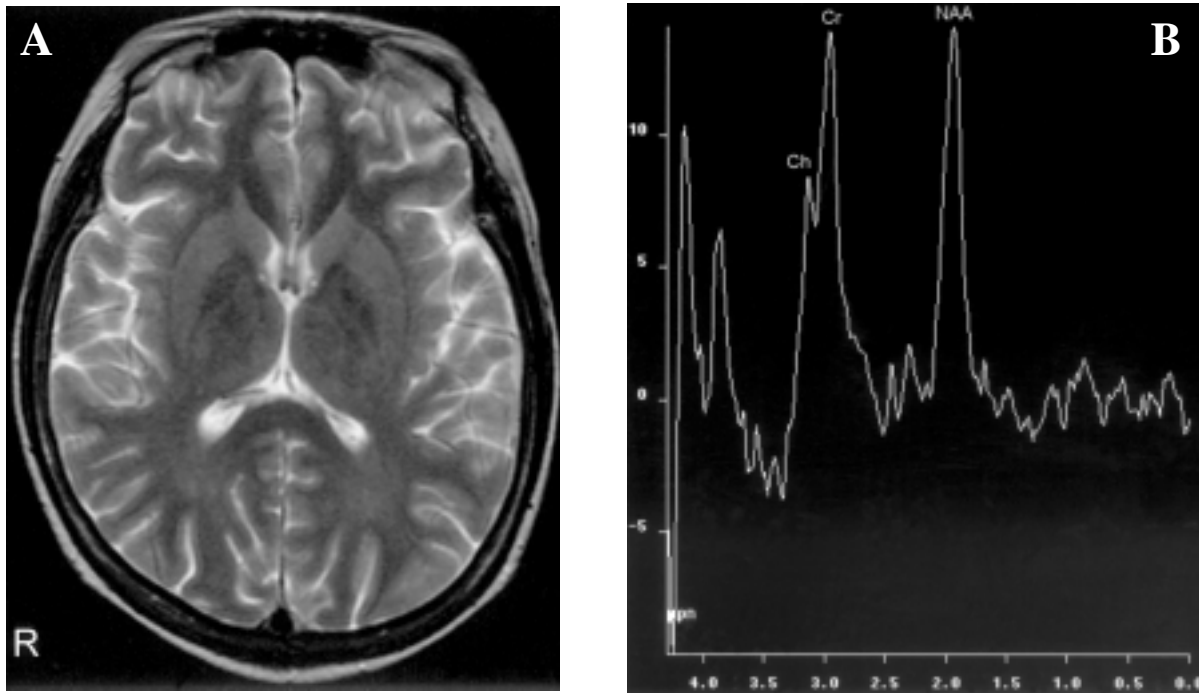


Fig. 1 Magnetic resonance image (A) and magnetic resonance spectroscopy (B) of the patient. (A) No specific abnormal findings in the T2 weighted image. (B) Decreased NAA/Cr ratio in right putamen ($48.73/45.45 = 1.07$) and in left putamen ($29.58/36.43 = 0.81$, not shown here). Normal range of NAA/Cr ratio in putamen is around 1.5-2.0. NAA: N-acetylaspartate; Cr: creatine; Ch: choline.

Prednisolone was tapered to 30 mg/day on August 23. She has not had orthostatic hypotension since then.

An acute autonomic disorder is characterized by severe sympathetic and parasympathetic impairment with preservation of somatic motor and sensory function. In the case reported here, the patient only had orthostatic hypotension without other autonomic involvement, such as pupillary, sweating, urinary and gastrointestinal symptoms. The most common cause of orthostatic hypotension is dehydration, medication, hypokalemia, anemia and other underlying systemic disease like diabetes mellitus, alcoholism and uremia. Our patient had long-standing type I RTA with obvious nephrocalcinosis. She did not take any medication causing her symptoms and her hemoglobin was 11 g/dL for a long period. Her serum potassium was near the lower limit of the reference range (3.0 mEq/L) when the symptoms began. However, the severity of the dizziness did not improve after parenteral fluid and potassium supply. Thus, hypokalemia was not the cause of orthostatic hypotension.

The initial low blood pressure (86/56 mmHg) may be attributed to the recent herpes simplex virus (HSV), cytomegalovirus (CMV) infection and a flare-up of SLE. Her blood pressure became stable and her fever subsided after supportive care and parenteral hydrocortisone. Although HSV infection is associated with acute autonomic neuropathy with orthostatic hypotension and transient peripheral somatic neuropathy in a 13-year-old girl,⁽⁸⁾ no symptoms were present in this case to suggest peripheral neuropathy and active HSV infection was not supported by the clinical course.

Blood pressure during postural change was regulated mainly by the sympathetic system and the vasomotor center in the brain stem. The heart rate response in our patient to standing up was preserved, possibly indicating a normal parasympathetic response. However, the patient's arterial pressure and heart rate response to the Valsalva maneuver, diastolic pressure during handgrip and detailed heart rate response to standing in a 30:15 ratio were not evaluated, making comparison between the sympathetic and parasympathetic systems difficult.

Generally, definite brain lesions revealed by MRI are unrelated to autonomic disorders, except for such lesions of multiple system atrophy (MSA) and

Parkinsonism, although the regulatory center of the sympathetic system is known to be located in the hypothalamus with a pathway toward the medulla. Forgetfulness and difficulty in thinking, which are common symptoms of neuropsychiatric involvement, combined with orthostatic hypotension in our patient may indicate a high probability of lesions in the central nervous system. The MRI was normal in our patient and the only finding was a decrease NAA/Cr ratio in putamen as revealed by MRS. No evidence of MSA was revealed by MRI, and a lack of rigidity or clinical movement disorder excluded the possibility of MSA or Parkinsonism. The changes in MRS may indicate neuron loss in putamen, and were perhaps evidence of neuropsychiatric SLE, which may have yielded the non-specific changes in image studies.⁽⁹⁾ A significant decrease in NAA/Cr ratio in frontal and parieto-occipital white matter is noted in cases with SLE compared to a healthy control.⁽¹⁰⁾ Furthermore, the decrease of NAA/Cr ratio in the basal ganglia correlated with the severity of the neuropsychiatric symptoms.⁽¹¹⁾ In addition, earlier or subtler neuron damage may occur in the sympathetic integrating center, but may not be evident in current image modalities. Also, the findings of the MRS in this patient may be secondary to persistent (orthostatic) hypotension in this watershed region, including for example, the hippocampus, basal ganglia (putamen), thalamus and hypothalamus.⁽¹²⁾

The exact mechanism of the autonomic dysfunction in SLE was unclear. However, an immunological mechanism may be responsible. Autoantibodies to autonomic nervous structures have been found earlier.⁽⁶⁾ Thrombosis, or vasculitis may also participate. No significant association has been found between anti-cardiolipin antibodies and autonomic neuropathy, although a large proportion of patients have suffered an increased level of anti-cardiolipin antibodies.⁽³⁾ Furthermore, central pathways of the autonomic system have been speculated to be involved in acute autonomic disorders.^(2,4) In particular, our patient's dizziness and orthostatic hypotension improved after the dose of prednisolone was increased. Other than anti-inflammatory effect, prednisolone also has some mineralocorticoid effect. However, mineralocorticoid effect could not fully explain why it took four days to make the symptoms of lupus and orthostatic hypotension still occurring but rapidly improving to a dosage increase in only

one day, and did not recur after prednisolone was decreased to 30 mg/day. The anti-inflammatory effect, other than mineralocorticoid effect, of glucocorticoid may play an important role. Hence, possible vasculitis could not be ruled out, and immune-complex deposition may be another possibility.⁽⁹⁾

In summary, a lupus patient with acute orthostatic hypotension and a decrease NAA/Cr ratio revealed by the MRS is reported here. Whether this is a primary or secondary phenomenon remains to be determined. Nevertheless, this is the first case report of acute reversible hypotension in a patient with established systemic lupus, and thus differs from the report in which the ACR criteria of SLE were not met.⁽²⁾ This case suggests that acute orthostatic hypotension may be a novel manifestation of neuropsychiatric lupus.

REFERENCES

1. The Consensus Committee of the American Autonomic Society and the American Academy of Neurology. Consensus statement on the definition of orthostatic hypotension, pure autonomic failure, and multiple system atrophy. *Neurology* 1996;46:1470.
2. Hoyle C, Ewing DJ, Parker AC. Acute autonomic neuropathy in association with systemic lupus erythematosus. *Ann Rheum Dis* 1985;44:420-4.
3. Gamez-Nava JI, Gonzalez-Lopez L, Ramos-Remus C, Fonseca-Gomez MM, Cardona-Munoz EG, Suarez-Almazor ME. Autonomic dysfunction in patients with systemic lupus erythematosus. *J Rheumatol* 1998;25:1092-6.
4. Magaro M, Mirone L, Altomonte L, Zoli A, Angelosante S. Lack of correlation between anticardiolipin antibodies and peripheral autonomic nerve involvement in systemic lupus erythematosus. *Clin Rheumatol* 1992;11:231-4.
5. Gledhill RF, Dessein PH. Autonomic neuropathy in systemic lupus erythematosus. *J Neurol Neurosurg Psychiatry* 1988;51:1238-40.
6. Maule S, Quadri R, Mirante D, Pellerito RA, Marucco E, Marinone C, Vergani D, Chiandussi L, Zanone MM. Autonomic nervous dysfunction in systemic lupus erythematosus and rheumatoid arthritis: possible pathogenic role of autoantibodies to autonomic nervous structures. *Clin Exp Immunol* 1997;110:423-7.
7. Ewing DJ, Clarke BF. Autonomic neuropathy: its diagnosis and prognosis. *Clin Endocrinol Metab* 1986;15:855-88.
8. Neville BG, Sladen GE. Acute autonomic neuropathy following primary herpes simplex infection. *J Neurol Neurosurg Psychiatry* 1984;47:648-50.
9. Drenkard C, Villa AR, Reyes E, Abello M, Alarcon-Segovia D. Vasculitis in systemic lupus erythematosus. *Lupus* 1997;6:235-42.
10. Chinn RJ, Wilkinson ID, Hall-Craggs MA, Paley MN, Shortall E, Carter S, Kendall BE, Isenberg DA, Newman SP, Harrison MJ. Magnetic resonance imaging of the brain and cerebral proton spectroscopy in patients with systemic lupus erythematosus. *Arthritis Rheum* 1997;40:36-46.
11. Lim MK, Suh CH, Kim HJ, Cho YK, Choi SH, Kang JH, Park W, Lee JH. Systemic lupus erythematosus: brain MR imaging and single-voxel hydrogen 1 MR spectroscopy. *Radiology* 2000;217:43-9.
12. Courten-Myers GM de, Yamaguchi SI, Wagner KR, Ting P, Myers RE. Brain injury from marked hypoxia in cats: role of hypotension and hyperglycemia. *Stroke* 1985;16:1016-21.

一位全身性紅斑狼瘡婦女發生急性可逆姿態性低血壓

楊宗翰¹ 李蒔青^{1,2} 劉烈邦¹

報告首例急性可逆姿態性低血壓出現在一位確定為全身性紅斑狼瘡的台灣年輕女性。病患因發燒及狼瘡驟發而住院。一系列的檢查發現低血鉀(第一型)遠端腎小管酸血症。住院中發生了急性有症狀的姿態性低血壓，在代謝性酸血症及低血鉀恢復後，病患的症狀並未改善。磁共振造影並沒有異常的發現。然而，腦部的磁共振頻譜發現在被殼的N-乙酰天門東酸及肌酸比(NAA/Cr ratio)降低。最後，病人的姿態性低血壓在類固醇治療後恢復。因此，作者認為，在排除低血鉀、代謝性酸中毒及週邊神經系統所引起的姿態性低血壓，在全身性紅斑狼瘡患者應考慮中樞神經系統病變。(長庚醫誌 2006;29(4 Suppl):97-102)

關鍵字：姿態性低血壓，磁共振頻譜，腎小管酸血症，全身性紅斑狼瘡。

¹長庚紀念醫院 台北院區 內科部 風濕過敏免疫科；²桃園聖保祿醫院 內科部

受文日期：民國94年3月21日；接受刊載：民國94年9月5日

索取抽印本處：劉烈邦醫師，長庚紀念醫院 內科部 風濕過敏免疫科。桃園縣333龜山鄉復興街5號。Tel.: (03) 3281200轉8810; Fax: (03) 3281200轉8813; E-mail: b890121@adm.cgmh.org.tw