

An Intraosseous Capillary Hemangioma Of The Foot In A Child

Kah-Wai Ngan, MD; Hui-Ling Hsu¹, MD; Shir-Hwa Ueng, MD

An 8-year-old boy presented with an osteolytic lesion at the fourth metatarsal of the right foot. He received a surgical excision. Microscopically, the tumor was composed of lobules of capillary sized vascular channels with occasional dilated crescent-shaped openings at the periphery. Intraosseous hemangioma accounts for approximately 1% of all primary bone tumors. Furthermore, it is especially uncommon to be located at this site. An intraoperative frozen section would be helpful in order to avoid excessive and ineffective treatment of intraosseous hemangioma. (*Chang Gung Med J 2006;29(4 Suppl):71-5*)

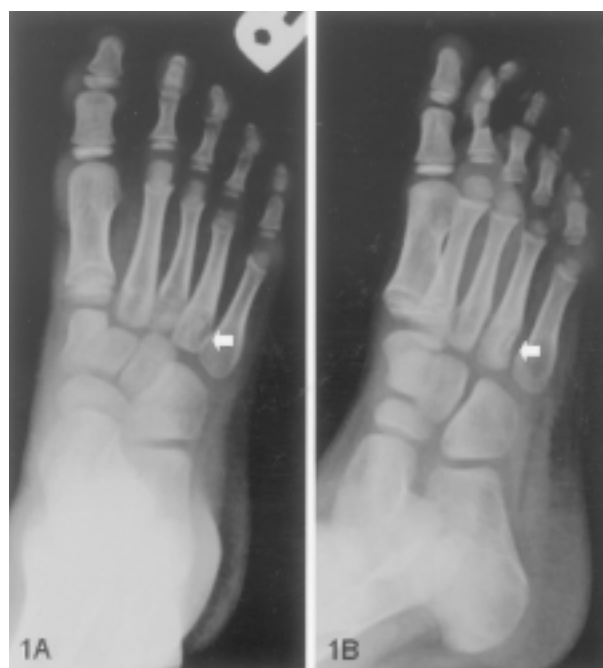Key words: intraosseous hemangioma, foot, metatarsal, capillary hemangioma.

Intraosseous hemangioma is an uncommon benign vascular tumor. It accounts for about 1% of all primary osseous tumors.⁽¹⁾ It is considered rare to be found in a foot. We report a case of intraosseous hemangioma of an 8-year-old boy with an initial presentation of an osteolytic lesion in the right fourth metatarsal bone.

CASE REPORT

An 8-year-old boy visited our orthopedic outpatient department in October 2003 complaining of pain, for two to three months, in the right foot. Though localized swelling was noted, the physical examination showed the full range of movement. Blood tests showed an elevated C-reactive protein (9.1 mg/dL) and alkaline phosphatase (204 U/L).

The plain radiographs of the right foot showed an osteolytic lesion at the fourth metatarsal base with cortical destruction (Figs. 1A-B). Magnetic resonance images revealed an infiltrating medullary lesion, about 2 cm in size, involving the proximal portion of the fourth metatarsal bone with cortical breakthrough and adjacent soft tissue involvement.



Figs. 1A-B Posteroanterior and oblique roentgenograms of the right foot revealed an eccentric osteolytic lesion involving fourth metatarsal base. There is cortical destruction at lateral side (White arrows).

From the Department of Anatomical Pathology, ¹Department of Radiology, Chang Gung Memorial Hospital, Taipei.

Received: Apr. 13, 2005; Accepted: Aug. 9, 2005

Correspondence to: Dr. Kah-Wai Ngan, Department of Pathology, Chang Gung Memorial Hospital, 5, Fushing Street, Gueishan Shiang, Taoyuan, Taiwan 333, R.O.C. Tel.: 886-3-3281200 ext. 2743; Fax: 886-3-3280147; E-mail: ngan@cgmh.org.tw

The lesion was well enhanced after contrast administration (Figs. 2A-D). These imaging findings were suggestive of an infiltrative process, such as: osteomyelitis, Langerhan cell histiocytosis, or Ewing's sarcoma.

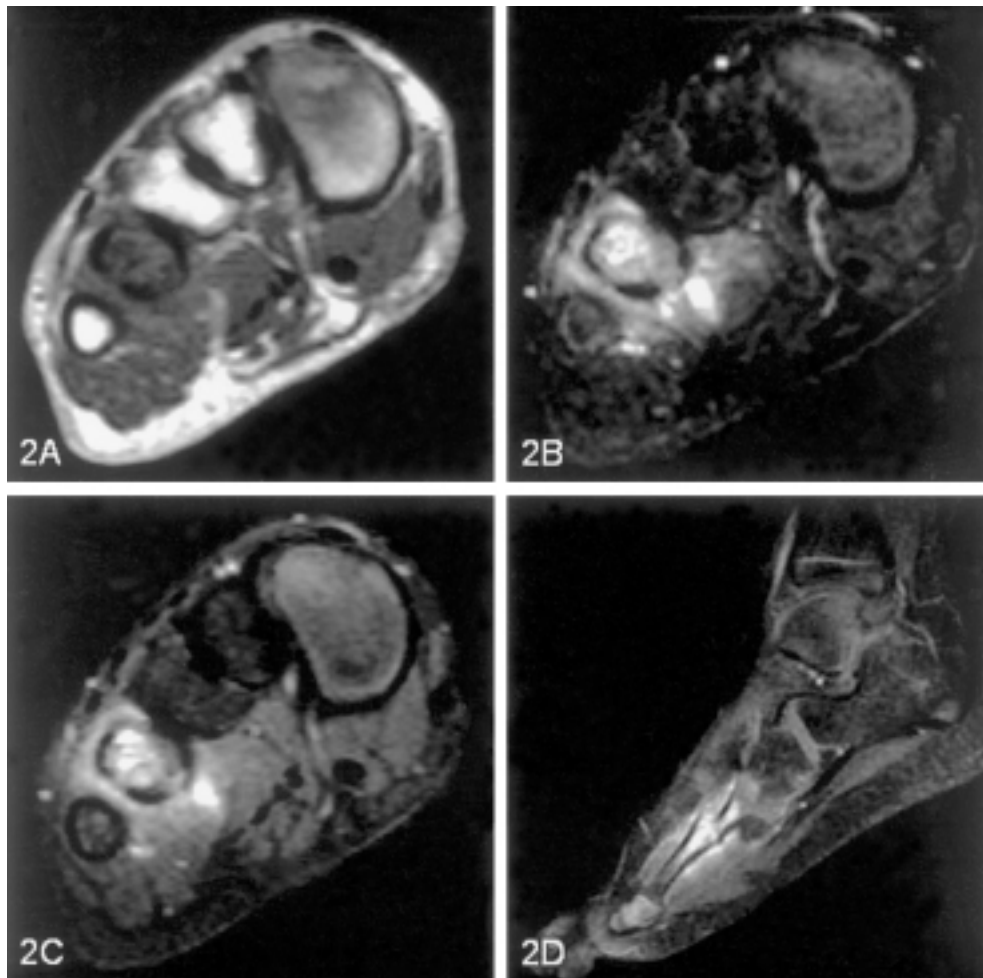
With the possibility of a malignant bone lesion, surgical intervention was performed. The intraosseous content was submitted for a frozen section study. He received a local excision of the tumor after a benign vascular lesion was evident.

Microscopically, the tumor was composed of lobules of capillary sized vascular channels with occasional dilated crescent-shaped openings at the periphery (Figs. 3-4). These vascular channels interspersed among the bony trabeculae. Furthermore,

hemosiderin deposits and fibrosis were seen.

An immunohistochemical study was performed on formalin-fixed, paraffin embedded tissue by avidin-biotin-peroxidase method with the Ventana autostaining system. The immunostains used were CD34 (1:100, DAKO) and factor VIII related antigen (1:200, DAKO). These tumor cells were immunoreactive for both vascular markers, CD 34 and factor VIII related antigen. A diagnosis of intraosseous capillary hemangioma was confirmed.

The patient received the standard postoperative follow-up. His symptoms had improved in part. The most recent MRI study, performed one year after the surgery, showed a residual lesion at the previous site.



Figs. 2A-D Axial T1- and T2-weighted (A, B) MR images of the right foot show an infiltrating medullary lesion involving proximal portion of the fourth metatarsal bone with cortical breakthrough and adjacent soft tissue involvement. Post-contrast axial and sagittal T1-weighted (C, D) MR images show strong enhancement of both intramedullary component and adjacent soft tissue.

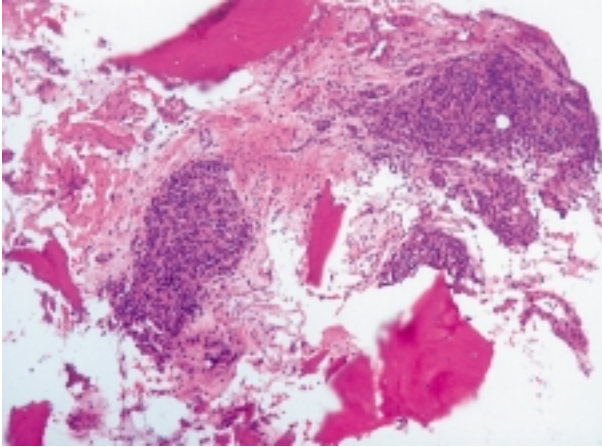


Fig. 3 Lobules of capillary sized vascular channels interspersed among bony trabeculae (H & E, x 100).

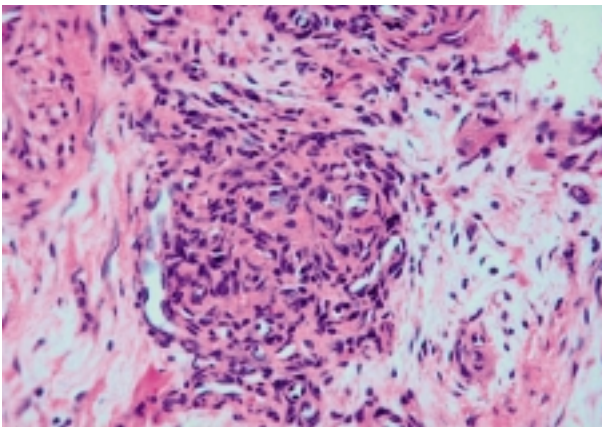


Fig. 4 At higher magnification, there is dilated crescent-shaped opening at peripheral of the capillary lobules. (H & E, x 400).

DISCUSSION

Primary intraosseous hemangioma is an uncommon bone tumor. The majority of cases are seen in the cranium and vertebrae, either as solitary or as multiple lesions. It is rarely found in a foot. None of the 108 intraosseous hemangiomas in Dahlin's series was found in a foot.⁽²⁾

Of the twenty-four cases of intraosseous hemangioma described by Dorfman et al. in 1971, only two occurred in feet.⁽¹⁾ Of the total 255 cases in a large series of primary intraosseous neoplasm of the foot, reported by Murani et al. in 1989, only three cases were diagnosed as hemangioma.⁽³⁾ Furthermore, it comprises of approximately 1.2% of all intraosseous neoplasm found in feet. Mirra added another two cases of intraosseous hemangiomas in tarsal bones of the foot.⁽⁴⁾ Since then, only limited cases were described in English medical literature. All cases, including ours, are summarized in Table 1.

From a radiological point of view, the classic corduroy and sunburst patterns of vertebral and skull hemangiomas are uncommon in extremity sites. The extremity site lesions may have a classic coarse trabecular bone pattern or soap bubble appearance, but a permeative pattern of irregular bone destruction can also be seen. Due to the diversity of radiological patterns produced by the skeletal hemangiomas, a correct preoperative diagnosis is rarely made.⁽⁵⁾

The most common histological pattern of intraosseous hemangioma is the cavernous type, although capillary or mixed patterns of growth might

Table 1. Summary of Reported Cases of Intraosseous Hemangioma of the Foot

Author(s)	Number of cases	Age	Gender	Location of tumor	Histological features
Dorfman et al. ⁽¹⁾	2	NA	NA	Calcaneus (1), Tarsal (1)	Cavernous, another case: NA
Mirra ⁽⁴⁾	2	NA	NA	Tarsal (2)	NA
Murani et al. ⁽³⁾	3	29 (8-45)	Males	Metatarsal (2), Talus (1)	NA
Sheth et al. ⁽⁶⁾	1	35	Male	Talus	Venous
Wu ⁽⁷⁾	1	46	Male	Talus	Cavernous
Davies ⁽⁸⁾	1	57	Male	Midfoot, includes: Cuneiform, Metatarsal, Naviculocuneiform joint, and cuboid	Mixed cavernous and capillary
Our case	1	8	Male	Fourth metatarsal	Capillary

Abbreviation: NA: not available

also be seen. This case is not pyogenic granuloma since no inflammatory cell infiltrates are seen. Another differential diagnosis is Kaposiform hemangioendothelioma, a borderline vascular tumor which has the features of both capillary hemangioma and Kaposi's sarcoma. However, the Kaposi-like area that composed of spindle cells with a slit-like pattern and hyaline globules is not evident in our case. The bland looking tumor cells are easily distinguished from those in intermediate and high-grade vascular tumors, such as epithelioid hemangioendothelioma and angiosarcoma.

Intraosseous hemangioma of the foot can be either asymptomatic or painful. Symptomatic hemangioma usually requires further management. Surgical excision or vascular ablative treatment is then justified.

In conclusion, at present, only 12 cases of intraosseous hemangioma found in feet have been reported in medical literature. Our case is the thirteenth and notably the first case that has occurred in a child. When encountering an osteolytic bone lesion of the foot, intraosseous hemangioma should always be considered among the differential diagnosis as stated above. By maintaining a high degree of alertness, coupled with an intraoperative frozen section

study to delineate the benign nature of this lesion, unnecessary, ineffective and excessive treatment can be avoided.

REFERENCES

1. Dorfman HD, Steiner GC, Jaffe HL. Vascular tumor of bones. *Hum Pathol* 1971;2:349-76.
2. Unni KK. *Dahlin's Bone Tumors. General Aspects and Data on 11087 Cases*, 5th ed. Lippincott-Raven Publishers, 1996:307-16.
3. Murani TM, Callaghan JJ, Berrey BH and Sweet DE. Primary benign and malignant osseous neoplasm of the foot. *Foot Ankle* 1989;10:68-80.
4. Mirra JM. Vascular tumors. In: Mirra JM, ed. *Bone Tumors*, vol 2. Lea and Febiger: Philadelphia, 1989:1338-69.
5. Kaleem Z, Kyriakos M, Totty WG. Solitary skeletal hemangioma of the extremities. *Skeletal Radiol* 2000;29:501-13.
6. Sheth D, Marcore RC, Healey J, Wilson M, Huvos AG. Intraosseous hemangioma of the talus: A case report. *Foot Ankle Int* 1994;15:41-3.
7. Wu KK. Intraosseous hemangioma of the foot. *J Foot Ankle Surg* 1994;33:314-7.
8. Davies JL, Stone PA, Mc Garry JJ. Mixed cavernous and capillary hemangioma of the foot. *J Am Pediatr Med Assoc* 1997;87:478-82.

小孩的足部骨內血管瘤

顏嘉慧 徐惠玲¹ 翁世樺

一位八歲大的男孩右腳第四蹠骨出現溶骨性病灶，並接受手術治療。顯微鏡下，腫瘤是由微血管大小的血管所組成，偶爾血管團邊緣呈現新月型的開口。骨內血管瘤佔原發性骨頭腫瘤的1%左右，發生於足部更為罕見。術中冷凍切片檢查可以確立診斷並避免過多的治療。(長庚醫誌 2006;29(4 Suppl):71-5)

關鍵字：骨內血管瘤，足部，蹠骨，微血管血管瘤。

長庚紀念醫院 台北院區 病理科，¹放射科

受文日期：民國年月日；接受刊載：民國年月日

索取抽印本處：顏嘉慧醫師，長庚紀念醫院 病理科。桃園縣333龜山鄉復興街5號。Tel.: (03)3281200轉2743; Fax: (03)3280147; E-mail: ngan@cgmh.org.tw