

Vastus Lateralis Muscle Flap Used for Reconstruction of the Maxilla after Radical Resection of Recurrent Ameloblastoma

Chi-Ying Tsai, DDS, PhD; Fu-Chan Wei¹, MD; Yu-Liang Chang, DDS, PhD;
Ya-Yi Chen², DDS, MSD; Chien-Tzung Chen¹, MD

Maxillary ameloblastoma is a benign odontogenic neoplasm. Excision should involve wide margins because of its high recurrence rate and, ideally, be followed by reconstruction. A 23 year-old female patient presented with recurrent ameloblastoma. Two years previously, she had undergone a curettage excision. The recurrent lesion was managed by a total maxillectomy including inferior orbital rim. Simultaneous reconstruction was performed with an iliac crest bone graft for the orbital floor, and a vastus lateralis muscle flap for obliteration of the maxillary sinus and repair the oral and nasal cavities. The transferred vastus lateralis muscle already had spontaneous mucosalization over its surface two weeks after surgery. Postoperative follow up after fourteen months revealed no recurrence and no diplopia. The patient was satisfied with her appearance. The use of a single vastus lateralis muscle flap to repair both oral and nasal cavities is advantageous. It helps avoid hyper-nasal speech and maintain the stability of removable partial dentures. The conventional iliac bone graft supported by a well vascularized muscle eventually survived and provided a good functional and cosmetic result. (*Chang Gung Med J 2006;29:331-5*)

Key words: maxillary ameloblastoma, iliac crest, vastus lateralis muscle flap.

Ameloblastoma is a benign odontogenic neoplasm of the mandible and maxilla.^(1,2) However, it is reported that maxillary ameloblastoma behave more aggressively and have a poorer prognosis compared with mandibular ameloblastoma.⁽³⁾ The painless and slow growth of the lesion and the thin bone of the maxilla are the main factors involved in delay in recognizing a maxillary ameloblastoma.⁽⁴⁾

Conservative treatment of a ameloblastoma usually results in recurrence and possible malignant transformation.⁽⁵⁾ Radical excision of the tumor followed by adequate reconstruction can improve survival and provide more satisfactory functional and cosmetic results.⁽⁶⁾ However, reconstruction of multifaceted maxillary defects is a challenge to the reconstructive surgeon, as it requires provision of adequate

anatomical structural support to separate the oral and nasal cavities, and to obliterate the dead space in the maxillary sinus.

Here we report on a recurrent maxillary ameloblastoma that was successfully treated with radical excision and simultaneous reconstruction using an iliac bone graft for the orbital rim and a free vastus lateralis muscle flap for the maxillary antrum, oral and nasal cavities.

CASE REPORT

A 23 year-old female patient presented with a right upper molar gingival swelling that had been present for several months. She noted unusual loosening of her right first upper molar tooth, which was

From the Department of Oral and Maxillofacial Surgery, ¹Department of Plastic and Reconstructive Surgery, ²Department of Dentistry, Chang Gung Memorial Hospital, Taipei.

Received: Jul. 23, 2004; Accepted: Nov. 1, 2004

Correspondence to: Dr. Fu-Chan Wei, Department of Plastic and Reconstructive Surgery, Chang Gung Memorial Hospital, 199, Duenhua N. Road, Sungshan Chiu, Taipei, Taiwan 105, R.O.C. Tel.: 886-2-27135211 ext. 3493; Fax: 886-2-27189475; E-mail: Fcw2007@adm.cgmh.org.tw

extracted by a local dentist. However, the wound did not heal and she was eventually referred to our care. Clinical examination revealed a fungating mass about 4 x 5 cm in size in the right upper alveolar region (Fig. 1-A), and an incisional biopsy was performed. The pathology report cited pseudoepitheliomatous hyperplasia. Under general anesthesia, the patient underwent curettage via an intraoral approach. The defect was repaired using a buccal fat pad flap. After surgery, the final histopathology showed plexiform ameloblastoma. The wound remained unhealed with a persistent oro-antral fistula, which was managed by secondary closure. The patient then remained symptom free for two years.

However, due to persistent right facial swelling and numbness, a computed tomography (CT) scan was requested, which revealed a space-occupying lesion in the maxillary sinus involving the orbital floor, nasal concha and the anterior wall of the maxillary sinus. A recurrent ameloblastoma was suspect-

ed and radical excision of the lesion was planned.

The patient then underwent a total maxillectomy via a Weber-Ferguson incision with preservation of the orbit (Fig. 1-B). A frozen specimen was taken from the ethmoid sinus membrane, inferior border of the eyeball and nasal mucosa, and was tumor-free. To repair the inferior orbital rim defect, a piece of iliac crest was harvested, shaped and fixed with a microplate and screws (Fig. 1-C). A flap of vastus lateralis muscle (Fig. 1-D), based on the descending branch of the lateral circumflex femoral vessel, was harvested and used to obliterate the dead space in the maxillary sinus and wall off the oral and nasal cavities. No skin graft was used. The raw surfaces of the transferred vastus lateralis muscle on both the nasal and oral sides were left to mucosalize spontaneously. The muscle was then revascularized through microsurgical anastomoses with the facial vessels. A preformed acrylic surgical stent was fixed to the teeth to prevent the vastus lateralis muscle from falling

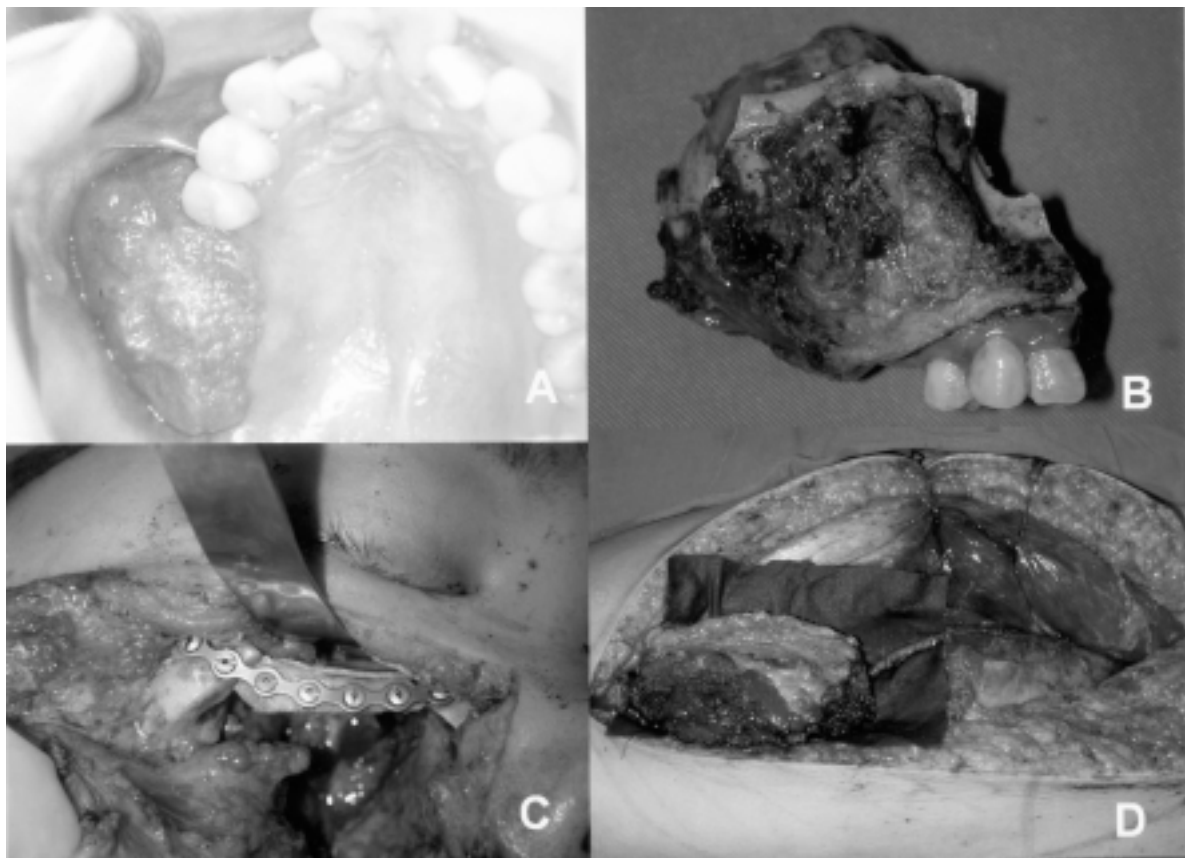


Fig. 1 (A) Bulging mass about 4 x 5 cm in size inside the oral cavity; (B) Surgical specimen; (C) Repair of infraorbital rim with an iliac crest bone graft; (D) Vastus lateralis muscle flap, elevated.

down. The postoperative course was uneventful. At the time of the acrylic stent removal, two weeks after surgery, the transferred vastus lateralis muscle already showed spontaneous mucosalization over its surface.

At the follow up examination fourteen months after surgery, the entire vastus lateralis muscle was still covered with normal-looking mucosa (Fig. 2-A), the eyes were at the same level without diplopia, facial symmetry was good and mouth opening (inter-incisor distance) was 40 mm. The patient was satisfied with her appearance (Fig. 2-B, Fig. 2-C). A follow up magnetic resonance imaging (MRI) study revealed no tumor recurrence, and the grafted iliac crest remained intact with no resorption (Fig. 2-D).

DISCUSSION

Maxillary ameloblastoma is an aggressive benign tumor. Rapid growth of the tumor is not unusual due to its closeness to the maxillary sinus.

However, the patient may not notice the mass until it has eaten away the bone. Although histologically benign, recurrence rate is high. Occasionally it transforms into ameloblastic carcinoma and metastasizes to distant organs, most commonly the lungs.⁽⁷⁾ Repeated surgical treatment has a potential of spreading lesions to the base of the skull, which can be fatal. Therefore, radical resection of the tumor at the first surgery is important to achieve a complete cure.

Due to the high recurrence rate of maxillary ameloblastoma, some authors suggest using only an obturator for the defect left after tumor resection in order to retain a better view of the site.^(8,9) However, the obturator cannot replace all deficiencies in the maxillary bone, and this can result in mid-facial depression. Furthermore, the poor stability of a palatal obturator, due to lack of soft and hard tissue support and anchorage, will be a problem for the patient in daily life. For a young female patient, reconstruction, which takes into consideration con-

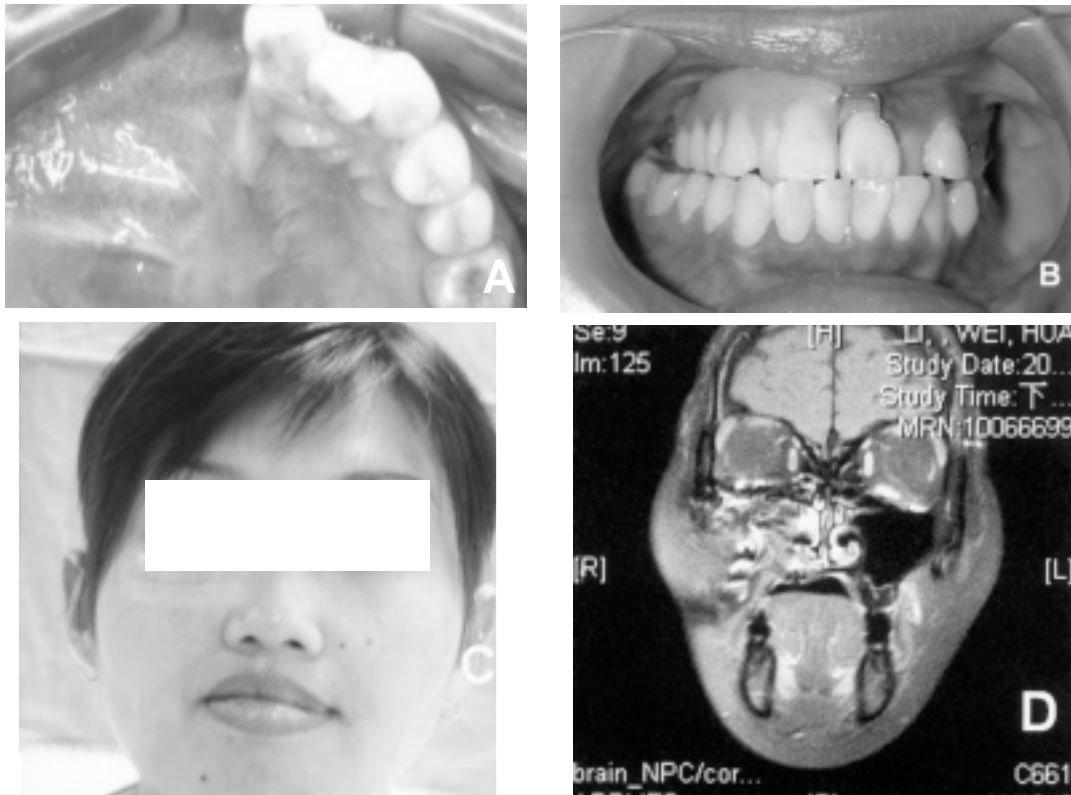


Fig. 2 (A) Vastus lateralis muscle covered with normal mucosa rather than keratinized epithelium; (B) Removable partial denture in place; (C) Symmetry of the face; (D) Follow up MRI study revealed no recurrence of the tumor.

cerns of both function and appearance, is important. A one-stage complete reconstruction after radical excision, if possible, is the ideal approach.

There are several methods that can be used to reconstruct the maxilla defect after excision of the tumor: using a free fibula flap is one option.⁽¹⁰⁾ It can be osteotomized to obtain a form similar to the maxillary arch. However, it was not suitable for this patient as it could not be harvested together with the necessary soft tissue required to obliterate the maxillary dead space. Inadequate tissue replacement not only predisposes to infection but also leads to mid-face depression. The same reason also holds true for other vascularized bone. This is a complicated, more than three-dimensional, defect reconstruction and so, if maxillary bone reconstruction is necessary, it can be planned at a second stage.

Although the anteriolateral thigh flap is an ideal workhorse flap for reconstruction of soft tissue defects inside the oral cavity, the skin is not pliable enough for insertion into the maxillary sinus. In contrast, the vastus lateralis muscle flap is pliable and more conformable to the dead space in the maxillary sinus. Sacrifice of vastus lateralis muscle has been proven to be unharmed to knee function.⁽¹¹⁾ The preformed surgical stent^(12,13) was useful in preventing the muscle from falling into the oral cavity, and also helped to maintain all the dead space obliterated by the inserted flap. The fact that survived muscle can have spontaneous mucosalization has been observed;⁽¹⁴⁾ our experience also confirmed such a possibility as long as there is a stent to support the muscle. The repair of oral and nasal cavities with part of the vastus lateralis muscle also helps avoid hyper-nasal speech and maintain the stability of a removable partial denture. The vastus lateralis muscle flap may, theoretically, shrink to a certain extent. However, in our case shrinkage was not significant more than one year after surgery. The stimulation from the denture may have minimized muscle atrophy but longer follow up is required to confirm this possibility. The mild depression present on the operated side mainly occurs due to lack of maxillary bone, which can be totally corrected in a secondary vascularized bone graft reconstruction.

In summary, this case demonstrates the advan-

tage of radical excision of a maxillary ameloblastoma with immediate one-stage reconstruction.

REFERENCES

1. Verneuil A, Sapp P, Huang C, Abemayor E. Malignant ameloblastoma: classification, diagnostic, and therapeutic challenges. *Am J Otolaryngol* 2002;23:44-8.
2. Munir M. Ameloblastoma of the jaws. *Gan To Kagaku Ryoho* 2000;27 Suppl 2:261-7.
3. Jackson IT, Callan PP, Forte RA. An anatomical classification of maxillary ameloblastoma as an aid to surgical treatment. *J Craniomaxillofac Surg* 1996;24:230-6.
4. Iordanidis S, Makos C, Dimitrakopoulos J, Kariki H. Ameloblastoma of the maxilla. Case report. *Aust Dent J* 1999;44:51-5.
5. Olaitan AA, Arole G, Adekeye EO. Recurrent ameloblastoma of the jaws. A follow-up study. *Int J Oral Maxillofac Surg* 1998;27:456-60.
6. Zwahlen RA, Gratz KW. Maxillary ameloblastomas: a review of the literature and of a 15-year database. *J Craniomaxillofac Surg* 2002;30:273-9.
7. Onerci M, Yilmaz T, Dogan R, Sungur A. Pulmonary metastasectomy in the treatment of recurrent ameloblastoma of the maxilla and mandible: a case report. *Eur Arch Otorhinolaryngol* 2001;258:25-7.
8. Borlase G. Use of obturators in rehabilitation of maxillectomy defects. *Ann R Australas Coll Dent Surg* 2000;15:75-9.
9. Rogers SN, Lowe D, McNally D, Brown JS, Vaughan ED. Health-related quality of life after maxillectomy: a comparison between prosthetic obturation and free flap. *J Oral Maxillofac Surg* 2003;61:174-81.
10. Ferri J, Caprioli F, Peuvrel G, Langlois JM. Use of the fibula free flap in maxillary reconstruction: a report of 3 cases. *J Oral Maxillofac Surg* 2002;60:567-74.
11. Demirkan F, Chen HC, Wei FC, Chen HH, Jung SG, Hau SP, Liao CT. The versatile anterolateral thigh flap: a musculocutaneous flap in disguise in head and neck reconstruction. *Br J Plast Surg* 2000;53:30-6.
12. Har-El G, Bhaya M. Intraoperative fabrication of palatal prosthesis for maxillary resection. *Arch Otolaryngol Head Neck Surg* 2001;127:834-6.
13. Lindahl L, Lindstrom J. Integrated prosthetic and surgical treatment of malignant tumours of the maxilla. A new acrylic plate device. *Scand J Plast Reconstr Surg* 1978;12:279-81.
14. Wolff KD. Indications for the vastus lateralis flap in oral and maxillofacial surgery. *Br J Oral Maxillofac Surg* 1998;36:358-64.

股外肌皮瓣重建廣範切除後之復發上顎造釉細胞瘤

蔡啓穎 魏福全¹ 張佑良 陳雅怡² 陳建宗¹

上顎造釉細胞瘤是顎骨良性腫瘤，但因復發機率高，必須廣範切除後作重建。病例：23歲女性，主訴右臉腫脹。兩年前曾接受右上顎造釉細胞瘤刮除手術，並以頰脂墊修補。現今復發，腫瘤長到下眼框。施行腫瘤廣泛切除術後，取腸骨脊修補下眼框，再取左側大腿股外肌皮瓣修補鼻腔側壁及上顎竇。術後2週上顎竇塞滿肌肉皮瓣而緊實，且上顎黏膜再生。術後14個月，無復發，雙眼無複視。病患對外觀及咬合功能均很滿意。取股外肌皮瓣將鼻腔及口腔分開，避免術後說話有鼻音，可維持活動假牙穩定性。傳統之腸骨脊骨移植受到股外肌皮瓣之包裹，使其存活不被吸收，並可得到良好的外觀及功能。(長庚醫誌 2006;29:331-5)

關鍵字：上顎造釉細胞瘤，腸骨脊，股外肌皮瓣。

長庚紀念醫院 台北院區 口腔外科；¹整形外科；²牙科義齒補綴科

受文日期：民國93年7月23日；接受刊載：民國93年12月1日

通訊作者：魏福全醫師，長庚紀念醫院 整形外科。台北市105敦化北路199號。Tel.: (02)27135211轉3493; Fax: (02)27189475; E-mail: Fcw2007@adm.cgmh.org.tw