

## Exchange Nailing for Aseptic Tibial Shaft Nonunion: Emphasis on the Influence of A Concomitant Fibulotomy

Chih-Wen Hsiao, MD; Chi-Chuan Wu, MD; Chun-Yi Su, MD; Kuo-Feng Fan, MD; I-Chuan Tseng, MD; Po-Chang Lee, MD

**Background:** Exchange nailing is reported to have a high success rate for aseptic tibial nonunions. However, sample sizes in all series in the literature were small, and the influence of a concomitant fibulotomy was not evaluated.

**Methods:** Fifty-four aseptic tibial shaft nonunions for 1.2~4.3 (mean, 2.4) years were treated with exchange nailing. Indications for this technique included an aseptic nonunion of the tibial shaft with an inserted intramedullary nail and < 2 cm of shortening. A fibulotomy was performed in a nonunion with poor shaft alignment, which concomitantly required manipulation to correct. The success rate of exchange nailing was determined, and whether a concomitant fibulotomy affected the success rate was evaluated.

**Results:** Forty-seven nonunions were followed-up for 1.1~6.9 (mean, 3.8) years, and all nonunions healed. The union rate was 100% (47/47), and the average period required to achieve union was 4.7 (3.0~7.5) months. The average union periods between the fibulotomy and non-fibulotomy groups did not statistically differ (4.6 vs. 4.8 months,  $p = 0.61$ ). There were no significant complications in either group.

**Conclusions:** Exchange nailing is an excellent technique to treat aseptic nonunions of the tibia. It can be considered the treatment of choice for all indicated cases. A concomitant fibulotomy has minimal influence on the success rate. It can be performed when the shaft alignment needs correction.

*(Chang Gung Med J 2006;29:283-90)*

**Key words:** exchange nailing, tibia, fibulotomy.

Tibial shaft nonunions are not uncommon, and normally are caused by failed treatment of acute fractures. Because of the subcutaneous location of the medial aspect of the tibia, acute fractures are often open types, and nonunions are often associated with deep infection.<sup>(1,2)</sup> Treatment of infected tibial nonunions is usually complicated.<sup>(3)</sup> As for aseptic nonunions, various nonoperative or operative treat-

ment techniques may achieve different success rates.<sup>(4,5)</sup> Nevertheless, an adequate treatment method should be chosen which adequately deals with the situation at hand.

In the literature, closed and mildly open tibial shaft fractures treated with closed unlocked or locked intramedullary nails achieved high union rates.<sup>(6,7)</sup> An aseptic nonunion after closed tibial

---

From the Department of Orthopedics, Chang Gung Memorial Hospital, Taipei, Chang Gung University.

Received: Aug. 22, 2005; Accepted: Dec. 29, 2005

Correspondence to: Dr. Chih-Wen Hsiao, Department of Orthopedics, Chang Gung Memorial Hospital, 5, Fushing Street, Gueishan Shiang, Taoyuan, Taiwan 333, R.O.C. Tel.: 886-3-3281200 ext. 2423; Fax: 886-3-3289582; E-mail: mr3507@adm.cgmh.org.tw

intramedullary nailing is therefore uncommon. Once it occurs, treatment with exchange nailing may achieve a high success rate.<sup>(8-11)</sup> Other advantages of exchange nailing include a small operative wound, no need for a donor wound to procure a cancellous bone graft, its technical simplicity, and achievement of early ambulation.

Technically, tibial exchange nailing may require a concomitant fibulotomy to correct the shaft alignment. In that situation, is the success rate of treatment greatly affected? Theoretically, a fibulotomy can enforce tibial shaft compression, thus promoting fracture repair. Conversely, it may decrease local stability, thus hindering fracture repair. Such contradictory arguments, to the best of our knowledge, have not been clarified in the literature. Furthermore, the sample sizes of all series reporting on tibial exchange nailing were small, and the exact effects might not be very representative.<sup>(8-11)</sup> The purposes of this retrospective study were to investigate this uncertainty and further evaluate the effect of exchange nailing.

## METHODS

Between September 1997 and December 2003, 54 patients with 54 aseptic tibial shaft nonunions after intramedullary nailing were treated with exchange nailing at our institution. Patients were aged 21~72 (mean, 38) years with a male-to-female ratio of 4 to 1. All of the fractures were a result of motor vehicle accidents. Those fractures were initially treated at various hospitals including ours. The initial fracture types included closed and types I, II, IIIA, and IIIB open fractures.<sup>(12)</sup> Patients underwent 1~6 (mean, 1.7) operations before the exchange nailing. The period from the time of injury to the revision surgery was 1.2~4.3 (mean, 2.4) years.

We retrospectively reviewed the records of all patients, including the previous course of fracture treatment, the fracture healing process, and the wound condition. If deep infection had occurred, the nonunion was treated with other techniques, and those patients were excluded from this study.<sup>(3)</sup>

Cases with an elevated white blood cell (WBC) count, erythrocyte sedimentation rate (ESR), or C-reactive protein (CRP) or any other evidence suggestive of a latent infection were also excluded from the study. All laboratory data of the study cohort were within acceptable ranges. Indications for this tech-

nique included an aseptic nonunion of the tibial shaft with an inserted intramedullary nail, with < 2 cm of shortening, and a nonunion gap of < 5 mm. Nonunions with shortening exceeding 2 cm or with a nonunion gap exceeding 5 mm were treated with other technique, and those patients were excluded from this study.<sup>(13)</sup>

### Surgical technique

Under spinal anesthesia, patients were placed on a fracture table in the supine position. The lesion limb was hung vertically on the support post. A pneumatic tourniquet was routinely used. An image intensifier was prepared for nonunions requiring insertion of distal locked screws in order to maintain stability.

A fibulotomy was performed for tibial nonunions with malalignment (with angulation of > 5° or with a rotational deformity of > 10°), which required manipulation to achieve a normal axis.<sup>(5)</sup>

A skin incision was made along the medial edge of the patellar tendon. The previous intramedullary nails were removed. The shaft was forcefully manipulated to achieve a normal axis. In these nonunions, a normal axis was restored without opening the nonunion site. Nonunions which required open reduction were excluded from this study to simplify the comparisons.

The new nail inlet on the proximal tibia required revision in some cases. If so, the new inlet was made just beneath the medial edge of the patellar tendon. A flexible guide wire was inserted into the marrow cavity, and the cavity was reamed as widely as possible. An interlocking nail (Howmedica, Kiel, Germany or Smith & Nephew, Memphis, TN, USA) was inserted. In those cases, the exchange reamed nail was 1~3 mm larger in diameter than the previous nail. The insertion of the 2 distal locked screws required guidance with an image intensifier. On this basis, the cross-screws were placed through either the proximal or distal nail-bone composite, depending on whether the nonunion site was over either the proximal 1/3 or the distal 1/3 of the tibia.<sup>(2)</sup> A dynamic locking mode was used for all patients.

After the operation, patients were permitted to ambulate with partial weight-bearing at as early a time as was possible. Crutches were used until the fractures had healed sufficiently. Patients were encouraged to engage in exercises to promote the

range of motion of the knee and ankle. Patients were followed-up at the OPD at 4~6-week intervals. The clinical and radiographic features of the fracture healing process were recorded. Complications were treated if necessary. After the fractures had healed, patients were followed-up annually or whenever necessary.

We defined a fracture union clinically as having no pain, no tenderness, and no need of aids to assist ambulation, and radiographically as a solid callus with sufficient cortical density to have connected both fragments. A nonunion was defined as a fracture site which had still not healed after 1 year or treatment or one for which repeated surgeries had to be performed to achieve union.<sup>(10,13)</sup>

For the convenience of comparisons, Fisher's exact test or the 2-tailed unpaired Student's *t*-test were used. A value of  $p < 0.05$  was considered statistically significant.

## RESULTS

Forty-seven patients were included in this study, and 47 patients with 47 nonunions were followed for 1.1~6.9 (mean, 3.8) years. The average age at the time of injury was 40.0 (range, 21~72) years. Seven patients with 7 nonunions were lost to follow-up despite our best efforts to contact them.

Nineteen nonunions were repaired by exchange nailing with a fibulotomy. The average age of this group was 36.0 (range, 21~68) years. The time from the initial injury to exchange nailing was 2.6 (range, 1.2~4.3) years. These patients underwent 1~6 (mean, 1.8) operations. Initially, in the exchange nailing with fibulotomy group, there were 6 closed- and 9 open-type grades I to IIIA and 4 open-type IIIB tibial fractures, according to the Gustilo-Anderson classification. The extent of malalignment ranged from 8.0° to 23.0° (mean, 13.5°) before the revision surgery. All 19 nonunions were treated using the exchange dynamic locking nail.

In the exchange nailing without a fibulotomy group, there were 28 nonunions in patients aged 23~72 (mean, 41) years, with an interval of 1.5~3.5 (mean, 2.2) years between the injury and exchange nailing surgery. They had undergone 1~4 (mean, 1.6) previous operations. There were 10 closed- and 15 open-type grades I to IIIA, and 3 open-type IIIB tibial fractures in this group. The malalignment of the

group ranged from 2.0° to 5.0° (mean, 3.5°) preoperatively. All 28 nonunions were treated using the exchange dynamic locking nail.

There were no significant differences in age, number of previous operations, or length of the nonunion period between the fibulotomy and non-fibulotomy groups ( $p > 0.05$ ) (Table 1).

In terms of union time and among the subgroups (closed-type fracture or open-type I-III A fracture and open-type IIIB fracture), there were no significant differences between the fibulotomy and non-fibulotomy groups. All 47 nonunions healed within 3.0~7.5 (mean, 4.7) months with a union rate of 100% (47/47). All 19 nonunions with a fibulotomy healed within 3.0~7.5 (mean, 4.6) months (Fig. 1), while all 28 nonunions without a fibulotomy healed within 3.0~7.0 (mean, 4.8) months ( $p = 0.61$ ) (Fig. 2).

There were no wound infections or malunion (with angulation  $> 5^\circ$ , rotational deformity  $> 10^\circ$ , or shortening  $> 2$  cm).<sup>(5)</sup>

The ranges of motion of the knee and ankle were nearly normal in all cases.

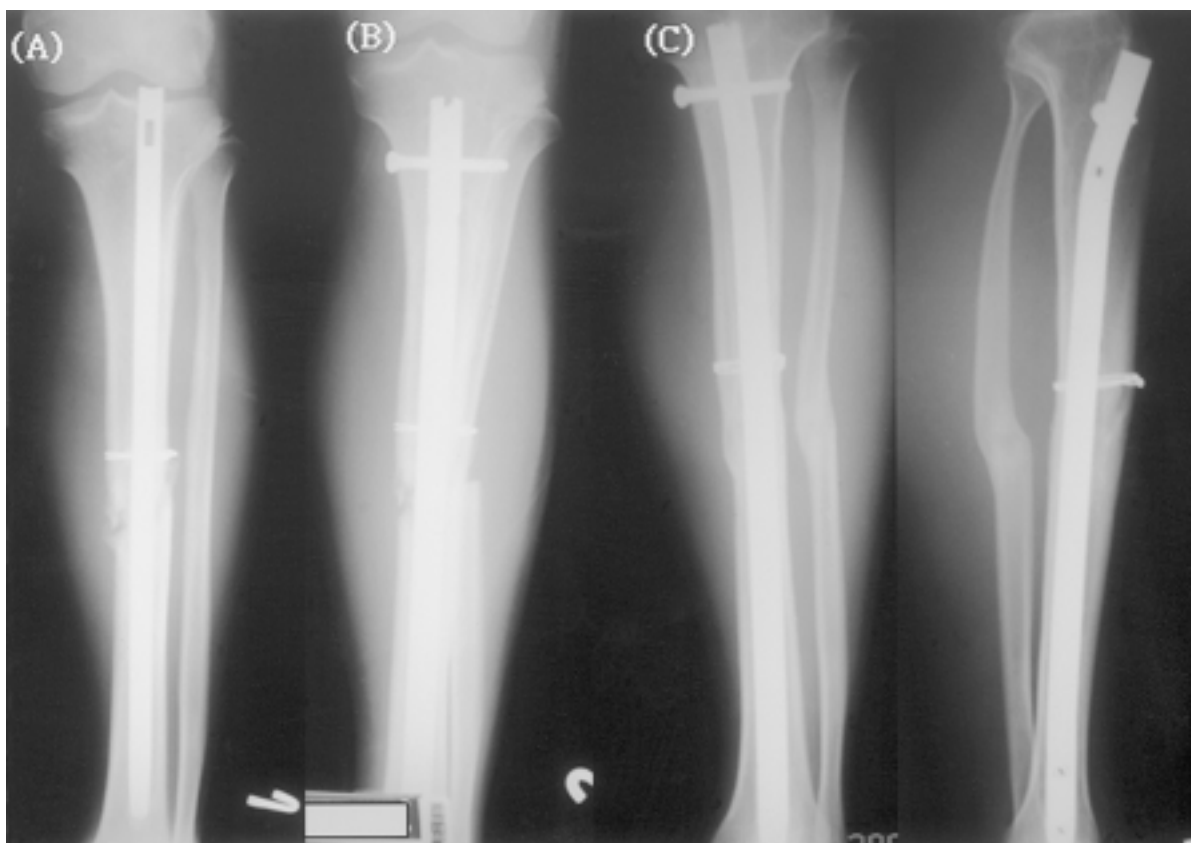
## DISCUSSION

Although nonunions are normally divided into hypertrophic and atrophic types, treating a nonunion always requires provision of sufficient stability and stimulation of osteogenic power.<sup>(14,15)</sup> Following advancements in modern technology, intramedullary nails are now considered to have sufficient stability for use during a fracture repair. Various nonoperative or operative techniques to stimulate the osteogenic power have become the key to successful treatment. In this study, a 100% success rate was achieved with exchange nailing.

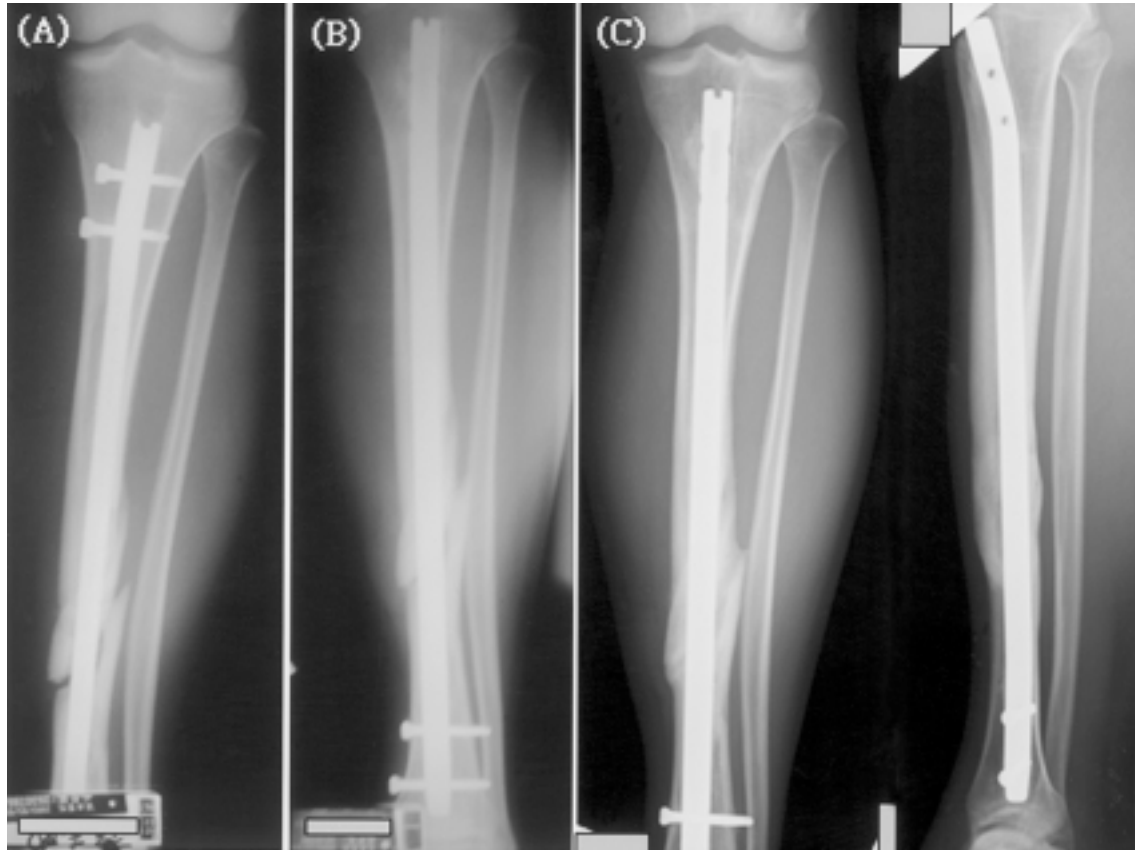
To stimulate osteogenic power, nonoperative techniques including ultrasonic, electrical, and shock-wave stimulation can be chosen. However, the majority of success rates were 80%~86%.<sup>(16-18)</sup> The success rates varies with the operative techniques: a simple fibulectomy had a 77% union rate;<sup>(19)</sup> plate treatment may be combined with removal or preservation of the intramedullary nail with union rates of 90%~95%;<sup>(20,21)</sup> an open cancellous bone graft was also associated with a high union rate of 98%;<sup>(22)</sup> and under unusual situations, augmentation with Ilizarov external fixation was reported to be successful in all

**Table 1.** Clinical Data for Aseptic Tibial Shaft Nonunion Treatment by Exchange Nailing With or Without a Fibulotomy

	Mean age (range; years)	Mean no. of previous operations (range)	Mean nonunion period (range; years)	Initial fracture type	Total no. of cases	No. of union cases/union rate (%)			
							Closed fracture	Open fracture grades I~IIIA	Open IIIB fracture
Exchange nailing with a fibulotomy	36 (21~68)	1.8 (1~6)	2.6 (1.2~4.3)	No. of cases	6	9	4	19	19/100%
				Mean union time (range; months)	4.7 (3.0~6.3)	4.4 (4.0~6.8)	4.9 (3.3~7.5)	4.6 (3.0~7.5)	
Exchange nailing without a fibulotomy	41 (23~72)	1.6 (1~4)	2.2 (1.5~3.5)	No. of cases	10	15	3	28	28/100%
				Mean union time (range; months)	4.6 (3.0~6.5)	5.0 (3.5~6.5)	4.7 (3.8~7.0)	4.8 (3.0~7.0)	
<i>p</i> value	0.89	0.91	0.82	0.69	0.48	0.58	0.61	1.00	



**Fig. 1** A 32-year-old woman sustained a left tibial fracture without a fibular fracture. The fracture was treated with open Kuntscher nailing and wiring. Two years after the injury, anteroposterior radiography (A) showing that persistent tibial nonunion with lateral angulation had occurred for 2 years. Anteroposterior radiography (B) after exchange nailing with a fibulotomy was performed. Anteroposterior and lateral radiography (C) showing that the fracture had uneventfully healed after 4 months.



**Fig. 2** A 36-year-old man sustained a left tibial fracture without a fibular fracture. The tibial fracture was treated with closed locked nailing. Anteroposterior radiography (A) showing that tibial nonunion had occurred for 1.5 years. Anteroposterior radiography (B) after exchange nailing without a fibulotomy was performed. The anteroposterior and lateral radiography (C) showing that the fracture had uneventfully healed after 4 months.

3 cases for which it was used.<sup>(23)</sup> Theoretically, exchange nailing requires only a small incision wound, produces less blood loss, is a simple technique, and allows early ambulation. Additionally, the reported union rate may be the highest among all techniques. Therefore, it may be considered the treatment of choice for all indicated cases.<sup>(8-11)</sup>

In the literature, exchange nailing has been the treatment of choice for aseptic femoral shaft nonunions after intramedullary nailing.<sup>(24,25)</sup> However, its success rate varied from 53% to 96%.<sup>(26,27)</sup> In contrast, success rates reported for tibial exchange nailing were 93%~100%.<sup>(8-11)</sup> Zelle et al.<sup>(11)</sup> reported that 38 (95%) patients achieved healing of tibial nonunions after exchange nailing. Union times with static locked versus dynamic locking nailing and whether or not a partial fibulectomy was required

showed no significant differences. Temoleman et al.<sup>(9)</sup> reviewed 27 cases of aseptic nonunion of the tibia, and reported that 25 (93%) nonunions healed after exchange nailing without an additional bone graft.

Normally, the vascularity of the surrounding soft tissues of the femur is better than that of tissues around the tibia. Conceivably, the reaming effect should not be closely correlated to the surrounding vascularity. Additionally, reaming only provides a thin layer of cancellous bone graft at the nonunion site. Thus, the tibia may be favored due to its relatively better stability, i.e., the fibula may provide some contribution. If so, a fibulotomy should be avoided if possible. In particular, a fibulotomy may be associated with peroneal nerve injury.<sup>(28)</sup>

In 1997, Thomas et al.<sup>(35)</sup> reported on compres-

sive strain patterns of biomechanical analyses of fractured tibias with intramedullary nailing with or without a partial fibulectomy, and no significant changes were noted in the loading patterns between the 2 groups in that cadaveric study. The effect of mechanical compression in enforcing fracture repair has been studied. A 77% success rate was achieved with a fibulectomy for treating tibial shaft nonunions.<sup>(19)</sup> A 64% success rate was achieved with dynamization for treating delayed tibial unions or nonunions after static locked nailing.<sup>(32)</sup> Based on previous data, a fibulotomy and early dynamization still have some functions during treatment of a nonunion.

Factors favoring fracture healing are a minimal gap, adequate stability, and sufficient nutrition supply.<sup>(30)</sup> Casting treatment for acute closed or mild open tibial shaft fractures produces a high delayed union or nonunion rate.<sup>(31)</sup> Accordingly, stability is the main factor during the tibial healing process. In this study, both the fibulotomy and non-fibulotomy groups achieved high success rates, so the stability provided by an intact fibula does not seem to be a critical factor. Reaming to produce an internal cancellous bone graft and using a larger-diameter nail may provide sufficient stability and osteogenic power for tibial nonunion treatment.

In the literature, over-reaming of at least 2 mm was recommended for femoral exchange nailing.<sup>(24)</sup> However, no similar comments were found for tibial exchange nailing. Biomechanically, using larger-diameter intramedullary nails can enforce the nail strength and reduce nail breakage rates.<sup>(29)</sup> Moreover, a larger caliber of locked screws is for tibial nails exceeding 11 mm in diameter, the locked screws breakage rates may also be reduced. Therefore, the medullary canals of both the femur and the tibia should be prepared as widely as possible.

With malaligned tibia nonunions and an intact or healed fibula, it may be difficult to insert the guide wire into the correct point because of the sclerotic bone along the margin of the previous nail. It is also very difficult to achieve a correct alignment without opening the nonunion site if the nonunion is tethered by a healed or intact fibula. Therefore, in tibial nonunions with angulation exceeding 5° or a rotational deformity of > 10°, a fibulotomy can be done to facilitate correction of the malalignment.

In conclusion, exchange nailing to treat aseptic

tibial shaft nonunions can achieve high success rates. It may be considered the treatment of choice for all indicated cases. A fibulotomy showed no significant influence on the success rate of treatment in this study, and it can normally be performed to correct tibial malalignment, whenever fixation stability by exchange nailing is anticipated.

## REFERENCES

1. Clifford RP, Beauchamp CG, Kellam JF, Webb JK, Tile M. Plate fixation of open fractures of the tibia. *J Bone Joint Surg [Br]* 1988;70:644-8.
2. Henley MB. Intramedullary devices for tibial fracture stabilization. *Clin Orthop* 1989;240:87-96.
3. Morandi M, Zembo MM, Ciotti M. Infected tibial pseudarthrosis. A 2-year follow-up on patients treated by the Ilizarov technique. *Orthopedics* 1989;12:497-508.
4. Falez F, Moreschini O. The functional brace in the treatment of delayed union and non-union. *Ital J Orthop Traumatol* 1988;14:113-9.
5. Johnson KD. Management of malunion and nonunion of the tibia. *Orthop Clin North Am* 1987;18:157-71.
6. Olerud S, Karlstrom G. The spectrum of intramedullary nailing of the tibia. *Clin Orthop* 1986;212:101-12.
7. Bone LB, Johnson KD. Treatment of tibial fractures by reaming and intramedullary nailing. *J Bone Joint Surg [Am]* 1986;68:877-87.
8. Court-Brown CM, Keating JF, Christie J, McQueen MM. Exchange intramedullary nailing. Its use in aseptic tibial nonunion. *J Bone Joint Surg [Br]* 1995;77:407-11.
9. Templeman D, Thomas M, Varecka T, Kyle R. Exchange reamed intramedullary nailing for delayed union and nonunion of the tibia. *Clin Orthop* 1995;315:169-75.
10. Wu CC, Shih CH, Chen WJ, Tai CL. High success rate with exchange nailing to treat a tibial shaft aseptic nonunion. *J Orthop Trauma* 1999;13:33-8.
11. Zelle BA, Gruen S, Klatt B, Haemmerle MJ, Rosenblum WJ, Prayson MJ. Exchange reamed nailing for aseptic nonunion of the tibia. *J Trauma* 2004;57:1053-9.
12. Gustilo RB, Anderson JTT. Prevention of infection in the treatment of one thousand and twenty-five open fractures of long bones with retrospective and prospective analysis. *J Bone Joint Surg [Am]* 1976;58:453-8.
13. Wu CC, Chen WJ. Tibial lengthening: technique for speedy lengthening by external fixation and secondary internal fixation. *J Trauma* 2003;54:1159-65.
14. Weber BG, Brunner C. The treatment of nonunions without electrical stimulation. *Clin Orthop* 1981;161:24-32.
15. LaVelle DG. Delayed union and nonunion of fractures. In: Canale ST, ed. *Campbell's Operative Orthopedics*. 10<sup>th</sup> ed. Vol. 2. Philadelphia, PA: Mosby, 2003:3125-65.
16. Nolte PA, van der Krans A, Patka P, Janssen IM, Ryaby JP, Albers GH. Low-intensity pulsed ultrasound in the

- treatment of nonunions. *J Trauma* 2001;51:693-702.
17. de Haas WG, Beaupre A, Cameron H, English F. The Canadian experience with pulsed magnetic fields in the treatment of ununited tibial fractures *Clin Orthop* 1986;208:55-8.
  18. Wang CJ, Chen HS, Chen CE, Yang KD. Treatment of nonunions of long bone fractures with shock waves. *Clin Orthop* 2001;387:95-101.
  19. DeLee JC, Heckman JD, Lewis AG. Partial fibulectomy for ununited fractures of the tibia. *J Bone Joint Surg [Am]* 1981;63:1390-5.
  20. Helfet DL, Jupiter JB, Gasser S. Indirect reduction and tension-band plating of tibial non-union with deformity. *J Bone Joint Surg [Am]* 1992;74:1286-97.
  21. Ueng SW, Liu HT, Wang IC. Augmentation plate fixation for the management of tibial nonunion after intramedullary nailing. *J Trauma* 2002;53:588-92.
  22. Reckling FW, Waters CH III. Treatment of non-unions of fractures of the tibial diaphysis by posterolateral cortical cancellous bone-grafting. *J Bone Joint Surg [Am]* 1980;62:936-41.
  23. Menon DK, Dougall TW, Pool RD, Simonis RB. Augmentative Ilizarov external fixation after failure of diaphyseal union with intramedullary nailing. *J Orthop Trauma* 2002;16:491-7.
  24. Henley MB. Fractures of the femoral shaft and subtrochanteric region. In: Brinker MR, ed. *Review of Orthopedic Trauma*. Philadelphia, PA: WB Saunders, 2001:67-75.
  25. Ricci WM. Femur: trauma. In: Vaccaro AR, ed. *Orthopedic Knowledge Update 8*. Vol. 2. Rosemont, IL:2005:425-31.
  26. Weresh MJ, Hakanson R, Stover MD, Sims SH, Kellam JF, Bosse MJ. Failure of exchange reamed intramedullary nails for ununited femoral shaft fractures. *J Orthop Trauma* 2000;14:335-8.
  27. Webb LX, Winquist PA, Hansen ST. Intramedullary nailing and reaming for delayed union or nonunion of the femoral shaft: a report of 105 consecutive cases. *Clin Orthop* 1986;212:133-41.
  28. Kirgis A, Albrecht S. Palsy of the deep peroneal nerve after proximal tibial osteotomy. An anatomical study. *J Bone Joint Surg [Am]* 1992;74:1180-5.
  29. Tencer AF. Biomechanics of fractures and fixation. In: Buchholz RW, Heckman JD. eds. *Rockwood and Green's Fractures in Adult*. 5<sup>th</sup> ed. Vol. 1. Philadelphia, PA: Lippincott Williams & Wilkins, 2001:3-36.
  30. Karlstrom G, Olerud S. Fractures of the tibial shaft: a critical evaluation of treatment alternatives. *Clin Orthop* 1974;105:82-111.
  31. Wu CC, Shih CH. Tibial fracture with or without fibular fracture--clinical studies. *Chang Gung Med J* 1990;13:191-8.
  32. Wu CC, Shih CH. Effect of dynamization of a static interlocking nail on fracture healing. *Can J Surg* 1993;36:302-6.
  33. Tu YK, Lin CH, Su JI, Hsu DT, Chen RJ. Unreamed interlocking nail versus external fixator for open type III tibia fractures. *J Trauma* 1995;39:361-7.
  34. Wu CC, Shih CH. Complicated open fractures of the distal tibia treated by secondary interlocking nailing. *J Trauma* 1993;34:792-6.
  35. Thomas KA, Bearden CM, Gallagher DJ, Hinton MA, Harris MB. Biomechanical analysis of nonreamed tibial intramedullary nailing after simulated transverse fracture and fibulectomy. *Orthopedics* 1997;20:51-7.

## 以置換骨髓內鋼釘去治療脛骨幹的非感染性不癒合： 強調同時做腓骨截骨術的影響

蕭智文 吳基銓 蘇君毅 范國豐 曾益全 李柏成

**背景：**以置換骨髓內鋼釘去治療脛骨幹的非感染性不癒合，被報導有很高的成功率。但是，報導的樣本數都很少；並且同時做腓骨截骨術時的影響，從未被評估過。理論上講，做腓骨截骨術可能有正或反的雙重對抗後果。因此，我們報告自己對此手術的經驗及心得，以作為未來的選擇依據。

**方法：**54 處脛骨幹的非感染性不癒合（期間為 1.2-4.3 年，平均為 2.4 年），以置換骨髓內鋼釘去治療。做此手術的適應症包括：脛骨幹的非感染性不癒合，已裝置了骨髓內鋼釘，脛骨短縮少於 2 公分。腓骨截骨術，做在脛骨不癒合而伴隨不合格的軸線，而必須徒手矯正的情況。我們重新評估置換骨髓內鋼釘的成功率；以及同時做腓骨截骨術，是否會影響成功率。

**結果：**47 處脛骨幹的非感染性不癒合，被複查平均有 3.8 年（期間為 1.1-6.9 年），而全部得到了癒合。因此，癒合率為 100% 而癒合時間平均為 4.7 (3-7.5) 個月。平均癒合時間，在有做截骨與未做截骨的兩組，未有統計學上差異（4.6 對 4.8 個月， $p = 0.61$ ）。在研究中，沒有發生明顯的併發症。

**結論：**置換骨髓內鋼釘是一項卓越的方法，去治療脛骨幹的非感染性不癒合。它可被優先選擇去治療合乎手術適應症的所有患者。當脛骨不癒合的角度過大，同時需要腓骨截骨術以矯正脛骨軸線時，只要骨髓內鋼釘的穩定性夠強，對於骨癒合的時間與成功率似乎沒有不利的影響。

(長庚醫誌 2006;29:283-90)

**關鍵字：**置換骨髓內鋼釘，脛骨，腓骨截骨術。

---

長庚紀念醫院 台北院區 骨科部，長庚大學

受文日期：民國94年8月22日；接受刊載：民國94年12月29日

通訊作者：蕭智文醫師，長庚紀念醫院 骨科部。桃園縣333龜山鄉復興街5號。Tel.: (03)3281200轉2423; Fax: (03)3289582;

E-mail: mr3507@adm.cgmh.org.tw