

## Primary Correction of the Unilateral Cleft Lip Nasal Deformity: Achieving the Excellence

Lun-Jou Lo, MD

Unilateral cleft lip nasal deformity is characterized by prominent asymmetry resulting from distorted and displaced structures. Primary correction of the nasal deformity at the same time of lip repair has gained popularity, aiming at early restoration of the symmetry by lifting the alar cartilage and lengthening the columella on the cleft side. Postoperative relapse is a frequent finding due to the elasticity of the deformed alar cartilage. A variety of strategies have been proposed to treat this type of condition, including preoperative nasoalveolar molding, overcorrection of the nostril and alar cartilage, Tajima method of rhinoplasty, and postoperative nasal splinting. The results have been promising. Long-term assessments need to be performed to determine the final outcomes. (*Chang Gung Med J* 2006;29:262-7)

**Key words:** primary nasal correction, unilateral cleft lip and palate, nasal deformity.

### Deformity of the unilateral cleft lip nose

Unilateral cleft lip and palate occurs when the medial nasal process and maxillary process fail to fuse normally during the 4th to 8th week of development, and failure of subsequent elevation and fusion of the palatal shelves. The circum-oral muscles are disrupted and obliquely oriented along the cleft margins. The nasal floor on the cleft side is lacking or deficient with the cleft of alveolus. Because of unrestraint circum-oral muscles and tongue pressure against the surrounding structures, the development of the lip and nose in association with palatal tissue continues to diverge while in utero. The lip and nasal deformities may reach their maximum upon birth of the baby.

The unilateral cleft lip nasal deformity is dominated by the asymmetry and structural abnormality in the lip, nose, as well as the underlying skeleton (Figs. 1 and 2). The ala on the cleft side is lengthened vertically and lies below the alae on the noncleft side. The lower lateral cartilage is depressed and spread across the cleft. The nasal tip is deviated

toward the noncleft side. The columella on the cleft side is shortened significantly, as compared with the noncleft side. The columella is obliquely oriented, with its base deviated to and located in the noncleft side, away from the midline. Bilateral alar bases are asymmetric, with the cleft side alar base inferiorly and posteriorly displaced. In spite of the nasal deformity, the lower lateral cartilage on the cleft side was found to have no significant differences with that on the noncleft side histologically with regards to the chondrocytes, perichondrium, and cartilage thickness.<sup>(1)</sup> In a study by Park et al, the lower lateral cartilage on each side was examined during the secondary cleft lip nasal reconstruction, and they were found to be the same size and dimension.<sup>(2)</sup> Based on the findings, the nasal cartilage deformity is believed to be resulted from deformation by abnormal forces from the labial cleft, rather than primary cartilage malformation.

There is, however, a defect in the osseous maxilla on the cleft side (Figs. 1 and 2). The piriform in the cleft side is more posteriorly displaced. The

---

From the Craniofacial Center and the Department of Plastic and Reconstructive Surgery, Chang Gung Memorial Hospital, Taipei.  
Received: Nov. 19, 2005; Accepted: Dec. 20, 2005

Correspondence to: Dr. Lun-Jou Lo, Department of Plastic and Reconstructive Surgery, Chang Gung Memorial Hospital, 5, Fushing Street, Gueishan Shiang, Taoyuan, Taiwan 333, R.O.C. Tel.: 886-3-3281200 ext. 2855, Fax: 886-3-3285818, E-mail: lunjoulo@cgmh.org.tw

vomer bone is deviated, and the anterior nasal spine turns toward the noncleft side. A quantitative assessment of the primary cleft lip nasal deformity in a group of 3-month-old patients with unilateral complete cleft lip and palate was performed using 3-dimensional computed tomography (CT).<sup>(3)</sup> The premaxilla was seen to move anteriorly and laterally toward the noncleft side, deforming the overlying nasal and lip structures. The researchers evaluated position changes of the soft tissue and osseous landmarks in the lower nose, where major deformation was observed. The results showed (1) the columella base deviated to the noncleft side by 5 mm, (2) cleft-side alar base displaced more posteriorly by 3.6 mm, (3) noncleft-side alar base deviated further from the midline by 2.8 mm, and (4) cleft-side piriform aperture displaced more posteriorly by 2.1 mm.<sup>(3)</sup>

#### **Primary lip repair without nose correction**

Traditional treatment protocol for correction of the unilateral cleft lip has been to repair the lip without correcting the nose.<sup>(4)</sup> Presurgical orthopedic management may or may not be done to position the two palatal segments and to narrow the alveolar cleft. The lip repair is performed before the infant reaches 6 months of age using the one-stage or two-stage method with an adhesion cheiloplasty ahead of the definitive lip repair. The lip is brought together using layer closure, with emphasis on the symmetry of the lip, vermilion, and Cupid's bow. The nasal floor is reconstructed at the same time. The external nasal deformity is left untouched until the child is preschool age or after a growth spurt. The nasal deformity is improved to some extent after an approximation of the lip, but it remains the same morphological pattern as the presurgical one. At the time of secondary correction, an open type of rhinoplasty is performed with or without the addition of a cartilage graft. The ideas of doing primary lip repair without dissecting the nose are what people believe the nasal development is not hindered, and there is no scarring tissue hampering the secondary nasal reconstruction, and hence have a better outcome. However, the stigmata of the nasal features remain the center of problems.

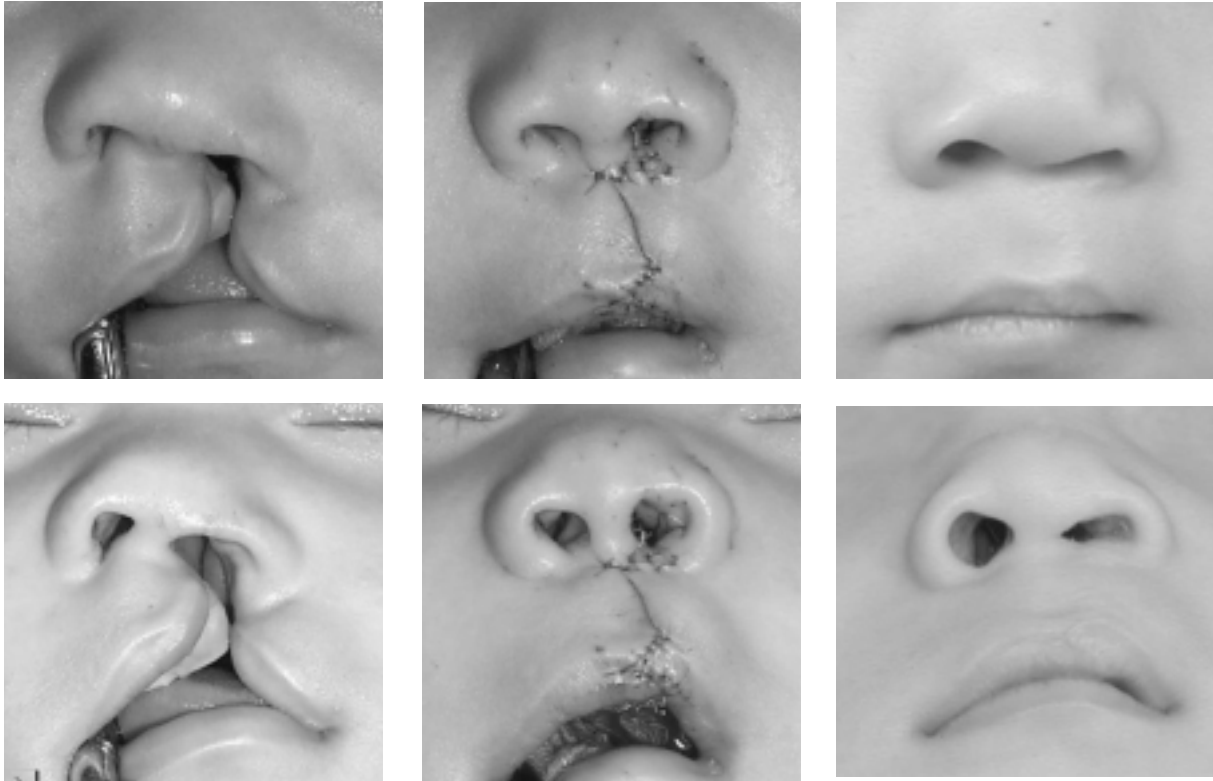
#### **Primary nose correction at the time of lip repair**

The uncorrected nasal deformity has been unac-

ceptable and patients with this condition have been ridiculed, which has generated major psychosocial impacts on the patients and parents. Primary correction of the nasal deformity simultaneously with the definitive lip repair, usually at 3 months of age, has been proposed and has gradually gained wide acceptance. McComb and Salyer are given the credit for popularizing this concept.<sup>(5,6)</sup> The aims of primary rhinoplasty are to achieve normalization of the nose, i.e., symmetry, by lengthening the cleft side columella, elevating the lower lateral cartilage, and shortening or lifting the cleft side hemi-nose. McComb freed the nasal skin from the nasal bone and cartilage from the incision in the upper buccal sulcus. The scissors were also passed up through the columella to free the skin from the medial crus and dome of the alar cartilage. The extent of the nasal dissection was from the alar rim over the nasal tip and up to the nasion on the cleft-side hemi-nose. No intranasal incisions were made. The nasal cartilage, with the attached vestibular lining, was now easily lifted and fixed with one or two mattress suspension sutures tied over the small gauze bolsters at the nasion. One or more lateral mattress transfixion sutures are used to obliterate the dead space and secure the alar lift.<sup>(5)</sup> This type of surgical technique for nose dissection, alar lifting, and stabilization sutures is basically the same as done by the supporters of primary nasal correction,<sup>(6)</sup> while a partial inter-cartilage incision is made to mobilize the alar cartilage and nostril by others.<sup>(7-9)</sup> After long term follow-up periods, it has been found that the nose growth is not interfered with, and the shape can be maintained thus reducing the chance for and magnitude of the secondary nasal reconstruction.<sup>(8,10)</sup>

More harm could probably occur if the primary nasal reconstruction is not done at the time of the lip repair. The cartilage becomes locked and tethered in its abnormal position, with an altered growth of the nasal tip. In this situation, a secondary nasal reconstruction could be more difficult.<sup>(5)</sup>

Although primary nasal correction is performed, this does not mean an excellent nose has been obtained and that with growth there may not be changes that require a secondary correction. A tendency for the lifted alar cartilage to slump within a couple of months was observed (Fig. 1).<sup>(11-13)</sup> Salyer reported that 35% of his patients required early minor secondary corrections.<sup>(8)</sup> Khoo reported 10 to



**Fig. 1** A patient with left complete cleft lip and palate at 3 months of age during lip repair. Note the characteristic nasal deformity (left column). Rotation-advancement cheiloplasty and primary nasal correction was performed (middle column). Same patient during the follow-up examination at 5 years of age, showing good results but some recurrence of the nasal deformity (right column).

20 percent of his patients had moderate nasal deformities after adolescent growth spurts.<sup>(14)</sup> There is room for further improvement of the unilateral cleft lip nasal deformities after the primary correction.

#### **Nasoalveolar molding**

Conventional presurgical orthopedic management has been achieved using a palatal plate, lip taping, and changing sleeping position. The purposes are to facilitate infant feeding, maintain appropriate position of palatal shelves, and induce narrowing of the cleft width, which in turn help to improve the results of the primary cleft lip repair and nasal correction. Grayson and Maull are accredited with the development of the technique of nasoalveolar molding by combining the intraoral molding plate with the nasal stent.<sup>(15)</sup> Using the nasoalveolar molding, the alveolar cleft is approximated and the alar cartilage is lifted together with lengthening of the columella on the cleft side. During the early infant

stage, the cartilage remains soft and pliable, probably because of the estrogen and hyaluronic acid. It has been reported that the technique of nasal correction was facilitated and the outcome was improved using presurgical nasoalveolar molding.<sup>(13,15)</sup> During a 3-year follow-up study, it was found that the nasal asymmetry was significantly improved after nasoalveolar molding, and the deformities were further corrected after primary lip repair and nasal correction.<sup>(15)</sup> However, it was also found that the nasal asymmetry significantly relapsed during the first year, but then maintained stable nasal shape during the following years. Overcorrection of the nasal vertical dimension has been suggested in order to compensate for the relapse of the lower lateral cartilage on the cleft-side.

#### **Overcorrection of the nasal deformity**

The goal of primary correction for the unilateral cleft lip nasal deformity is to mobilize the displaced

alae with its lower lateral cartilage on the cleft side. However, symmetry of the nostrils on the operating table may not last long, and relapse of the cleft-side alar cartilage often occurs within months after the operation. The relapse has been reported to be due to tissue scarring, memory or elasticity of the deformed alar cartilage, or differential growth between the cleft and noncleft sides.<sup>(11-13)</sup> In order to compensate for the alar relapse, overcorrection of the alar cartilage has been applied in the primary nasal reconstruction.<sup>(12,16,17)</sup> Overcorrecting the cleft-side nasal vertical dimension was suggested after a longitudinal observation on the changes of nasal symmetry and growth.<sup>(13)</sup> After overcorrection, the columella length, doom height, and nostril vertical height should all be longer than those on the non-cleft side. In order to achieve the overcorrection, the cleft-side alar base has to be elevated from the piriform, which is the more posteriorly displaced compared with that of non-cleft side. This release can be carried out at the sub-periosteal or supra-periosteal level. The nasal skin is dissected free from the underlying cartilage, and then the elevation and overcorrection is stabilized using various methods, such as traction sutures tied over a bolster at the nasion, bolster suture, internal resorbable splint, alar web mattress suture or transfixion sutures, and the Tajima technique. Outcomes of the nasal overcorrections, however, have not yet been critically evaluated.

#### **Tajima method of nasal correction**

Tajima and Maruyama reported using a reverse U incision on the cleft-side for correction of the secondary cleft lip nasal deformity.<sup>(18)</sup> The U incision was made on the dorsum of the nostril and inside the alae, similar to the nostril shape on the non-cleft side. Subcutaneous undermining between the skin and cartilage was performed to the whole nose. Adequate exposure was obtained and the cartilage, together with vestibular skin and mucosa, were elevated and fixed to the upper lateral cartilage and contralateral lower lateral cartilage by supporting sutures. By doing this technique, the lower lateral cartilage on the cleft side was mobilized higher than the contralateral cartilage, i.e. an overcorrection. The Tajima method of nasal correction has been applied in primary<sup>(16,17,19,20)</sup> as well as secondary<sup>(16,19)</sup> nasal correction for unilateral cleft lip nasal deformities. Byrd reported that the Tajima method was used in 40% of

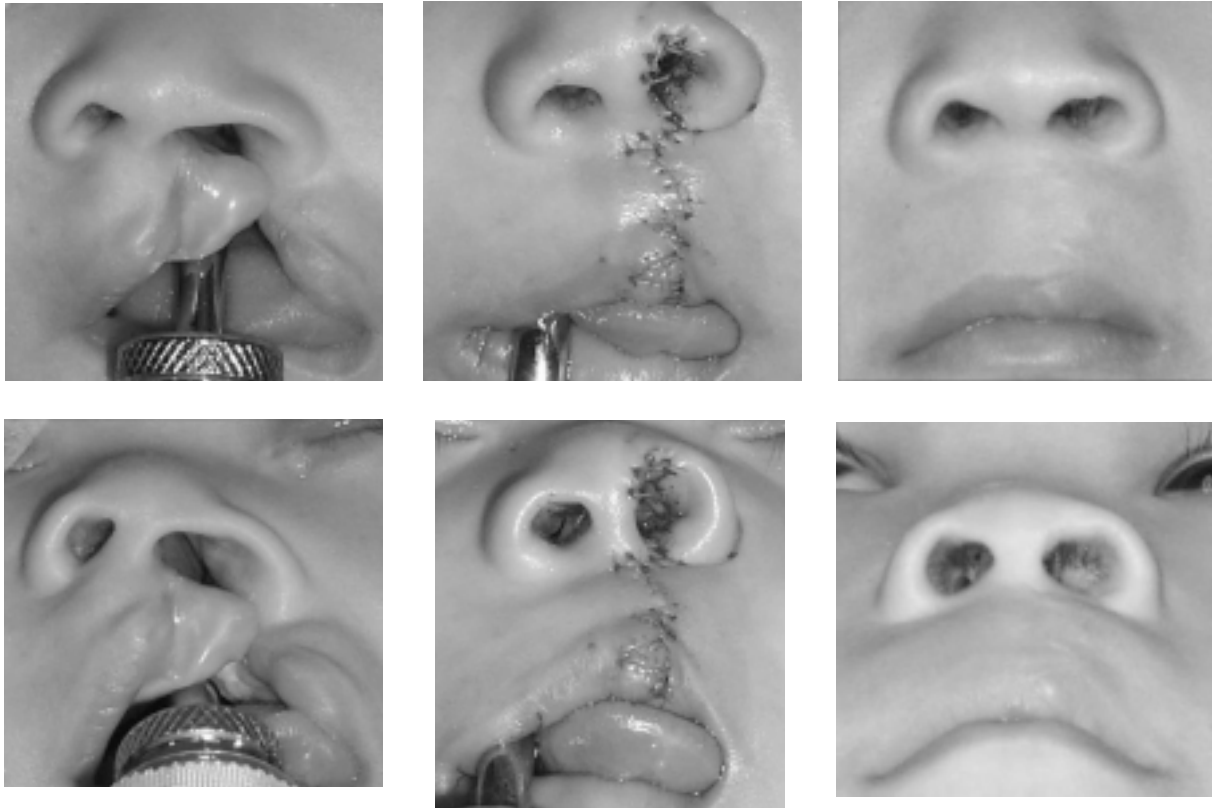
his patients for the primary correction of the unilateral cleft nasal deformity.<sup>(20)</sup> The reverse U incision can be designed higher on the nostril rim for overcorrection of the alar cartilage (Fig. 2). After elevation, the U shape incision line is rotated and sutured inside the nostril and therefore is not seen from the outside.

#### **Use of nasal splinting**

A good method for maintaining nasal shape after correction of the alar cartilage is to use a nasal splint, whether it is an internal or external one. Yeow et al performed a retrospective assessment comparing two groups of patients with or without the use of a postoperative nasal splint.<sup>(11)</sup> Photographic evaluations on the nostril symmetry, alar cartilage slump, alar base level, and columella tilt were carried out. Patients who used the nasal stents after their operations had significantly less residual nasal deformities and better overall appearance. Therefore, it is recommended that all patients undergoing primary correction of complete unilateral cleft deformity use the nasal retainers postoperatively for a period of at least 6 months.<sup>(11)</sup> A resorbable internal splinting has been reported to be a helpful adjunct to the primary correction of the unilateral cleft lip nasal deformity.<sup>(12)</sup> Similarly, two groups of patients with or without use of the internal splint were compared using photogrammetric analysis for alar contours, and the results showed the alar asymmetry was decreased in the splinted group. Another type of external splint using a "hook" at the doom which was suspended upward to the forehead area was reported in a meeting and good results were obtained.

#### **Achieving excellence**

It has been recognized that primary nasal correction for unilateral cleft lip nasal deformities simultaneous with lip repair can significantly improve nasal appearance. The nose surgery does not influence subsequent growth or development of the nose. Presurgical nasoalveolar molding changes the alar cartilage and approximates the alveolar segments, setting a smooth foundation on which the nose can be reconstructed. Overcorrecting the cleft-side nostril and its alar cartilage is believed to produce better symmetry compensating for possible relapse during the postoperative period. The overcorrection can be achieved using the Tajima method of rhinoplasty during the primary correction for unilateral cleft lip



**Fig. 2** A patient with left complete cleft lip and palate at 3 months of age during lip repair (left column). The nasal deformity was the same as in Figure 1. Lip repair was accomplished using the same technique as in Figure 1. Overcorrection and Tajima method were used in the primary nasal correction (middle column). Patient during the follow-up examination at 5 years of age follow-up showing good results with symmetric nostrils (right column).

nasal deformity. Relapse of nasal deformities can be reduced using external or internal nasal splinting. We have been using these techniques and experienced superb results. However, long-term evaluation has yet to be performed to document the outcomes. If excellent results are achieved initially, secondary reconstruction will not be necessary.

## REFERENCES

1. Sadove R, Ladaga L, Magee WP Jr. Cartilaginous histology of the cleft lip nose: proving the extrinsic etiology. *Plast Reconstr Surg* 1988;81:655-61.
2. Park BY, Lew DH, Lee YH. A comparative study of the lateral crus of alar cartilages in unilateral cleft lip nasal deformity. *Plast Reconstr Surg* 1998;101:915-20.
3. Fisher DM, Lo LJ, Chen YR, Noordhoff MS. Three-dimensional computed tomographic analysis of the primary nasal deformity in 3-month-old infants with complete unilateral cleft lip and palate. *Plast Reconstr Surg* 1999;103:1826-34.
4. Millard DR Jr. Earlier correction of the unilateral cleft lip nose. *Plast Reconstr Surg* 1982;70:64-73.
5. McComb H. Primary correction of unilateral cleft lip nasal deformity: a 10-year review. *Plast Reconstr Surg* 1985;75:791-9.
6. Salyer KE. Primary correction of the unilateral cleft lip nose: a 15-year experience. *Plast Reconstr Surg* 1986;77:558-68.
7. Noordhoff MS, Chen Y, Chen K, Hong KF, Lo LJ. The surgical technique for the complete unilateral cleft lip-nasal deformity. *Oper Techn Plast Reconstr Surg* 1995;2:167-74.
8. Salyer KE, Genecov ER, Genecov DG. Unilateral cleft lip-nose repair: a 33-year experience. *J Craniofac Surg* 2003;14:549-58.
9. Cronin ED, Rafols FJ, Shayani P, Al-Haj I. Primary cleft nasal repair: the composite V-Y flap with extended mucosal tab. *Ann Plast Surg* 2004;53:102-8.
10. McComb HK, Coghlan BA. Primary repair of the unilat-

- eral cleft lip nose: completion of a longitudinal study. *Cleft Palate Craniofac J* 1996;33:23-30.
11. Yeow VK, Chen PK, Chen YR, Noordhoff SM. The use of nasal splints in the primary management of unilateral cleft lip nasal deformity. *Plast Reconstr Surg* 1999;103:1347-54.
  12. Wong GB, Burvin R, Mulliken JB. Resorbable internal splint: an adjunct to primary correction of unilateral cleft lip-nasal deformity. *Plast Reconstr Surg* 2002;110:385-91.
  13. Liou EJ, Subramanian M, Chen PK, Huang CS. The progressive changes of nasal symmetry and growth after nasoalveolar molding: a three-year follow-up study. *Plast Reconstr Surg* 2004;114:858-64.
  14. Boo-Chai K. Primary repair of the unilateral cleft lip nose in the Oriental: a 20-year follow-up. *Plast Reconstr Surg* 1987;80:185-94.
  15. Grayson BH, Maull D. Nasoalveolar molding for infants born with clefts of the lip, alveolus, and palate. *Clin Plast Surg* 2004;31:149-58.
  16. Nakajima T, Yoshimura Y, Kami T. Refinement of the "reverse-U" incision for the repair of cleft lip nose deformity. *Br J Plast Surg* 1986;39:345-51.
  17. Kim SK, Cha BH, Lee KC, Park JM. Primary correction of unilateral cleft lip nasal deformity in Asian patients: anthropometric evaluation. *Plast Reconstr Surg* 2004;114:1373-81.
  18. Tajima S, Maruyama M. Reverse-U incision for secondary repair of cleft lip nose. *Plast Reconstr Surg* 1977;60:256-61.
  19. Kernahan DA, Bauer BS, Harris GD. Experience with the Tajima procedure in primary and secondary repair in unilateral cleft lip nasal deformity. *Plast Reconstr Surg* 1980;66:46-53.
  20. Byrd HS, Salomon J. Primary correction of the unilateral cleft lip nasal deformity. *Plast Reconstr Surg* 2000;106:1276-86.