

Surgical Treatment of Spinal Pseudoarthrosis in Ankylosing Spondylitis

Lih-Huei Chen, MD; Feng-Chen Kao¹, MD; Chi-Chien Niu, MD; Po-Liang Lai, MD; Tsai-Sheng Fu, MD; Wen-Jer Chen, MD

Background: In ankylosing spondylitis (AS), the spine with osteoporotic changes is fragile and vulnerable to trauma. Patients may develop spinal pseudoarthrosis (SP), whose clinical features are usually misdiagnosed as a tuberculous infection. This study reports our experience with surgical treatment for SP in AS.

Methods: Eight patients with AS and SP at the thoracolumbar area were treated surgically and followed-up for at least 3 years. All had persistent back pain and progressive kyphosis. One patient had neurologic deficits preoperatively. Anterior debridement and interbody fusion followed by posterior stabilization were performed in all patients. A posterior corrective osteotomy was additionally done in 3 patients whose kyphotic angle exceeded 45°.

Results: All patients with persistent back pain obtained significant pain relief postoperatively. On a visual analogue scale, there was an average improvement of 43 points on the clinical scores. The patient with neurologic deficits showed improvement after the operation. Solid bony fusion was achieved in an average of 7.5 months, and correction of the kyphotic angle averaged 18.6°.

Conclusions: Spinal pseudoarthrosis should be considered in patients with AS, and must be differentiated from tuberculous and other infections. The results of this study show that pain relief and correction of the kyphotic deformity can be achieved by surgical treatment for ankylosing spondylitis complicated with pseudoarthrosis.

(Chang Gung Med J 2005;28:621-8)

Key words: ankylosing spondylitis, pseudoarthrosis, surgery.

In ankylosing spondylitis (AS), the spine with osteoporotic changes is fragile and vulnerable to trauma.^(1,2) Initially, injuries often pass unrecognized, and the patient may later develop a “destructive vertebral lesion” causing localized back pain and neurologic abnormalities.

The terms spondylodiscitis, Andersson lesion, destructive discovertebral lesion, and spinal

pseudoarthrosis (SP) are used to describe similar conditions, which was first described by Andersson in 1937.⁽¹⁾ Radiographic changes of SP occur in the discovertebral area and resemble those of spinal tuberculous spondylitis. Sometimes, SP in AS may be misdiagnosed as a tuberculous infection and treated with antituberculous chemotherapy.^(2,3)

Several methods of treatment for pseudoarthro-

From the Department of Orthopedic Surgery, Chang Gung Memorial Hospital, Taipei; ¹Department of Orthopedic Surgery, E-DA Hospital, Kaohsiung.

Received: Feb. 21, 2005; Accepted: Jul. 18, 2005

Address for reprints: Dr. Wen-Jer Chen, Department of Orthopedic Surgery, Chang Gung Memorial Hospital, No. 5, Fushing St., Gueishan Shiang, Taoyuan, Taiwan 333, R.O.C. Tel: 886-3-3281200 ext. 2163; Fax: 886-3-3278113; E-mail: chenwenj@adm.cgmh.org.tw

sis have been advocated, including immobilization with braces,^(2,4-6) posterior fusion,^(2,3) anterior fusion,^(2,3,6,7) and combined anterior and posterior procedures.^(2,5) However progressive kyphosis still occurs after these treatments. The present study reports the surgical results of combined anterior fusion and posterior stabilization for SP in AS.

METHODS

From 1991 to 2001, 8 patients with SP were treated by anterior fusion combined with posterior stabilization. There were 7 males and 1 female, with an average age of 49 (29~73) years. The mean follow-up period was 7.4 (range, 3~11) years. Indications for surgical treatment included intense focal back pain and a progressive kyphotic deformity after conservative treatment.

HLA B27 was positive in 7 patients and negative in 1. The white blood cell (WBC) count at the time of diagnosis ranged from 5000 to 14,700/mm³. The erythrocyte sedimentation rate (ESR) averaged 50 (range, 12~89) mm/h. Table 1 presents the demographic data and blood chemistry results of the patients. Bone scans were performed in 6 patients, and all revealed active localized spinal lesions.

Most lesions were near the thoracolumbar junction with the highest at T8~9 and the lowest at L2~3. All of the radiographs displayed typical changes in establishing AS, including fusion of the sacroiliac joints, and continuous syndesmophyte formation through the thoracic and lumbar spine (bamboo spine). Radiographic study of the lesion site showed

the irregular disappearance of the vertebral end plate on both the upper and the lower borders of the disc. The kyphosis was measured using Cobb's method on a lateral radiograph, and the kyphotic angle of the lesion site averaged 41.2° (range, 10°~75°) preoperatively (Fig. 1).

Magnetic resonance imaging (MRI) was performed on all patients, and revealed reduced signal intensity on T1-weighted images and increased signal intensity on T2-weighted images at the lesion site. Furthermore, widening of the disc space or the cavity-like area was also noted.

Surgical technique

All patients were operated on under general anesthesia with endotracheal intubation. Patients were placed in the right lateral decubitus position. The lesions were thoroughly debrided, and all necrotic tissue was removed. All surgical specimens were sent for pathologic examination and were cultured for bacteria and tuberculosis.

A surgical assistant pushed the back anteriorly to correct the kyphotic spine, and the length of the bone graft was determined. A sufficiently long anterior iliac tricortical bone graft was then procured. Again, the kyphotic spine was reduced by the surgical assistant, and the bone graft was packed between the healthy vertebral bodies for support. The anterior procedure was followed by second-stage posterior fusion and instrumentation. The instrumentation technique consisted of bilateral segmental instrumentation. At a minimum, 4 points of fixation were achieved bilaterally. The range of fixation depended

Table 1. Data of Patients

Case	Age (year)	Gender	Duration of back pain (years)	Involved segment	WBC (cells/mm ³)	ESR (mm/h)	CRP (mg/dl)	Follow-up (years)
1	45	M	2	T11~12	5900	35	< 5	4
2	54	M	8	T8~9	6400	42	29	3
3	40	F	2	T11~12	14,700	89	36	11
4	73	M	3	L2~3	7500	20	< 5	10
5	58	M	3	T12~L1	10,100	26	22.8	10
6	53	M	10	T10~11	5000	14	< 5	9
7	42	M	10	L2~3	6600	12	< 5	8
8	29	M	3	T11~T12	8000	60	28	4

Abbreviations: WBC: white blood cells; ESR: erythrocyte sedimentation rate; CRP: C-reactive protein.

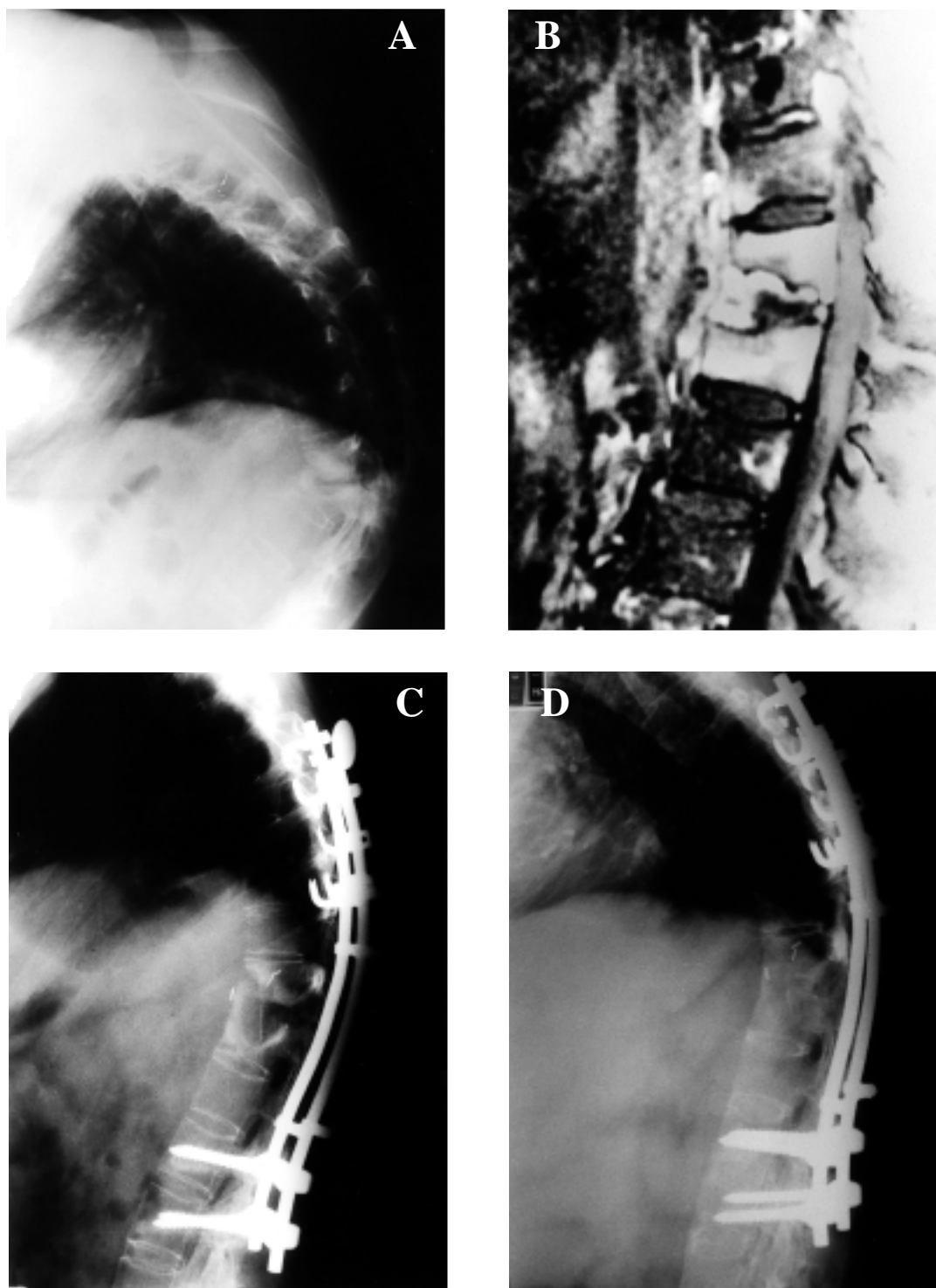


Fig. 1 Case 8. (A) Preoperative lateral view; (B) MRI (T1-weighted image with enhancement) showing high signal intensity at the lesion site; (C) postoperatively, lateral view; (D) latest follow-up, lateral view.

on the kyphotic severity, usually ending 2 vertebrae cephalad and caudal to the lesion site. Short fixation in the lumbar and thoracolumbar region was sometimes performed with pedicle screws; for longer ranges, hook fixation was preferred particularly in the upper thoracic levels. A corrective osteotomy by shortening the posterior structures were performed in 3 patients with kyphotic angles exceeding 45°. There were no perioperative complications. The median duration of the operation was 4.8 (range, 3.8~6.4) h, and the median blood loss was 3500 (range, 2200~8000) ml. The operative time and blood loss depended on the number of segments stabilized.

Patients were restrained using a thoracolumbar brace for 3 months after the operation. At follow-up, plain radiographs, including anteroposterior and lateral projections, were obtained at 3, 6, 9, and 12 months, and annually thereafter. Neurologic recovery and back pain improvement were clinically evaluated. Surgical results were assessed by asking patients to quantify their degree of pain on a Huckisson visual analogue scale (VAS; with 0 mm indicating no pain and 100 mm the worst pain). An initial VAS score was taken on enrollment. Subsequent VAS scores were recorded at each follow-up. The group's VAS values were compared using the Wilcoxon signed rank test. Patients were also asked to compare their ambulatory status, the ability to sleep comfortably, and analgesic requirements before and after surgery. After surgery, they selected 1 of 3 possible responses for each including significantly improved, approximately the same, or worse. As an overall assessment of well being, patients were asked whether they thought that the procedure had significantly enhanced their quality of life.

RESULTS

Pathology

The pathology revealed that the disc was replaced by fibrous tissue and/or fibrocartilage. No caseous necrosis or Langhans' giant cells were observed. All patients showed negative results for gram-positive, gram-negative, and tuberculosis cultures.

Correction of the kyphosis

All patients had immediate postoperative correction of the kyphosis. The postoperative Cobb's

angle of fused segments averaged 22.6° (range, lordosis of 7° to kyphosis of 50°). The average correction of the kyphotic angle was 18.6° (range, 15°~30°). The final kyphotic angle of the fused segment averaged 29.5° (range, 5°~60°). The loss of correction averaged 6.9° (range, 0°~12°). In the 3 patients who received a corrective osteotomy, the patients felt much improvement in their posture. Tables 2 and 3 show the operative level and angle correction before and after the operation.

Clinical results

Patients were asked to quantify their degree of pain on a Huckisson's visual analogue scale (VAS;

Table 2. Operative Data of Patients

Case	Operative level		Polysegmental osteotomy	Interval for solid fusion* (months)
	Anterior	Posterior		
1	T11-T12	T7~L3	+	6
2	T8-T9	T5~T12	-	6
3	T11-T12	T7~L3	+	9
4	L2-L3	L1~L4	-	6
5	T12-L1	T7~L3	-	6
6	T10-T11	T10~L4	+	12
7	L2-L3	L1~L4	-	6
8	T11-T12	T7~L3	-	9

* Interval for solid fusion of the anterior bone graft.

Table 3. Degree of Kyphotic Angle of Patients

Case	Preoperative angle (°)	Postoperative angle (°)*	Correction (°)	Final angle (°)	Loss of correction (°)
1	46	30	16	32	2
2	35	17	18	25	8
3	75	45	30	52	7
4	10	-7	17	5	12
5	36	21	15	30	9
6	66	50	16	60	10
7	20	5	15	12	7
8	42	20	22	20	0
Average	41.3	22.6	18.6	29.5	6.9

* Postoperative degree of lordosis indicated by a minus sign (-).

with 0 mm indicating no pain and 100 mm the worst pain before surgery and at the final follow-up. The pain score decreased from 67.75 ± 8.0 mm before surgery to 23.50 ± 5.29 mm at the final follow-up. The reduction in pain from preoperatively to the final follow-up was statistically significant ($p = 0.0078$). The condition of 1 patient with neurologic deficits also improved after the operation. Fusion was judged radiographically by obliteration of the interface between the bone graft and vertebral body, and the appearance of bony trabeculae the fusion side. Solid bony fusion was achieved in an average of 7.5 (range, 6-12) months. In the meantime, bone graft dislodgement was found in only 1 patient. This patient was treated conservatively by bracing, and had no other obvious clinical symptoms. Seven patients (87.5%) were able to return to their pre-injury activity level and had achieved a better quality of life at the final follow-up.

DISCUSSION

Spinal pseudoarthrosis (SP) generally develops over many months or years and characteristically involves a single vertebral level.⁽²⁾ Cawley et al. classified the destructive vertebral lesion in ankylosing spondylitis (AS) into 3 types according to whether the lesions are localized or extensive.⁽⁴⁾ Type I is a localized central discovertebral lesion, type II is a localized peripheral discovertebral lesion, and type III is a combination of types I and II, in which the most-extensive lesion is through the discovertebral junction. All lesions in the present series were type III.

In 1988, Fang described 3 possible causes of pseudoarthrosis.⁽²⁾ First, the segment may escape fusion while other levels become ossified. The process of spinal ossification in AS is multifocal and discontinuous. Second, an acute fracture may occur through an already fused segment. Third, the mechanics of a stiff kyphotic spine may cause high stress, especially near the thoracolumbar junction, and the repeated stress may cause a fatigue fracture, as in a stress fracture of the long bone. Inflammation and mechanical factors can cause similar destructive lesions.^(7,8)

Most patients complain of localized pain with a rather acute onset, increasing with movement and decreasing after rest. The clinical diagnosis of spinal

pseudoarthrosis is not easy. Previous studies found that plain radiographs were of limited value. Such radiographs commonly arouse suspicion of an infection or a neoplastic process.^(2,5,9-11) Plain radiographic images of discovertebral destruction are often mistakenly diagnosed as infective lesions, especially in Asian patients, in whom tuberculosis is not uncommon.

Laboratory findings sometimes reveal an inflammatory process, indicating the strong possibility of an infective origin. In the present series, leukocytosis was found in 2 patients. The concentration of serum C-reactive protein was elevated in cases 3, 5, and 8, while the ESR levels were elevated in cases 3 and 8. Although ESR levels are often raised, as expected in AS, no evidence is available of a general increase in disease activity concomitant with a change in symptoms.^(2,4,5,8,12)

The characteristic radiological appearance and evolution of pseudoarthrosis, and its frequent association with fractures of the posterior elements, facilitate the differential diagnosis. However, Chan et al. found difficulties in interpreting changes in posterior elements on plain x-ray or tomograms, owing to the abnormal spinal curvature and the superimposition of heavily ossified spinal ligaments.⁽¹³⁾ These difficulties can be overcome by using computed tomography. Magnetic resonance imaging (MRI) can be further useful in the early detection of pseudoarthrosis, and in revealing the precise extent of lesion involvement.⁽¹⁴⁾ Shih et al. described 2 patterns of fracture or pseudoarthrosis, namely: low signal on T1- and high signal on T2-weighted images, and low signals on both T1- and T2-weighted images. Differentiating spinal pseudoarthrosis from infectious spondylitis is important.⁽⁶⁾ Although these 2 disease entities differ in etiology, they both occur in the discovertebral junction of the spine. Progressive osteolysis of the anterior elements with variable sclerosis and the presence of osteolytes are found in pseudoarthrosis. The signal intensity of the ossified anterior longitudinal ligament (ALL) is thicker and darker in AS. The initial presentation of infection of the spine is the introduction of septic emboli into the metaphyseal artery at the vertebral end plate. The infection subsequently spreads along the subligamentous area, in a process known as subligamentous infiltration. The posterior elements are rarely involved in the infection. Fracture extension into the posterior elements is

quite common in AS. Thus, the involvement of the posterior element and the different morphology of the ALL with its surrounding soft tissue are important distinctions in differentiating pseudoarthrosis from infections. In the present series, all cases were in the advanced stage and were associated with bone destruction.

Most cases of SP are painful and do not respond to conservative treatment. Healing occurs only rarely by plaster immobilization or with no treatment.⁽²⁾ Biomechanically, destruction of the vertebral body induces kyphotic deformities, significantly increasing compressive torque and accelerating the collapse of the vertebral body.⁽¹⁵⁾ Patients always have thoracolumbar kyphosis. We consider surgical treatment to be necessary to restore spinal stability and to correct the kyphosis. Since tissue proof of pseudoarthrosis is important, especially where an infectious origin is strongly suspected, the pathology of the present series showed that the disc was replaced by fibrous tissue and/or fibrocartilage, and some necrotic bone and cartilage were also found. This finding is similar to that described by Wu et al.⁽⁷⁾

An anterior strut graft is important in reducing the stresses that act on the internal fixation, since it provides cortical contact and buttresses the fixation against flexion moments.⁽¹⁶⁾ Fang reported anterior spinal fusion to be successful in preventing the progression of kyphosis and in correcting preexisting kyphosis.⁽²⁾ In this study, the intervertebral space was opened after the pseudoarthrosis was excised and the anterior column was released. Then, the back was pushed anteriorly to correct the kyphosis, and a bone graft of optimal length was packed between the healthy vertebral bodies. Furthermore, a posterior osteotomy was considered to correct the severe kyphotic deformities. In the present series, the average correction of the kyphotic angle was 18.6°, and loss of correction averaged 6.9°. In previous series⁽¹⁷⁻¹⁹⁾ in which lumbar osteotomies were performed for kyphosis in AS, the degree of correction initially ranged from 31° to 48°. The average loss of correction was 4° (range, 0°~25°) after 1 or more years.⁽¹⁹⁾ We think that a transpedicular wedge osteotomy may be indicated in cases of severe kyphosis. The average correction per segment is around 35°.⁽²⁰⁻²²⁾

In conclusion, spinal pseudoarthrosis should be diagnosed in patients with an ankylosed spine, and this must be differentiated from tuberculous and

other infections. The results of this study show that pain relief and correction of the kyphotic deformity can be achieved with surgical treatment for spinal pseudoarthrosis in ankylosing spondylitis.

REFERENCES

1. Andersson O. Röntgenbilder vid spondylarthritis ankylopoetica. *Nord Med* 1937;14:2000.
2. Fang D, Leong JC, Ho EK, Chan EL, Chow SP. Spinal pseudoarthrosis in ankylosing spondylitis. Clinicopathological correlation and results of anterior spinal fusion. *J Bone Joint Surg [Br]* 1988;70:443-7.
3. Kanefield DG, Mullins BP, Freehafer AA, Furey FG, Horenstein S, Chamberlin WB. Destructive lesions of the spine in rheumatoid ankylosing spondylitis. *J Bone Joint Surg [Am]* 1969;51:1369-75.
4. Cawley MI, Chalmers TM, Kellgren JH, Ball J. Destructive lesions of vertebral bodies in ankylosing spondylitis. *Ann Rheum Dis* 1972;31:345-8.
5. Rasker JJ, Prevo RL, Lanting PJ. Spondylodiscitis in ankylosing spondylitis, inflammation or trauma: a description of six cases. *Scand J Rheumatol* 1996;25:52-7.
6. Shih TT, Chen PQ, Li YW, Hsu Cr. Spinal fracture and pseudoarthrosis complicating ankylosing spondylitis: MRI manifestation and clinical significance. *J Comput Assist Tomogr* 2001;25:164-70.
7. Wu PC, Fang D, Ho EK. The pathogenesis of extensive discovertebral destruction in ankylosing spondylitis. *Clin Orthop* 1988;230:154-61.
8. Rivelis M, Freiburger RH. Vertebral destruction at unfused segments in late ankylosing spondylitis. *Radiology* 1969;93:251-6.
9. Dihlmann W, Delling G. Disco-vertebral destructive lesions (so-called Andersson lesions) associated with ankylosing spondylitis. *Skelet Radiol* 1987;3:10-6.
10. Peh WC, Ho TK, Chan FL. Pseudoarthrosis complicating ankylosing spondylitis—appearances on magnetic resonance imaging. *Clin Radiol* 1993;47:359-61.
11. Pettersson T, Laasonen L, Leirisalo-Repo M, Terrahartala P. Spinal pseudoarthrosis complicating ankylosing spondylitis: a report of two patients. *Br J Rheumatol* 1996;35(12):1319-23.
12. Pastershank SP, Resnick D. Pseudoarthrosis in ankylosing spondylitis. *J Can Assoc Radiol* 1980;31:234-5.
13. Chan FL, Ho EK, Chau EM. Spinal pseudoarthrosis complicating ankylosing spondylitis: comparison of CT and conventional tomography. *Am J Roentgenol* 1988;150:611-4.
14. Peh WC, Luk DK. Pseudoarthrosis in ankylosing spondylitis. *Ann Rheum Dis* 1994;53:206-10.
15. Park WM, Spencer DG, McCall IW. The detection of spinal pseudoarthrosis in ankylosing spondylitis. *Br J Radiol* 1981;54:467-72.

16. Krag MH. Biomechanics of thoracolumbar spinal fixation -- a review. *Spine* 1991;16:S84-99.
17. Briggs H, Keats S, Schlesinger PT. Wedge osteotomy of the spine with bilateral intervertebral foraminotomy. *J Bone Joint Surg [Am]* 1947;29:1075-82.
18. Law WA. Lumbar spinal osteotomy. *J Bone Joint Surg [Br]* 1959;41:270-8.
19. Bradford DS, Schumacher WL, Lonstein JE, Winter RB. Ankylosing spondylitis: experience in surgical management of 21 patients. *Spine* 1987;12:238-43.
20. Chen IH, Chien JT, Yu TC. Transpedicular wedge osteotomy for correction of thoracolumbar kyphosis in ankylosing spondylitis: experience with 78 patients. *Spine* 2001;26:E354-60.
21. Chen PQ. Correction of kyphotic deformity in ankylosing spondylitis using multiple spinal osteotomy and Zielke's VDS instruments. *J Formos Med Assoc* 1988;87:692-8.
22. Thomassen E. Vertebral osteotomy for correction of kyphosis in ankylosing spondylitis. *Clin Orthop* 1985;194:142-52.

僵直性脊椎炎合併骨折癒合不全的外科療法

陳力輝 高逢辰¹ 牛自健 賴伯亮 傅再生 陳文哲

背景：僵直性脊椎炎具有僵直及骨鬆的特性且容易受傷，一旦發生骨折可能引起癒合不全，這種病灶可能被誤認為結核感染，本研究在於探討外科手術的臨床結果。

方法：共收集 8 位僵直性脊椎炎合併骨折癒合不全發生在胸腰椎，經手術治療後並追蹤至少三年的臨床結果，所有病人皆有持續背痛及漸行性駝背，一位病人術前合併有神經缺失情形，所有病人皆經由前位擴創術及骨融合術加上後位內固定治療，有三位因駝背角度大於 45 度需再同時作後位切骨術以矯正嚴重駝背。

結果：所有病人皆有明顯疼痛減輕，一位神經缺失的個案，其神經功能也在術後獲得改善，骨融合平均在 7.5 個月達成，駝背角度改善平均為 18.6 度。

結論：這種僵直性脊椎炎骨折的癒合不良，必需和脊椎感染作鑑別診斷，前位手術可得到病理組織的鑑定，前位結構的支持，加上後位必要的內固定通常可得到良好的成果。

(長庚醫誌 2005;28:621-8)

關鍵字：僵直性脊椎炎，骨折癒合不全，手術。

長庚紀念醫院 台北院區 骨科；¹義大醫院 骨科

受文日期：民國94年2月21日；接受刊載：民國94年7月18日

索取抽印本處：陳文哲醫師，長庚紀念醫院 骨科。桃園縣333龜山鄉復興街5號。Tel.: (03)3281200 ext 2163; Fax: (03)3278113; E-mail: chenwenj@adm.cgmh.org.tw