

## Chorioretinal Folds Associated with a Meningioma

Ling Yeung, MD; Chi-Chun Lai, MD; Tun-Lu Chen, MD; Wei-Chi Wu, MD, PHD

Chorioretinal folds are a rare presentation of a meningioma. We report a case of a meningioma with chorioretinal folds as its initial presentation. A 39-year-old female patient complained of progressive blurring of the right eye. A fundus examination of the right eye revealed chorioretinal folds. Magnetic resonance imaging found a tumor mass involving the right orbit and right anterior middle cranial fossa. An echo-guided biopsy confirmed the meningioma. She received surgical excision of the meningioma, and her visual acuity was stationary at 12/20 after 15 months of follow-up. We review the etiologies of chorioretinal folds and elucidate the strategies for dealing with them. Certain underlying diseases associated with chorioretinal folds are lethal and require prompt management. Ophthalmologists should evaluate these patients carefully in a stepwise manner. (*Chang Gung Med J* 2005;28:575-80)

**Key words:** chorioretinal folds, meningioma, orbital tumor.

Chorioretinal folds are a rare condition that results from undulations in the choriocapillaris, Bruch's membrane, retinal pigment epithelium, and sensory retina. They were first described by Nettleship in 1884 in a patient with optic atrophy following papilledema secondary to an intracranial mass.<sup>(1)</sup> Differential diagnoses of chorioretinal folds include age-related macular degeneration, posterior scleritis, hyperopia, hypotony, papillitis, an intraorbital- or intracranial-occupying mass, and increased intracranial pressure.<sup>(2)</sup> Certain of these diseases are lethal and require prompt management. We report a case of a meningioma with the rare presentation of chorioretinal folds. We also review the etiologies of chorioretinal folds and discuss the strategies for dealing with them.

### CASE REPORT

A 39-year-old woman visited our ophthalmologic clinic because of progressive blurring in her right

eye for 5 months. She denied any eye pain or diplopia. She had previously been in good health. No trauma history could be traced. An ophthalmologic examination revealed that her best-corrected visual acuities were 10/20 in the right eye and 20/20 in the left eye. Intraocular pressures of both eyes were within a normal range. There was mild proptosis and hypertropia of the right eye. The anterior segment was unremarkable in both eyes. There was no afferent pupillary defect. Ophthalmoscopy disclosed multiple fine chorioretinal folds over the right fundus (Fig. 1A). The folds were horizontally orientated and emanated from the optic disc. There were no papilledema, drusen, retinal detachment, or other pathological changes. The posterior segment of the left eye was unremarkable. A physical examination revealed a palpable soft mass under the skin of the right temporal periorbital area. However, the patient had neglected it because this subcutaneous mass was asymptomatic and had grown in a slow manner over the past 6 months. It was flat, round-shaped, and

---

From the Department of Ophthalmology, Chang Gung Memorial Hospital, Taipei.

Received: Apr. 13, 2004; Accepted: Jul. 12, 2004

Address for reprints: Dr. Wei-Chi Wu, Department of Ophthalmology, Chang Gung Memorial Hospital, No. 5, Fushing St., Gueishan Shiang, Taoyuan, Taiwan 333, R.O.C. Tel.: 886-3-3281200 ext. 8666; Fax: 886-3-3287798; E-mail: weichi@cgmh.org.tw

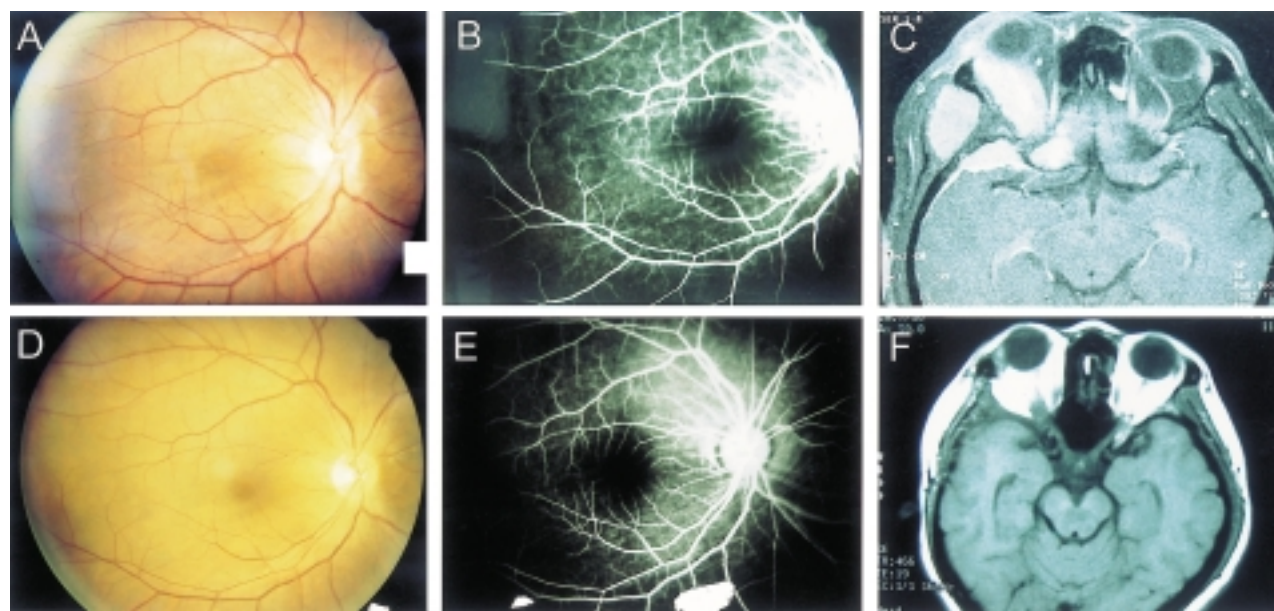
about 5 cm in diameter with an ill-defined margin. No open wound, local heat, or erythema was noted around the mass or periorbital area. No lymphadenopathy was found in the head and neck region.

Fluorescein angiography demonstrated typical alternating dark and light bands of the chorioretinal folds. The bands appeared from the early phase throughout all phases (Fig. 1B). The fluorescein angiography was otherwise normal. Magnetic resonance imaging (MRI) of the head depicted a soft-tissue mass lesion in the temporal portion of the right orbit (Fig. 1C). It involved the right temporal scalp, lateral and superior aspects of the right orbit, right orbital apex, and right anterior middle cranial fossa. It had also invaded the adjacent sphenoid bone, temporal bone, and orbital wall. Whole-body bone scans revealed a focal area of increased uptake of radioactivity involving the right periorbital area. An echo-guided biopsy of the right periorbital mass was done, and the pathology examination revealed a menin-

gioma. A craniotomy was done by a neurosurgeon to excise the entire meningioma. Transient diplopia developed after the operation, but it disappeared after 3 months. The chorioretinal folds resolved (Fig. 1D) after the operation despite faint alternating light and dark bands still being noted on fluorescein angiography (Fig. 1E). The patient received follow-up in our clinics for 15 months. The best-corrected visual acuity in her right eye improved to 12/20. MRI showed no evidence of tumor recurrence (Fig. 1F).

## DISCUSSION

Meningiomas are common intracranial tumors, but their clinical symptoms and signs can be highly variable with the different locations of the tumor.<sup>(3)</sup> They can present with headaches, seizures, progressive hemiparesis, personality change, sphincter problems, and ocular motility dysfunction. Chorioretinal folds are a rare presentation of a meningioma. Friberg and Grove in 1983 described 1 case with a



**Fig. 1** (A) Color fundus before excision of the meningioma. Alternating dark and light fine folds were demonstrated over the macular area. (B) Fluorescein angiography before excision of the meningioma. Typical alternating hyper- and hypo-fluorescent bands can be seen over the macular area. (C) T1-weighted enhanced MRI before excision of the meningioma. A large tumor mass had invaded the right orbit and anterior middle cranial fossa. (D) Color fundus after excision of the meningioma. Residual markings of the choroid folds can barely be seen in the macular area 15 months after surgery. (E) Fluorescein angiography after excision of the meningioma. Faint alternating hyper- and hypo-fluorescence could still be found 15 months after surgery. (F) T1-weighted enhanced MRI after excision of the meningioma. No evidence of tumor recurrence was found 1 year after surgery.

meningioma, who had also developed chorioretinal folds.<sup>(4)</sup> Herein, we report on another patient who had chorioretinal folds associated with a meningioma.

Chorioretinal folds are undulations of the choriocapillaris, Bruch's membrane, retinal pigment epithelium, and sensory retina. They are usually narrow and located posterior to the equator with alternating dark and light bands. Most of them are orientated horizontally and point towards the optic disc, although they can also show vertical, oblique, irregular, and reticular patterns. Radiating chorioretinal folds in the macula should raise the suspicion of choroidal neovascularization.<sup>(5)</sup> Chorioretinal folds should be differentiated from retinal folds, which are ripples in the neurosensory retina alone.<sup>(6)</sup> Unlike chorioretinal folds, retinal folds are usually large, either single or in small numbers. They frequently emanate from identifiable areas of retinal pathology or evident vitreoretinal tractions. Furthermore, chorioretinal folds are deep in the retina and choroids, but retinal folds are superficial and translucent on a slit lamp biomicroscopic examination. Norton described the fluorescein angiographic features in 1969, which provides a good tool for differentiating chorioretinal folds from retinal folds.<sup>(7)</sup> Chorioretinal folds show typical alternating hyper- and hypo-fluorescent lines in the angiogram which persist throughout all phases, while retinal folds do not exhibit these. The exact cause of this phenomenon is uncertain. One popular concept accepts that thinning and crowding of the retinal pigment epithelium over the peaks and the troughs of the folds respectively cause these alternating bands. However, a reverse histopathological condition has also been observed.<sup>(8)</sup> Further studies are

needed to understand the underlying pathological changes of chorioretinal folds.

Various causes of chorioretinal folds have been reported.<sup>(2,9-11)</sup> Table 1 categorizes and summarizes the etiologies of chorioretinal folds. Orbital tumors account for 1%~8% of chorioretinal folds,<sup>(2,9)</sup> but no available data have described the incidence of meningiomas in patients with chorioretinal folds. Among those etiologies causing chorioretinal folds, Leahey et al. classified the underlying pathologies according to laterality.<sup>(2)</sup> Thyroid eye diseases, uveitis, and choroiditis were more-common presenting etiologies with bilateral chorioretinal folds. Vascular occlusions, ocular tumors, nerve edema, retinal detachment, orbital tumors, trauma, optic atrophy, and bone compression were more-common causes in unilateral cases; while macular degeneration, hyperopia, hypotony, and scleritis could occur with either unilateral or bilateral disease. They also recommended that those patients with unilateral chorioretinal folds should receive the most-aggressive diagnostic evaluation, as they tended to have the most-serious ocular causes and the highest incidence of orbital diseases. In those studies, about 15%~30% of patients in whom no definite diagnosis could be made even after complete evaluation, were finally termed as having "idiopathic chorioretinal folds". Griebel and Kosmorsky performed lumbar punctures in 12 patients who presented with chorioretinal folds and had negative imaging studies with ultrasound, MRI, and/or computed topography.<sup>(11,12)</sup> Ten (83%) of them had an opening pressure exceeding 230 mmH<sub>2</sub>O. Among those patients with elevated intracranial pressure, half of them had chorioretinal

**Table 1.** Etiologies of Chorioretinal Folds Described by Different Authors

	Number of eyes (%)		
	Cangemi and Trempe <sup>9</sup> n = 69	Atta and Byrne <sup>10</sup> n = 31	Leahey and Brucker <sup>2</sup> n = 78
Chorioretinal disorders	16 (23)	-	23 (29)
Local inflammation or infection	14 (20)	5 (16)	13 (16)
Hyperopia	9 (13)	8 (26)	13 (17)
Hypotony	6 (10)	1 (3)	8 (10)
Tumor or mass occupying lesions	6 (10)	-	6 (7)
Optic nerve disorder	1 (2)	6 (19)	3 (4)
Trauma	6 (9)	1 (3)	1 (1)
Idiopathic	10 (15)	10 (32)	11 (14)

folds as their only presentation, and no papillary edema could be found. He concluded that patients should have an appropriate work-up, probably including a lumbar puncture, before the designation “idiopathic chorioretinal folds” can be assigned to their condition.

The mechanism of production of chorioretinal folds is still controversial. Cappaert et al. used ultrasound and found that scleral thickening and subsequent shrinkage might play some roles.<sup>(13)</sup> Bullock and Egbert produced experimental chorioretinal folds in 1974.<sup>(14,15)</sup> They concluded that forces compressing Bruch’s membrane as well as the adjacent retinal pigment epithelium layer and choriocapillaris layer led to the folds. Friberg and Lace postulated that chorioretinal folds could be caused by minimal tension exerted at the optic nerve and posterior eye wall junction.<sup>(16)</sup> In 1989, Friberg explained the etiologies of chorioretinal folds in terms of biochemical

models.<sup>(17)</sup> In our patient, MRI clearly showed that the large tumor mass was indenting the posterior pole of the right eye and compressing the posterior portion of Bruch’s membrane. It had also displaced and was stretching the optic nerve. Both compression and stretching may have played a role in the mechanism producing the chorioretinal folds in this patient.

Treating patients with chorioretinal folds of an unknown etiology can sometimes be extremely difficult. Figure 2 shows step by step strategies for approaching patients with chorioretinal folds. Detailed history-taking, a complete physical examination, and imaging studies play crucial roles in diagnosing most underlying diseases, such as orbital inflammatory or infective diseases, orbital or cranial tumors, and certain progressive ocular diseases. Lumbar punctures should be considered in those patients who have any symptoms or signs of increased intracranial pressure. If the above examina-

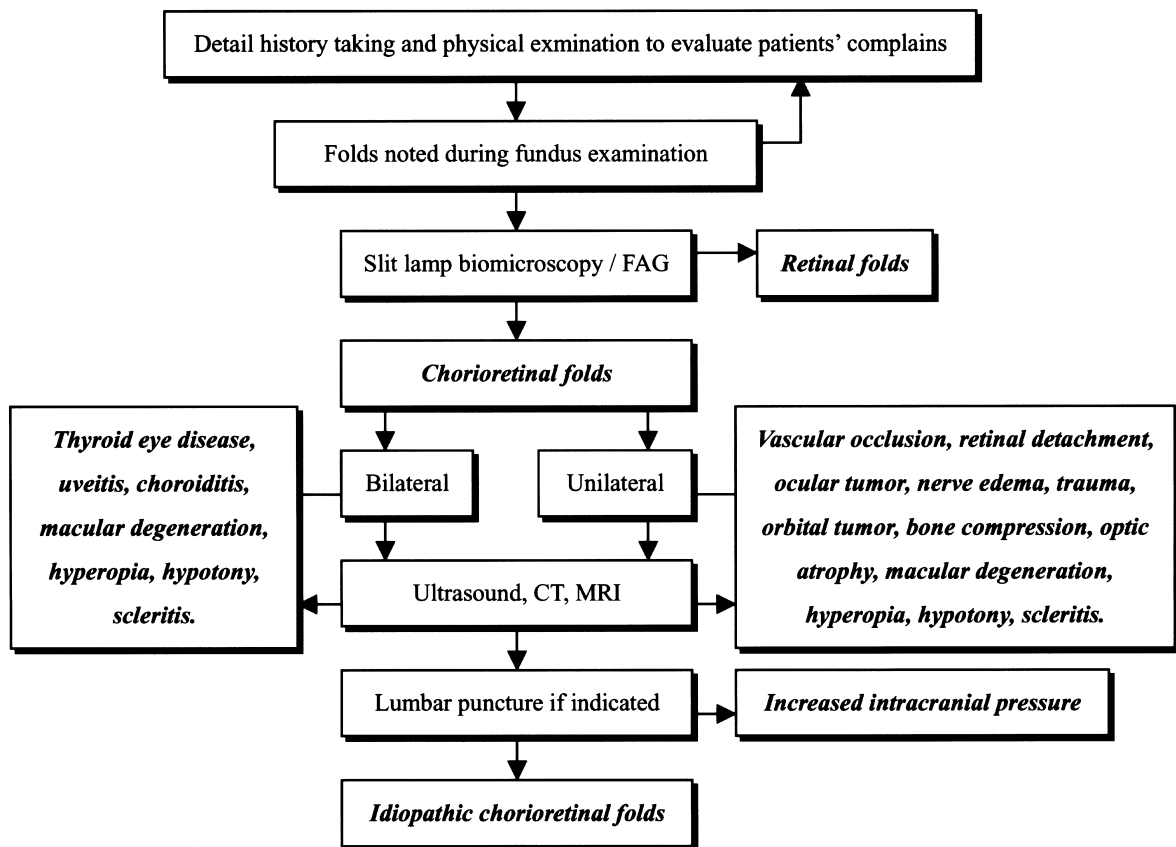


Fig. 2 Algorithm for approaching patients with chorioretinal folds.

tions all show negative results, the condition is then termed idiopathic chorioretinal folds.

Meningiomas rarely develop chorioretinal folds, but this can be the first presentation and the one that leads a patient to visit the hospital. Ophthalmologists should carefully evaluate patients with blurred vision and chorioretinal folds. Overlooking an underlying pathology will cause delays in treatment of a patient's diseases.

## REFERENCES

1. Nettleship E. Peculiar lines in the choroids in a case of post-papillitic atrophy. *Trans Ophthalmol Soc UK* 1883;84:4:167-8.
2. Leahey AB, Brucker AJ, Wyszynski RE, Shaman P. Chorioretinal folds. A comparison of unilateral and bilateral cases. *Arch Ophthalmol* 1993;111:357-9.
3. DeAngelis LM. Meningiomas. In: Mohr JP, Gautier JC, eds. *Guide to Clinical Neurology*. New York: Churchill Livingstone, 1995;743-6.
4. Friberg TR, Grove AS. Choroidal folds and refractive errors associated with orbital tumor. An analysis. *Arch Ophthalmol* 1983;101:598-603.
5. Cohen SM, Gass JD. Bilateral radial chorioretinal folds. *Int Ophthalmol* 1995;18:243-5.
6. Weissgold DJ, Brucker AJ. Chorioretinal and retinal folds. In: Guyer DR, Yannuzzi LA, Chang S, Shields JA, Green WR, eds. *Retina-Vitreous-Macula*. Philadelphia, PA: WB Saunders, 1999;256-68.
7. Norton EWD. A characteristic fluorescein angiographic pattern in choroidal folds. *Proc R Soc Med* 1969;62:119-28.
8. Shield JA, Shield CL, Rashid RC. Clinicopathologic correlation of choroidal folds: secondary to massive cranio-orbital hemangiopericytoma. *Ophthal Plast Reconstr Surg* 1992;8:62-8.
9. Cangemi FE, Trempe CL, Walsh JB. Choroidal folds. *Am J Ophthalmol* 1978;86:380-7.
10. Atta HR, Byrne SF. The findings of standardized echography for choroidal folds. *Arch Ophthalmol* 1988;106:1234-41.
11. Griebel SR, Kosmorsky GS. Choroidal folds associated with increased intracranial pressure. *Am J Ophthalmol* 2000;129:513-6.
12. Wilson WB. Choroidal folds and increased intraocular pressure. *Am J Ophthalmol* 2001;131:158-9.
13. Cappaert WE, Purnell EW, Frank KE. Use of B-sector scan ultrasound in the diagnosis of benign choroidal folds. *Am J Ophthalmol* 1977;84:375-9.
14. Bullock JD, Egbert PR. Experimental choroidal folds. *Am J Ophthalmol* 1974;78:618-23.
15. Bullock JD, Egbert PR. The origin of choroidal folds - a clinical, histopathological and experimental study. *Doc Ophthalmol* 1974;2:261-3.
16. Friberg TR, Lace JW. A comparison of the elastic properties of human choroid and sclera. *Exp Eye Res* 1988;47:429-36.
17. Friberg TR. The etiology of choroidal folds. A biomechanical explanation. *Graefes Arch Clin Exp Ophthalmol* 1989;27:459-64.

## 腦膜瘤引起之脈絡膜視網膜褶痕

楊嶺 賴旗俊 陳墩祿 吳為吉

脈絡膜視網膜褶痕乃腦膜瘤罕見表徵。本文報告 1 例以脈絡膜視網膜褶痕作為腦膜瘤最初表徵。一位 39 歲女性病患主訴右眼逐漸模糊，右眼眼底檢查結果發現脈絡膜視網膜褶痕，核磁共振掃描發現一腫瘤，佈及右眼窩及右中顱腔前方。超音波引導之切片檢查顯示為腦膜瘤。該病人遂接受腦膜瘤切除手術，術後 15 個月追蹤其右眼視力為 12/20。本文回顧脈絡膜視網膜褶痕之發生原因及處理步驟，其中某些造成脈絡膜視網膜褶痕之疾病可能危及生命。眼科醫師對此應謹慎評估及處理。(長庚醫誌 2005;28:575-80)

**關鍵字：**脈絡膜視網膜褶痕，腦膜瘤，眼窩腫瘤。

---

長庚紀念醫院 林口院區 眼科部

受文日期：民國93年4月13日；接受刊載：民國93年7月12日

索取抽印本處：吳為吉醫師，長庚紀念醫院 眼科。桃園縣333龜山鄉復興街5號。Tel.: (03)3281200 ext. 8666; Fax: (03)3287798; Email: weichi@cgmh.org.tw