

## A Solitary Laryngeal Neurofibroma in A Pediatric Patient

Yi-Wei Chen, MD; Tuan-Jen Fang, MD; Hsueh-Yu Li, MD

A neurofibroma of the larynx is a rare disease that usually involves the arytenoids and the aryepiglottic fold. Pediatric patients with a laryngeal neurofibroma often present with progressive dyspnea. A definitive diagnosis of a laryngeal neurofibroma is based on the histopathologic demonstration of the characteristic spindle cells, and a positive result in immunohistochemical staining for S-100 protein. Tumor excision of laryngeal neurofibromas by an external approach was formerly common. We present a case of a solitary laryngeal neurofibroma in a 4-year-old child that was completely excised using direct laryngoscopy and a CO<sub>2</sub> laser. There has been no recurrence after a follow-up of 4 years. For pediatric patients with an isolated laryngeal neurofibroma, endoscopic surgery provides an alternative approach due to its safety, effectiveness, and minimal invasiveness. (*Chang Gung Med J* 2004;27:930-3)

**Key words:** laryngeal neurofibroma, laryngoscopic laser surgery.

Neurogenic tumors of the larynx are unusual, and laryngeal neurofibromas are even rarer. Less than 70 cases of isolated neurofibromas were reported in MEDLINE to 2003. A laryngeal neurofibroma may occur alone or be associated with multiple neurofibromas especially in type I neurofibromatosis (von Recklinghausen's disease). Most patients with a laryngeal neurofibroma present with dyspnea, dysphagia, stridor, or hoarseness depending on the location and size of the tumor. In the past, an external approach was widely used to excise laryngeal neurofibromas; however, this is invasive for children. This report describes a pediatric patient with an isolated laryngeal neurofibroma who was successfully treated using a CO<sub>2</sub> laser under direct laryngoscopy.

### CASE REPORT

A 4-year-old girl was referred to the Department of Otolaryngology at Chang Gung Memorial Hospital, Taipei due to a progressively worsening

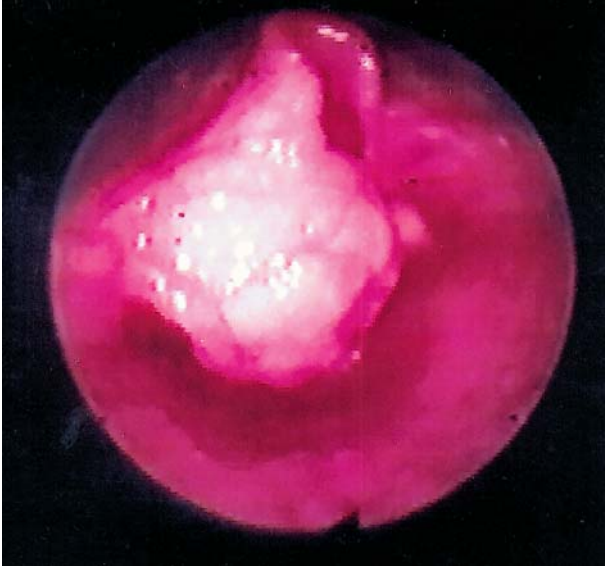inspiratory stridor for 2 years. A flexible laryngoscopic examination revealed a 2×2-cm pinkish mass covered by mucosa on the left aryepiglottic fold which was obstructing the airway (Fig. 1). Physical examination showed no other subcutaneous neurofibromas or *caf-au-lait* spots in the entire body. The patient had no known systemic or congenital abnormalities, and the developmental milestones were within the normal ranges. Based on these findings, a tentative diagnosis of a benign laryngeal tumor was made. The patient underwent direct laryngoscopy and CO<sub>2</sub> laser microsurgery using 6 W in the continuous mode. The mass was completely excised from its base at the aryepiglottic fold using the laser (Fig. 2). No intraoperative or postoperative complications were noted. The histopathology revealed a neurofibroma (Fig. 3). During the postoperative period, no voice or swallowing disturbances were noted. There was no recurrence of the tumor during 4 years of follow-up.

---

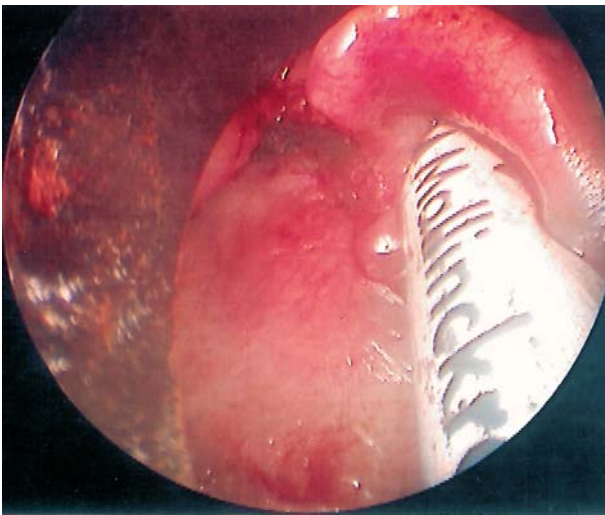
From the Department of Otolaryngology, Chang Gung Memorial Hospital, Taipei.

Received: Jan. 5, 2004; Accepted: Mar. 16, 2004

Address for reprints: Dr. Hsueh-Yu Li, Department of Otolaryngology, Chang Gung Memorial Hospital, 5, Fushing St., Gueishan Shiang, Taoyuan, Taiwan 333, R.O.C. Tel.: 886-3-3281200 ext. 3967; Fax: 886-3-3979361; E-mail: wei0721@ms14.hinet.net



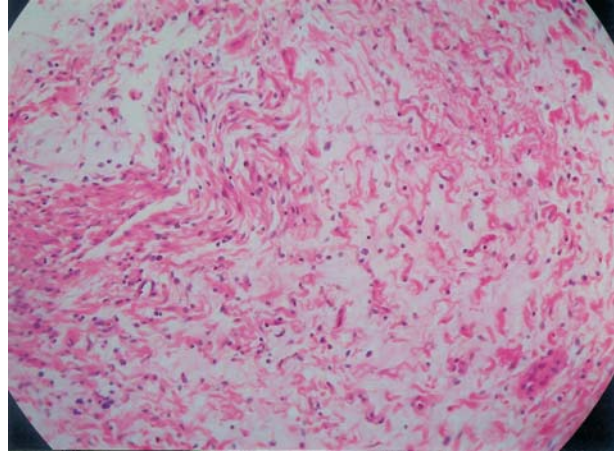
**Fig. 1** A 2×2-cm pinkish mass covered with mucosa on the left aryepiglottic fold. The airway was partially obstructed.



**Fig. 2** The tumor which was completely excised with a CO<sub>2</sub> laser (6 W, continuous mode) from its base at the aryepiglottic fold with the help of a laryngoscope. The laryngeal structures were carefully preserved.

## DISCUSSION

A neurofibroma of the larynx is a rare disease. Suchanek reported the first case of an isolated endolaryngeal neurofibroma in 1925.<sup>(1)</sup> Half of the cases presented in previous reports were solitary while others were associated with von



**Fig. 3** Microscopic findings showing spindle cells with prominent collagen production and trapped nerve fibers. Myxoid changes and hyalinization can also be noted.

Recklinghausen's disease.<sup>(2)</sup> The ratio of females to males affected by laryngeal neurofibromas was 3:2.<sup>(3)</sup> The ages of the affected patients ranged from 2 to 60 years old,<sup>(4,5)</sup> with children and young adults comprising more than half of the cases reported.

The most frequently affected area is the supra-glottic region, with the majority involving the arytenoids and the aryepiglottic fold, followed by the false vocal cords<sup>(5,6)</sup> because these areas are rich in terminal nerve plexuses.<sup>(7)</sup> It is believed that the neurofibroma arises from the superior laryngeal branch of the glossopharyngeal nerve.<sup>(8,9)</sup> The signs and symptoms of a laryngeal neurofibroma depend on the location and size of the tumor. Due to its slow growth, patients with a laryngeal neurofibroma are usually diagnosed incidentally or present with lumpthroat, dysphagia, voice changes, stridor, and dyspnea.<sup>(4,5)</sup> A laryngeal neurofibroma is benign and usually appears as a smooth round white mass, but may be firm or elastic during a laryngeal examination. A punch biopsy is difficult to perform, hence a preoperative histologic diagnosis has often been difficult. In the present case, the laryngeal neurofibroma was originated from the left aryepiglottic fold and presented with progressive inspiratory stridor, but had a smooth surface. The lesion was suspected to be benign based on the history and examinations. A punch biopsy was not performed, but an excisional biopsy was selected.

The histopathology of this case showed spindle

cells with slender, wavy nuclei containing ill-defined eosinophilic cytoplasm, prominent collagen production, and trapped nerve fibers with additional myxoid changes and hyalinization. The immunohistochemical staining for S-100 protein was positive and confirmed the diagnosis of a neurofibroma.

The treatment of choice for laryngeal neurofibromas is surgical removal. Excision of the tumor using a laryngoscope or through an external approach has been reported in the literature.<sup>(10-12)</sup> Lateral pharyngotomic and lateral thyrotomic approaches were the traditional methods used to gain access to the lesion.<sup>(13)</sup> Sometimes a tracheostomy was required to maintain the airway when these procedures were used. The advantages of the external approach include a wider field of operation and ease in controlling the bleeding. But these invasive procedures increase the risk for injury to the adjacent laryngeal structures. There is a visible scar on the neck, and the patient usually requires a longer hospitalization period. On the other hand, the laryngoscopic approach is less risky for the surrounding structures, produces less cosmetic injury, and requires a shortened hospital stay. This was more suitable for our patient because she was only 4 years old, and the tumor was small. However, the limited operative field of the laryngoscopic approach makes it difficult to treat larger invasive tumors or manage massive hemorrhaging. A CO<sub>2</sub> laser was used to completely excise the tumor at its base, thus decreasing the chance of local recurrence and reducing the risk of intraoperative bleeding. Postoperative complications of endoscopic surgery for a laryngeal neurofibroma include bleeding, airway compromise, scarring with or without laryngeal stenosis, and ipsilateral vocal palsy.<sup>(14)</sup> None of these complications was seen in our patient.

Follow-up during the postoperative period is important. Occasionally it is possible to find subcutaneous neurofibromas or *caf-au-lait* spots in patients with a solitary neurofibroma. This would mean that the disease had progressed into multiple neurofibromatosis.<sup>(6)</sup> Malignant transformation into a neurofibrosarcoma and a malignant schwannoma has been reported in patients with neurofibromas, and these were usually associated with von Recklinghausen's disease.<sup>(5,15,16)</sup> No malignant changes have been noted to occur among isolated neurofibromas to date.<sup>(17)</sup> The progression from a solitary neurofibroma to

multiple neurofibromatosis and then transformation into malignancy is theoretically possible but exceedingly rare.

A laryngeal neurofibroma is a benign tumor. For pediatric patients, minimally invasive endoscopic surgery of isolated lesion can be considered due to its safety and effectiveness, and a satisfactory outcome.

## REFERENCES

1. Suchanek E. Neurinom des kehlkopfeinganges. *Monatsschr Orhenheilkd Laryngo-Rhinol* 1925;50:613-7.
2. Sidman J, Wood RE, Poole M, Postma DS. Management of plexiform neurofibroma of the larynx. *Ann Otol Rhino Laryngol* 1987;96:53-5.
3. Figi FA, Stark DB. Neurofibroma of the larynx. Presentation of five cases. *Laryngoscope* 1953;63:652-9.
4. Stanley RJ, Scheithauer BW, Weiland LH, Neel HB III. Neural and neuroendocrine tumors of the larynx. *Ann Otol Rhinol Laryngol* 1987;96:630-8.
5. Chang-Lo M. Laryngeal involvement in von Recklinghausen's disease: a case report and review of the literature. *Laryngoscope* 1977;87:435-42.
6. Supance JS, Queneue DJ, Crissman J. Endolaryngeal neurofibroma. *Otolaryngol Head Neck Surg* 1980;88:74-8.
7. Helg JR. Neurinomas of the larynx and neurofibromatosis of von Recklinghausen's. *Pract Otorhinolaryngol (Basel)* 1950;12:165-84.
8. Maisel RH, Ogura JH. Neurofibromatosis with laryngeal involvement. *Laryngoscope* 1974;84:132-40.
9. Jasper BW, Stern FA. Neurofibroma of the larynx occurring with von Recklinghausen disease: report of a case. *Arch Otolaryngol* 1973;98:77-9.
10. Aponte GE, Vicens EA. Neurogenic tumours of the larynx. *Ann Otol Rhinol Laryngol* 1955;64:319-25.
11. Schaeffer BT, Som PM, Biller HF, Som ML, Arnold LM. Schwannomas of the larynx: review and computed tomographic scan analysis. *Head Neck Surg* 1986;8:469-72.
12. Barnes L, Ferlito A. Soft tissue neoplasms. In: Ferlito A, ed. *Neoplasms of the Larynx*. Churchill Livingstone: Hong Kong, 1993;265-305.
13. Cummings CW, Montgomery WW, Balogh K. Neurogenic tumors of the larynx. *Ann Otol Rhinol Laryngol* 1969;78:76-95.
14. Pearlman SJ, Friedman EA, Appel M. Neurofibroma of the larynx. *Arch Otolaryngol* 1950;52:8-14.
15. Holt GR. Von Recklinghausen's neurofibromatosis. *Otolaryngol Clin N Am* 1973;20:179-93.
16. Stines J, Rodde A, Carolus JM, Perrin C, Becker S. CT findings of laryngeal involvement in von Recklinghausen disease. *J Comput Assist Tomogr* 1987;11:141-3.
17. Enzinger FM, Weiss SW. Benign tumours of peripheral nerves. In: Gay SMK, ed. *Soft Tissue Tumours*, 3rd Ed, C. V. Mosby Company: St. Louis, 1995;821-88.

## 兒童單發性喉神經纖維瘤

陳益璋 方端仁 李學禹

發生於喉部的神經纖維瘤是非常罕見的，它通常會侵犯杓狀軟骨以及杓會厭皺襞。發生於嬰幼兒身上的喉神經纖維瘤常以漸進性的呼吸窘迫來表現，但最終的診斷仍需要在組織學上發現明顯的紡錘型細胞及針對S-100蛋白質的特殊染色來確定。傳統上處理此類腫瘤多以經外頸部路徑手術方式切除。我們在此報告一例4歲的小朋友，利用喉頭鏡及二氧化碳雷射完全切除腫瘤，並經過4年的追蹤而無復發的現象。對於兒童來說，利用內視鏡手術來處理單發性喉神經纖維瘤，不僅安全有效而且侵犯性小，是可供選擇的一種手術方式。(長庚醫誌 2004;27:930-3)

**關鍵字：**喉神經纖維瘤，喉頭鏡雷射手術。

---

長庚紀念醫院 台北院區 耳鼻喉部

受文日期：民國93年1月5日；接受刊載：民國93年3月16日

索取抽印本處：李學禹醫師，長庚紀念醫院 耳鼻喉部。桃園縣333龜山鄉復興街5號。Tel.: (03)3281200轉3967; Fax: (03)3979361; E-mail: wei0721@ms14.hinet.net