

## Brachiobasilic Fistula as a Secondary Access Procedure: An Alternative to a Dialysis Prosthetic Graft

Chieh-Hung Lee, MD; Po-Jen Ko, MD; Yun-Hen Liu, MD; Hung-Chang Hsieh, MD;  
Hui-Ping Liu, MD

**Background:** In order to extend the availability of each extremity as an access site for long-term dialysis, we created a brachiobasilic fistula by superficialization of the basilic vein, which had previously been arterialized. In this work, we present the preliminary results of this procedure.

**Methods:** Patients with prior forearm arteriovenous fistula dysfunction without an adequate superficial vein were enrolled in this study. The basilic vein was superficialized to create a brachiobasilic fistula. The basilic veins were transposed in 16 patients and elevated in 4 patients. At the same time, another 50 upper arm bridge prosthetic grafts were created. Finally, surgery-related complications and patency rates were analyzed and compared with upper arm prosthetic grafts.

**Results:** Twenty brachiobasilic fistulas and 50 upper arm bridge prosthetic grafts were created in 70 patients in our hospital from September 2001 to January 2004. No surgery-related deaths occurred. Cannulation of the brachiobasilic fistulas began at an average of 33 (range, 21 to 84) days after surgery. All fistulas were successfully used for dialysis. The mean follow-up was 15 (range, 2 to 26) months. Moreover, the primary patency rates for the brachiobasilic fistulas and upper arm prosthetic grafts were 80% and 70%, respectively. Notably, all brachiobasilic fistulas remained patent at the last follow-up. Furthermore, surgery-related complications were 25% for brachiobasilic fistulas and 60% for upper arm prosthetic grafts. Common complications of brachiobasilic fistulas were graft thrombosis, arm swelling, hematoma formation, and steal syndrome.

**Conclusions:** Brachiobasilic fistulas are technically feasible and show excellent patency. Fewer surgery-related complications were seen compared to upper arm prosthetic grafts, and most of them were treated without loss of the fistula. We suggest that this procedure should be considered before placement of a prosthetic graft whenever feasible. These observations merely represent our preliminary experience regarding this procedure, and further investigation involving larger cases numbers is needed in the future.  
(*Chang Gung Med J* 2004;27:816-23)

**Key words:** transposition, brachiobasilic fistula, arteriovenous fistula.

---

From the Division of Thoracic and Cardiovascular Surgery, Chang Gung Memorial Hospital, Chang Gung University, Taipei.  
Received: Feb. 26, 2004; Accepted: Sep. 21, 2004

Address for reprints: Dr. Yun-Hen Liu, Division of Thoracic and Cardiovascular Surgery, Chang Gung Memorial Hospital, No. 5, Fushing St., Gueishan Shiang, Taoyuan, Taiwan 333, R.O.C. Tel.: 886-3-3281200; Fax: 886-3-3285818; E-mail: pjko@cgmh.org.tw

Creating an arteriovenous (AV) fistula for long-term hemodialysis is always challenging for surgeons.<sup>(1)</sup> Patients undergoing long-term hemodialysis either lack adequate veins for construction or display development of an unsalvageable thrombosis in such a fistula. Consequently, a secondary or tertiary access site is commonly required. The choice is frequently between the use of a prosthetic graft or an autologous vein.<sup>(2)</sup> Upper-extremity access with the use of polytetrafluoroethylene (PTFE) has proven valuable, but patency rates are lower and complication rates are higher than with autologous fistulas.<sup>(2)</sup>

For patients suffering from prior forearm AV fistula dysfunction without an adequate superficial vein, we believe that a brachio basilic fistula, originally described by Carcardo et al. and Dagher et al.<sup>(3)</sup>, should precede placement of PTFE grafts in most patients as a secondary access based on the all-autogenous policy issued by the National Kidney Foundation. This study presents the preliminary surgical results for brachio basilic fistulas in our hospital.

## METHODS

From September 2001 to January 2004, twenty brachio basilic fistulas were created in 20 patients who had prior forearm arteriovenous access dysfunction and an inadequate superficial vein. During the same period, an additional 50 upper arm bridge prosthetic grafts were created. Inclusion criteria for brachio basilic fistula creation included: (1) primary forearm AV fistula dysfunction without an adequate superficial vein; (2) adequate basilic vein sized > 4 mm; and (3) no upper arm AV graft having previously been performed. Two techniques were used to create a brachio basilic fistula: elevation and transposition. Sixteen fistulas were constructed by transposing the basilic vein anteriorly in the arm using a technique similar to that described by Dagher et al.<sup>(3)</sup> Four patients received elevation of the basilic vein superficial to the surgically reapproximated deep fascia and subcutaneous tissue in the inner aspect of the arm. Notably, all patients received general anesthesia for these procedures, because these procedures require long incisions and dissection of the basilic vein. Patency was determined based on the ability to access the fistula for hemodialysis. Moreover, primary patency was defined as the period from graft cre-

ation to the development of a thrombosis or another complication requiring surgical revision of the graft. While operative ligation was classified as failure, death with a functioning fistula was considered loss to follow-up when the cause of death was not related to the fistula. Follow-up information was obtained from inpatient/outpatient records, office charts, and telephone conversations with referring physicians, dialysis personnel, and individual patients.

## Anatomical and surgical techniques

Under general anesthesia, the basilic vein of the upper arm was exposed through a medial longitudinal incision (with a mean length of 16 cm), similar to the approach described by Dagher et al.<sup>(4,5)</sup> Notably, the medial brachial cutaneous nerve is in close proximity to the basilic vein, and needs to be carefully separated from the vein during dissection. The branches of the vein were ligated. The basilic vein was mobilized up to its junction with the brachial vein. The anterior surface of the vein was marked to avoid axial rotation. A subcutaneous tunnel was created on the anterior aspect of the arm, maintaining its axial orientation, and the vein was passed through the tunnel. An end-to-side anastomosis to the brachial artery was created using 6-0 polypropylene sutures (Fig. 1). Additional care was taken to ensure hemostasis at the end of the procedure.



**Fig. 1** Transposition of the basilica vein via the subcutaneous tunnel.

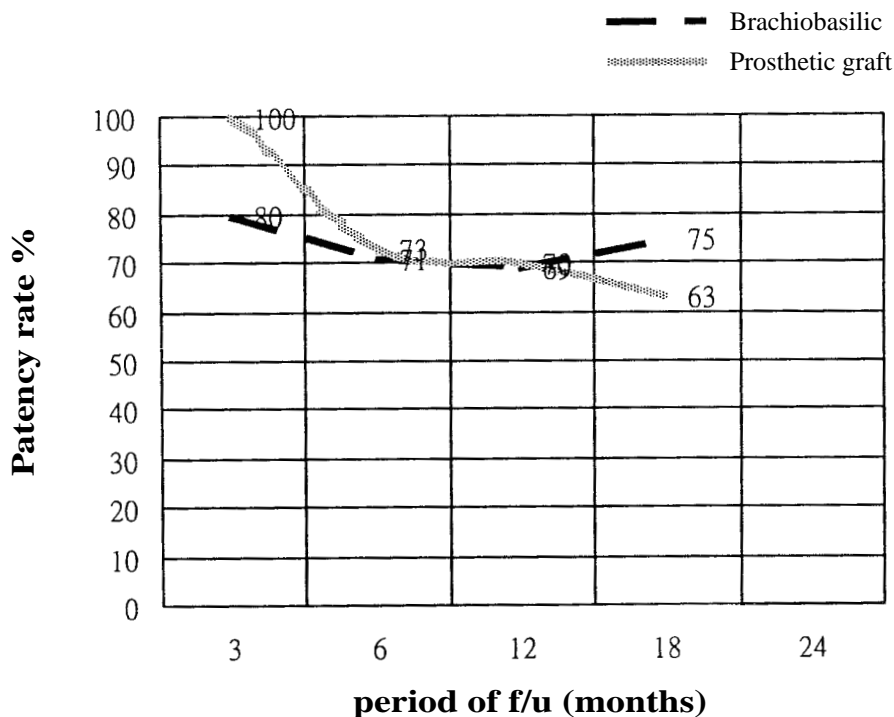
## RESULTS

Twenty brachiobasilic fistulas were created in 20 patients (8 males, 12 females, while another 50 patients (20 males, 30 females) received upper arm bridge prosthetic grafts during the same period. The mean age of the patients receiving brachiobasilic fistulas and upper arm AV grafts were 61 (range, 13 to 89) and 69 (range, 37 to 84) years, respectively. The clinical characteristics of patients are represented in Table 1. No operative deaths occurred. The primary patency rates were 80% for the brachiobasilic fistulas and 70% for the upper arm AV grafts. Patency rates are presented in Fig. 2. Primary patency rates for the different surgical techniques were 81% for the transposition group and 75% for the elevation group, respectively. The most-common surgery-related complication of brachiobasilic fistulas was graft thrombosis; most of those were treated without loss of the graft. Complications of brachiobasilic fistulas requiring additional procedures developed in 5 patients (25%), including 1 patient who presented with prolonged arm swelling due to venous outlet

**Table 1.** Clinical Characteristics of Patients

	Upper arm prosthetic graft	Transposition of the basilic vein	Elevation of the basilic vein
No. of patients	50	16	4
Gender			
Male	20	6	1
Female	30	10	3
Age (yr)			
Mean	69	63.4	55
Range	37~84	13~89	40~64
Underlying disease			
Heart disease	1 (2%)	0	0
DM	31 (62%)	2	1
HTN	27 (54%)	3	0
Complications			
Graft thrombosis	6 (12%)	1	1
Infections	2	0	0
Arm swelling	20	1	0
Hand ischemia	0	1	0
Hematoma	2	0	1
Subtotal	30 (60%)	18.75%	50%

**Abbreviations:** DM: diabetes mellitus; HTN: hypertension.



**Fig. 2** Patency rate of brachiobasilic fistulas and upper arm prosthetic grafts.

stenosis for which balloon angioplasty was performed for the obstructed vein, and 2 fistulas which required a surgical thrombectomy for acute graft thrombosis after episodes of hypotension. Additionally, banding of the brachio-basilic fistula was performed in 1 patient with hand ischemia, and 1 patient needed re-exploration for postoperative bleeding.

Cannulation of the brachio-basilic fistula began at an average of 33 (range, 21 to 84) days after surgery. Delays in cannulation were mainly due to prolonged arm swelling and obesity. The mean follow-up was 15 months, and all brachio-basilic fistulas were successfully used for dialysis. All fistulas remained patent and were functioning well for hemodialysis at the last follow up.

## DISCUSSION

For long-term hemodialysis patients lacking adequate superficial veins, the choices are generally between an autologous vein and placement of prosthetic grafts. Based on the all-autogenous policy issued by the National Kidney Foundation, we believe that additional autologous options should be considered before placing a prosthetic graft.<sup>(6-8)</sup>

A forearm radiobasilic fistula has been reported to be a good secondary choice of access. Patients enrolled in our study for brachio-basilic fistulas were those with prior forearm fistula dysfunction. Such patients usually either lack an adequate superficial vein or have poor radial artery quality. Furthermore, multiple puncture holes, aneurysm formation, and previous graft implantation over the forearm were also noted in some of our patients. These factors further complicate the creation of forearm radiobasilic fistulas. For these reasons, forearm radiobasilic fistulas were excluded from our study.

The upper arm basilic vein is relatively large and has been called the "hidden vein", because it is not visible by simple inspection or palpation. Consequently, the basilic vein frequently escapes damage inflicted by repeated iatrogenic venopunctures and intravenous lines, and represents a high-quality conduit for hemodialysis access.<sup>(9)</sup>

The basilic vein offers the following advantages over PTFE.

1. Only 1 or no anastomosis is needed for a brachio-basilic fistula. Venous outlet stenosis can thus

be avoided, eliminating the most-common problem encountered with PTFE.<sup>(5)</sup>

2. A large-caliber basilic vein provides a high flow rate.<sup>(3)</sup>

3. A native vein fistula provides better resistance to infection than a prosthetic graft.<sup>(9,10)</sup>

The primary patency rate for brachio-basilic fistulas was 80%, and all fistulas remained patent at the last follow-up, compared with the results of upper bridge prosthetic grafts in our study (70%) and previous reports, in which the rate ranged from 65% to 70% at 1 year and 49% to 51% at 2 years.<sup>(3,6,7,11)</sup>

The complication rate was 25% in our study, and although high, it is lower than that for upper arm prosthetic grafts in our study (60%) and that reported for PTFE grafts (60% to 100%).<sup>(2,3,11)</sup> We suggest that brachio-basilic fistulas should be used in preference to prosthetic grafts for secondary or tertiary hemodialysis access whenever feasible.

In our study, all patients received general anesthesia mainly because the conventional surgical technique for a brachio-basilic fistula consists of a long incision with dissection of the basilic vein. In view of the overall general condition of long-term dialysis patients, we should attempt to use general anesthesia as little as possible. Other anesthetic methods should be evaluated; regional anesthetic infiltration combined with axillary and interscalene block may be a good alternative to general anesthesia.<sup>(12,13)</sup> But these procedures are more technically demanding and require an experienced anesthesiologist. Further evaluations are required in the future of the efficiency of these procedures and possible complications such as toxicity or nerve injury from the block.

Conventional techniques for brachio-basilic fistula creation often require long incisions. In order to minimize wound complications, minimally invasive techniques such as video-assisted basilic vein transposition have been reported.<sup>(14-16)</sup> The complication rate is low, and the fistulas can be used early. But the equipment for these techniques is still very expensive, and the costs are much higher than for conventional techniques. Costs remain the major factor limiting the wider use of this technique.

In our study, cannulation of the brachio-basilic fistulas began at an average of 33 (range, 21 to 84) days after surgery. Delays in cannulation were mainly due to prolonged arm swelling and obesity. Transposed brachio-basilic fistulas are considered to

be new grafts which need time to mature. According to the Dialysis Outcomes Quality Initiative (DOQI) guidelines for access maturation, a dialysis AV graft should not routinely be used until 14 days after placement. Cannulation of a new dialysis AV graft should not routinely be attempted, even 14 days or longer after placement, until swelling has gone down enough to allow palpation of the course of the graft. Ideally, 3 to 6 weeks should be allowed prior to cannulation of a new graft.

Early postoperative swelling is not an uncommon finding following brachio basilic fistula or upper arm bridge prosthetic graft creation. It results from venous hypertension, and as collaterals develop and outflow improves, it rapidly disappears. Arm elevation and patient reassurance are usually sufficient. Persistence of severe swelling suggests obstruction of the major outflow vein (the axillary-subclavian-innominate vein). A venogram can document this clinical impression. This condition can be managed by balloon angioplasty, balloon angioplasty plus stenting, extension of the graft over the obstruction, or ligation of the fistula in severe cases.

Late swelling is usually due to central vein (axillary, subclavian, or innominate vein) stenosis or obstruction. In this particular situation, the causative factor was intima hyperplasias that resulted from turbulent flow draining of the AV fistula or trauma to the vascular wall induced by previous indwelling catheter placement. A diagnosis is supported by the presence of venous collaterals around the shoulder and is documented by fistula angiography. Treatment modalities consist of balloon angioplasty alone or with stenting, extension of a graft to the unobstructed vein, or access ligation.<sup>(14,17,18)</sup>

Steal syndrome tends to be more prevalent with brachio basilic fistulas, most likely because of the larger diameter of the basilic vein. In addition, more-severe atherosclerotic arterial disease in these patients, which may have resulted in multiple prior failures of the access procedure such that they now must undergo brachio basilic fistula placement, also may be a contributing factor to steal syndrome.

Difficult cannulation or inadequate compression of the fistula may lead to hematoma formation and shunt occlusion. The transposed brachio basilic fistula is more easily cannulated due to the basilic vein being transposed to the anterior position of the upper arm, reducing the frequency of hematoma formation

and thrombosis. Ahmed Hossny et al. described a higher rate of extravasation and hematoma formation in elevated veins.<sup>(19)</sup> The prevalence of hematomas in elevated fistulas results from difficult cannulation of the basilic vein in the inner aspect of the upper arm. Multiple attempts to cannulate a vein result in venous wall laceration, with extravasations and hematoma formation. Frequent needle displacement and inadequate compression of the puncture site are major causes of thrombosis in elevated fistulas, and Humphries et al. confirmed these observations.<sup>(19-21)</sup> Needle displacement usually follows inadvertent patient arm movement as he or she attempts to find a more-comfortable position. To monitor the puncture site, dialysis nurses used to position the arm of the patient in slight abduction and external rotation, a position that many patients cannot stand for prolonged periods. Cannulation of an elevated fistula requires special skills, and probably requires more time and practice from dialysis nursing staff.

Surgery-related complications were 25%, lower than for the upper arm prosthetic graft in our study (70%) and that reported for prosthetic grafts which ranged from 60% to 100%.<sup>(2,3,11,22,23)</sup> The most-common complication in this study was graft thrombosis, in 10% of brachio basilic fistulas and 12% of upper arm bridge grafts.

Graft thrombosis was the most-common complication of AV fistulas, and early thrombosis (within 1 month after surgery) was mainly due to technical or judgmental errors. Common causes were kinking of the vein over the anastomosis, an inadequate anastomotic technique, and undetected venous outflow occlusion. In addition, inadequate arterial inflow due to atherosclerotic arterial disease can also produce early failure. Late thrombosis is mostly due to progressive stenosis over the anastomosis and venous outlet, secondary to intimal hyperplasia. Treatments include a thrombectomy, thrombectomy plus balloon angioplasty, or graft bypass beyond the diseased vein.

Hematoma formation can be improved by a gentle dissecting technique, meticulous hemostasis during the operation, cannulation until AV graft maturation, and use of a well-trained dialysis nursing staff.

Furthermore, failure of a brachio basilic fistula does not prohibit subsequent use of a prosthetic conduit at the same site.<sup>(15)</sup> Matsuura et al. successfully inserted a prosthetic graft in 89% of their patients

with a failed brachio basilic fistula.<sup>(7)</sup>

According to our experience with brachio basilic fistulas, this surgical method was technically feasible and showed excellent patency. Operative complications were lower than those for prosthetic grafts, and most were treated without loss of the fistula. We concluded that for those patients with forearm dialysis fistula dysfunction without an adequate superficial vein, a brachio basilic fistula should be considered as an alternative to prosthetic graft insertion. Regional anesthesia combined with axillary or interscalene nerve block can be a good choice to decrease the need for general anesthesia in hemodialysis patients if available. Furthermore, a failed brachio basilic fistula does not prohibit subsequent use of a prosthetic conduit at the same site in the future. We believe that a brachio basilic fistula should precede the placement of upper arm prosthetic grafts in most patients for upper arm dialysis access whenever feasible.

In this manner, we tried to maximize future options, increase the patency of hemodialysis access, and minimize the complications and costs. These observations merely represent our preliminary experiences with brachio basilic fistulas, and further investigations involving a larger number of cases are required in the future.

## REFERENCES

1. Butterworth PC, Doughman TM, Wheatley TJ, Nicholson ML. Arteriovenous fistula using transposed basilic vein. *Br J Surg* 1998;85:653-4.
2. Kherlakian GM, Roedersheimer LR, Arbaugh JJ, Newmark KJ, King LR. Comparison of autogenous fistula versus expanded polytetrafluoroethylene graft fistula for angioaccess in hemodialysis. *Am J Surg* 1986;152:238-43.
3. Taghizadeh A, Dasgupta P, Khan MS, Taylor J, Koffman G. Long-term outcomes of brachio basilic transposition fistula for haemodialysis. *Eur J Vasc Endovasc Surg* 2003;26:670-2.
4. LoGerfo FW, Menzoian JO, Kumaki DJ, Idelson BA. Transposed basilic vein-brachial arteriovenous fistula. A reliable secondary-access procedure. *Arch Surg* 1978; 113:1008-10.
5. Dagher FJ. The upper arm AV hemoaccess: long term follow-up. *J Cardiovasc Surg (Torino)* 1986;27:447-9.
6. Oliver MJ, McCann RL, Indridason OS, Butterly DW, Schwab SJ. Comparison of transposed brachio basilic fistulas to upper arm grafts and brachiocephalic fistulas. *Kidney Int* 2001;60:1532-9.
7. Matsuura JH, Rosenthal D, Clark M, Shuler FW, Kirby L, Shotwell M, Purvis J, Pallos LL. Transposed basilic vein versus polytetrafluoroethylene for brachial-axillary arteriovenous fistulas. *Am J Surg* 1998;176:219-21.
8. Benedetto BJ, Madden RL, Kurbanov A, Lipkowitz GS. Transposed basilic vein fistula: a superior alternative to prosthetic grafts? *Curr Surg* 2000;57:503-4.
9. Dahduli SA, Qattan NM, Al-Kuhaymi RA, Al-Jabreen MA, Al-Khader AA. Mobilization and superficialization of basilic vein for brachio basilic fistula. *Saudi Med J* 2002;23:1203-5.
10. Burkhart HM, Cikrit DF. Arteriovenous fistulae for hemodialysis. *Semin Vasc Surg* 1997;10:162-5.
11. Murphy GJ, White SA, Knight AJ, Doughman T, Nicholson ML. Long-term results of arteriovenous fistulas using transposed autologous basilic vein. *Br J Surg* 2000;87:819-23.
12. Alsalti RA, el-Dawlatly AA, al-Salman M, Jomaa S, Amro K, Dweiri MA, Jasser MT. Arteriovenous fistula in chronic renal failure patients: comparison between three different anesthetic techniques. *Middle East J Anesthesiol* 1999;15:305-14.
13. Gonzalez MF, Ansuategui SM. Block of the brachial plexus through the axillary route with bupivacaine for the creation of arteriovenous fistulas in patients with chronic renal insufficiency. *Rev Esp Anesthesiol Reanim* 1974; 21:216-21.
14. Verstandig AG, Bloom AI, Sasson T, Haviv YS, Rubinger D. Shortening and migration of Wallstents after stenting of central venous stenoses in hemodialysis patients. *Cardiovasc Intervent Radiol* 2003;26:58-64.
15. Tordoir JH, Dammers R, de Brauw M. Video-assisted basilic vein transposition for haemodialysis vascular access: preliminary experience with a new technique. *Nephrol Dial Transplant* 2001;16:391-4.
16. Hayakawa K, Tsuha M, Aoyagi T, Miyaji K, Hata M, Tanaka S, Tanaka A, Shiota J. New method to create a vascular arteriovenous fistula in the arm with an endoscopic technique. *J Vasc Surg* 2002;36:635-8.
17. Maskova J, Komarkova J, Kivanek J, Danes J, Slavikova M. Endovascular treatment of central vein stenoses and/or occlusions in hemodialysis patients. *Cardiovasc Intervent Radiol* 2003;26:27-30.
18. Bhatia DS, Money SR, Ochsner JL, Crockett DE, Chatman D, Dharamsey SA, Mulingtapang RF, Shaw D, Ramee SR. Comparison of surgical bypass and percutaneous balloon dilatation with primary stent placement in the treatment of central venous obstruction in the dialysis patient: one-year follow-up. *Ann Vasc Surg* 1996;10:452-5.
19. Hossny A. Brachio basilic arteriovenous fistula: different surgical techniques and their effects on fistula patency and dialysis-related complications. *J Vasc Surg* 2003;37:821-6.
20. Humphries AL, Jr., Colborn GL, Wynn JJ. Elevated basilic vein arteriovenous fistula. *Am J Surg* 1999;177:489-91.

21. Davis JB, Jr., Howell CG, Humphries AL, Jr. Hemodialysis access: elevated basilic vein arteriovenous fistula. *J Pediatr Surg* 1986;21:1182-3.
22. Kumar A, Sinha S, Sharma AK. Long-term results of arteriovenous fistulas using transposed autologous basilic vein. *Br J Surg* 2000;87:1735-6.
23. Fitzgerald JT, Schanzer A, Chin AI, McVicar JP, Perez RV, Troppmann C. Outcomes of upper arm arteriovenous fistulas for maintenance hemodialysis access. *Arch Surg* 2004;139:201-8.

## 肘貴要動靜脈洗腎用瘻管：洗腎用人工血管之外的另一選擇

李杰鴻 柯博仁 劉永恆 謝宏昌 劉會平

**背景：** 爲了善用長期血液透析患者的手臂血管，我們對一些動靜脈瘻管失效的病人，將其之前已經有動脈化過的貴要靜脈施以肘貴要動靜脈洗腎用瘻管的手術，以作爲洗腎通路。本研究爲手術成果之初步呈現。

**方法：** 自2001年至2004年，總共有20個長期透析的病人接受了這種肘貴要動靜脈瘻管吻合及表淺化手術。所有的病人皆爲上臂的前次動靜脈瘻管失效，並且沒有合適的淺層靜脈可作爲洗腎瘻管者。手術的技術，有16位是行貴要靜脈轉位，4位是作表淺化。在同一時期，我們另外收集50位上臂人工血管病患資料作爲比較，我們分析了這些病人的瘻管併發症以及暢通率。

**結果：** 20個病人中，沒有手術相關的術後死亡。在術後平均33天後開始始用瘻管（21至84天）。所有的瘻管均可以成熟到可以洗腎的程度。平均追蹤了15個月（2到26個月）其瘻管的暢通率於肘貴要動靜脈爲80%而上臂人工血管爲70%。於最後一次追蹤時，所有瘻管皆維持暢通。手術相關的併發症肘貴要動靜脈爲25%而上臂人工血管爲60%。常見的併發症包括了血管栓塞，血腫，手臂水腫以及盜血症候群。

**結論：** 對於某些上臂動靜脈瘻管失效的病人，肘貴要動靜脈瘻管手術在技術上是可行的，暢通率也頗理想。相較於人工血管，手術的併發症率較低。跟據我們的初步經驗，以這樣的手術方式，只要病患狀況適合，可以替代人工血管的應用。初步的經驗還須要進一步大規模研究來印證。

(長庚醫誌 2004;27:816-23)

**關鍵字：** 血管轉位，肘貴要動靜脈瘻管，動靜脈瘻管。