

## Pseudoaneurysm Formation 12 Years after Ringed Intraluminal Graft Replacement for Type B Aortic Dissection

Jen-Ping Chang, MD; Hung-I Lu, MD; Ming-Jang Hsieh, MD; Chiung-Lun Kao, MD;  
Chiung-Jen Wu, MD

A sutureless ringed intraluminal graft has been used as a substitute for the diseased aorta with the advantage of decreasing the aortic cross-clamp time and blood loss. Concerns remain about implications of anecdotal accounts of late complications with this graft. We report on the experience of a 68-year-old man, successfully treated for type B aortic dissection using the sutureless technique, who developed a pseudoaneurysm and aortobronchial fistula over the distal anastomosis of the intraluminal graft 12 years after the operation. (*Chang Gung Med J* 2004;27:614-7)

**Key words:** intraluminal graft, pseudoaneurysm, aortic dissection.

Surgery for aortic dissection is associated with high mortality, in part due to intraoperative bleeding at the suture lines. A technique was devised to obviate this problem, which utilizes a sutureless ringed intraluminal graft (SRILG) that can be placed within the aorta.<sup>(1)</sup> The data in the literature suggest that sutureless fixation shortens aortic cross-clamp time and reduces blood loss.<sup>(1-3)</sup> Early graft-related complications were few; however, there are anecdotal references to late complications, mostly related to faulty techniques, but some may be related to flaws inherent in the concept of sutureless grafting.<sup>(4,5)</sup> We report on the experience with a re-repair of the descending thoracic aorta in a 68-year-old man, initially treated successfully for type B aortic dissection by the SRILG technique, who developed an aortobronchial fistula secondary to pseudoaneurysm formation over the distal spool of this particular graft 12 years after the operation.

### CASE REPORT

A 68-year-old man with a history of hyperten-

sion and who had suffered from transient severe back pain for a month, visited our service with intermittent hemoptysis. He was a victim of a type B aortic dissection with impending rupture, who had received descending thoracic aortic replacement with 20-mm SRILG at our hospital 12 years before. The computed tomographic (CT) scan during the follow-up period confirmed complete resolution of the distal false lumen (Fig. 1A), and regular antihypertensives had been prescribed with an uneventful course. The bronchoscopic examination revealed some blood clots in the left lower lobe bronchus. A CT scan and an aortogram showed pseudoaneurysm formation just distal to the previously implanted SRILG (Figs. 1B, 2).

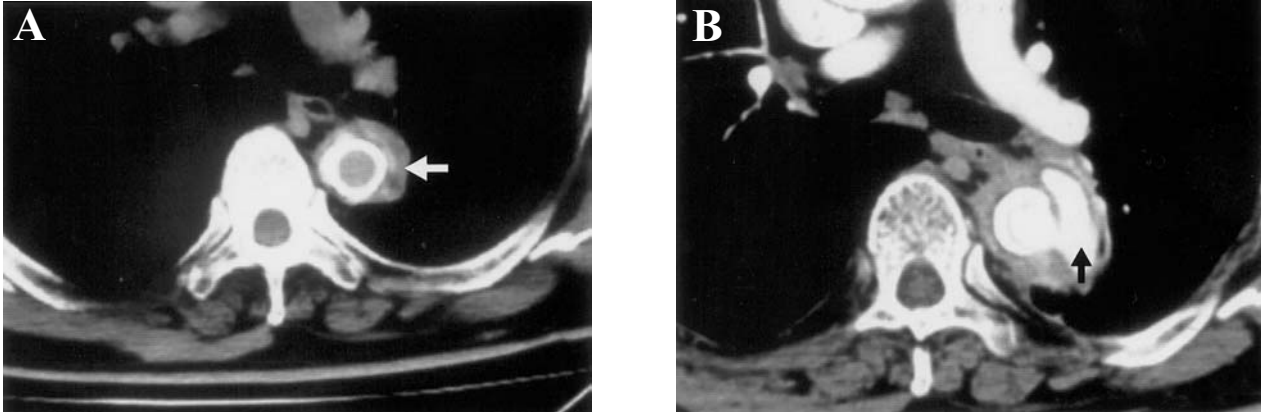
Under the impression of an aortobronchial fistula secondary to pseudoaneurysm formation over the distal spool ligature site, a reoperation was performed. Under femorofemoral bypass and hypothermic circulatory arrest, the superior segment of the left lower lobe of the lung was resected through the prior left thoracotomy with a tightly adherent pseudoaneurysmal wall. An intimal tear, 15 mm in

---

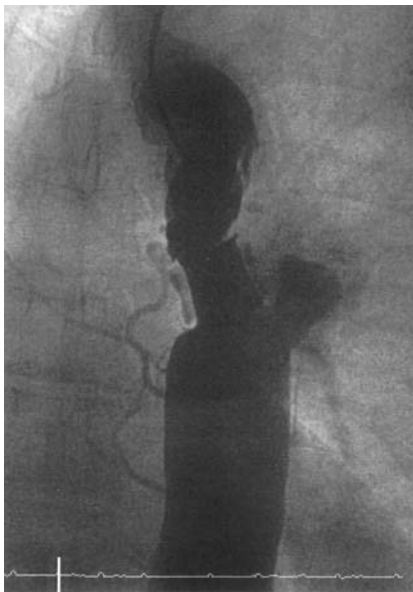
From the Division of Thoracic and Cardiovascular Surgery, Department of Surgery, Chang Gung Memorial Hospital, Kaohsiung.

Received: Jul. 10, 2003; Accepted: Dec. 5, 2003

Address for reprints: Dr. Jen-Ping Chang, the Division of Thoracic and Cardiovascular Surgery, Department of Surgery, Chang Gung Memorial Hospital, 123, Dabi Road, Niasung Shiang, Kaohsiung, Taiwan 833, R.O.C. Tel.: 886-7-7317123 ext. 8003; Fax: 886-7-7318762; E-mail: c9112772@cgmh.org.tw



**Fig. 1** (A) Computed tomographic scan during follow-up after the first operation confirming complete resolution of the distal false lumen (arrow). (B) Computed tomographic scan showing pseudoaneurysm formation around the previously implanted intraluminal graft (black arrow).



**Fig. 2** Aortogram showing pseudoaneurysm formation just distal to the ligated spool.

diameter, located just distal to the previously ligated spool was confirmed as the origin of this lesion. The spool was removed and a 20-mm Hemashield woven graft (Meadox Medicals, Oakland, NJ, USA) was interposed between the woven tubular Dacron portion of the SRILG and the distal aorta. The patient was then weaned off cardiopulmonary bypass. The postoperative course was uneventful, and he was discharged 10 days later.

## DISCUSSION

Surgery for aortic dissection has been associated with high mortality. An SRILG implantation technique has been devised to obviate this problem.<sup>(1)</sup> An SRILG, made of woven tubular Dacron with cloth-covered grooved spools at both ends, has been used as a substitute for the aorta with the advantage of decreasing the aortic cross-clamp time and blood loss. Although the reported short- and mid-term clinical outcomes may be preferable,<sup>(1-3)</sup> potential problems are still of concern including anastomotic leaks, migration, hemolysis, thromboembolism, and pseudoaneurysm formation from erosion or tears due to shear forces related to the rigid ring, or from pressure necrosis produced by fixation ligatures.<sup>(6)</sup> Although the reported pathological findings have alleviated concerns about those potential problems,<sup>(7)</sup> the implications of anecdotal accounts about late complications remain to be determined. Some technical modifications, using a vascular prosthesis or Teflon wrapping of the site of implantation of the rings have been reported in order to improve the stability of the prosthesis, promote hemostasis, and prevent such late complications as aneurysm or pseudoaneurysm formation.<sup>(6)</sup> We also wrapped the rings with woven tubular Dacron in this patient.

The data in the literature suggest that SRILG is a good option for repair of aortic dissections because it reestablishes central aortic flow, obliterates the

false lumen, and permits expeditious repair with minimal trauma to friable tissues.<sup>(8)</sup> In our patient, the distal false lumen had completely been obliterated after SRILG implantation, and the graft had been stable for 12 years, but the patient eventually experienced this catastrophic late complication. We would like to sound a cautionary note about the SRILG with emphasis on careful regular follow-up of this particular graft, even if it seems stable and functions well for a decade.

Determining whether or not the ring should be removed is of utmost concern for the repair of a perirring pseudoaneurysm. We believe that a simple patch aortorrhaphy should not be the procedure of choice in this circumstance. The retained ring will maintain an irregular inner surface which might be a causative agent for generating a lot of turbulence. This might have caused intimal lesions as in our patient, as well as possibly encouraging hemolysis or migration. We believe that the ring should be removed, and a direct suture anastomosis with a plain graft interpositional between the preexisting woven tubular Dacron part of the SRILG and the intact distal aorta is an appropriate choice in this particular situation. The suture technique is very simple and straightforward, so there is a lot less fumbling during the complicated reoperation. In conclusion, indications for SRILG implantation are quite limited and implications of anecdotal accounts about late complications remain to be determined.

## REFERENCES

1. Lemole GM, Strong MD, Spagna PM, Karmilovicz NP. Improved results for dissecting aneurysm. Intraluminal sutureless prosthesis. *J Thorac Cardiovasc Surg* 1982;83:249-55.
2. Liu DW, Lin PJ, Chang CH. Treatment of acute type A aortic dissection with intraluminal sutureless prosthesis. *Ann Thorac Surg* 1994;57:987-91.
3. Berger RL, Karlson KJ, Dunton RF, Leonardi HK. Replacement of the thoracic aorta with intraluminal sutureless prosthesis. *Ann Thorac Surg* 1992;53:920-7.
4. Apostolakis E. Acute postoperative obstruction of the ascending aorta following replacement with an intraluminal graft. *Cardiovasc Surg* 1995;3:87-9.
5. Tabayashi K, Sai S, Yoshida Y, Akino Y, Itoh Y, Uchida N, Ohmi M, Mohri H. Thoracic aortic aneurysmectomy with a sutureless intraluminal ringed graft. *Cardiovasc Surg* 1994;2:451-5.
6. Lansman SL, Ergin MA, Galla JD, Taylor MA, Griep RB. Intraluminal graft repair of ascending, arch, descending and thoracoabdominal aortic segments for dissecting and aneurysmal disease: long-term follow-up. *Semin Thorac Cardiovasc Surg* 1991;3:180-2.
7. Kanabuchi K, Koide S, Kawada S, Shohtsu A. Pathological findings of the aortic wall at the site of ligation against the rigid rings of an intraluminal graft for acute DeBakey type I aortic dissection. *Nippon Kyobu Geka Gakkai Zasshi* 1989;37:2020-4.
8. Diehl JT, Moon B, LeClerc Y, Wiesel RD, Salerno TA, Goldman BS. Acute type A dissection of the aorta: surgical management with the sutureless intraluminal prosthesis. *Ann Thorac Surg* 1987;43:502-7.

# 帶環管內人工血管置換B型主動脈剝離12年後 併發假性主動脈瘤

張仁平 呂宏益 謝敏暉 高炯倫 吳炯仁

免縫式帶環管內人工血管曾因為可減少主動脈遮斷時間及流血量而用作主動脈代用品。其長期追蹤報告及晚期併發症仍是學界所關心的題目。本篇報告一位68歲男性，因急性B型主動脈剝離，曾使用此免縫式帶環管內人工血管成功治癒。事隔12年後，於此免縫式帶環管內人工血管之遠端併發假性主動脈瘤及主動脈氣管瘻管而咳血，經再手術而治癒之經過。(長庚醫誌 2004;27:614-7)

**關鍵字：**管內人工血管，假性主動脈瘤，主動脈剝離。

---

長庚紀念醫院 高雄院區 胸腔心臟血管外科

受文日期：民國92年7月10日；接受刊載：民國92年12月5日。

索取抽印本處：張仁平醫師，長庚紀念醫院 胸腔心臟血管外科。高雄縣833鳥松鄉大埤路123號。Tel.: (07)7317123轉8003; Fax: (07)7318762; E-mail: c9112772@cgmh.org.tw