

## Tension Pneumoperitoneum Following Instrumental Perforation of an Obstructed Esophagus in an Infant

Chih-Cheng Luo, MD; Man-Shan Kong<sup>1</sup>, MD; Hsun-Chin Chao<sup>1</sup>, MD;  
Wan-Jao Wu<sup>1</sup>, MD

A 4-month-old infant was diagnosed with esophageal atresia and tracheoesophageal fistula. He was admitted to our hospital because of progressive poor findings and repeated aspiration pneumonia after surgical repair. An esophagogram demonstrated severe esophageal stricture. Flexible endoscopic dilatation was performed under general anesthesia, but sudden onset respiratory distress and progressive abdominal distention were noted during the procedure. Abdominal radiographic study revealed severe pneumoperitoneum. Tension pneumoperitoneum after perforation of the obstructed esophagus is extremely rare but life threatening. We herein report our experience with the successful management of this complication in an infant. (*Chang Gung Med J* 2003;26:768-71)

**Key words:** pneumoperitoneum, esophageal perforation.

Esophageal perforation is a well-known entity in adults, while it is relatively uncommon in infants and children. Instrumental perforation and spontaneous perforation remain the 2 major causes of esophageal injury in infants and children. Esophageal perforation due to instrumentation is a life-threatening complication. Incidences of morbidity and mortality are directly related to delays in diagnosis and treatment. Fever, dyspnea, tachypnea, and subcutaneous emphysema are clinical clues leading to a diagnosis of esophageal perforation. We recently encountered a pediatric case with severe tension pneumoperitoneum and respiratory distress following dilatation of an obstructed esophagus, which necessitated an emergency esophagectomy. We herein report this rare case, and review the related literature.

### CASE REPORT

A 4-month-old infant, weighing 4.2 kg, suffered from esophageal atresia with a tracheoesophageal fistula and had received esophageal repair after birth at another hospital. The male patient was delivered vaginally after a 36-week gestation with a birth body weight of 3.2 kg. His Apgar scores were 5 at 1 min and 8 at 5 min after birth. The patient experienced progressively poor feeding and repeated aspiration pneumonia after the operation. The esophagogram demonstrated severe esophageal stricture at the anastomotic site (Fig. 1). Flexible endoscopic dilatation was performed under general anesthesia by a gastroenterologist. The patient experienced sudden onset respiratory distress and progressive abdominal distention during the procedure. Two #18 needles

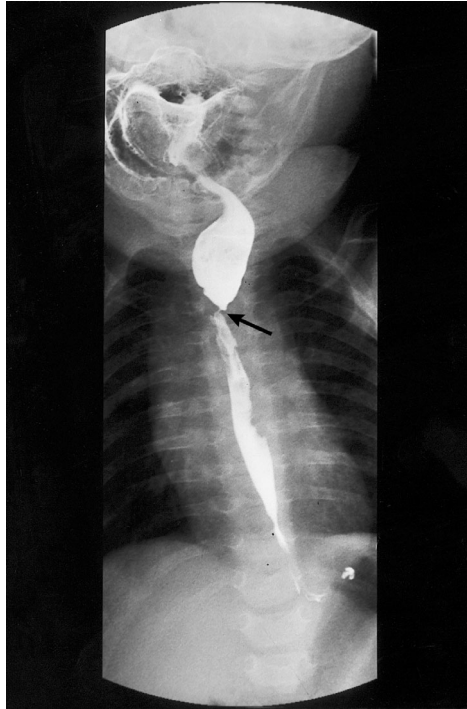---

From the Department of Pediatric Surgery, <sup>1</sup>Department of Pediatrics, Chang Gung Children's Hospital, Taipei; Chang Gung University, Taoyuan.

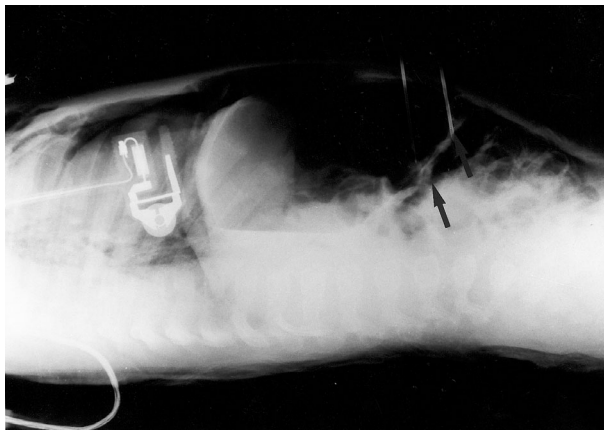
Received: Dec. 13, 2002; Accepted: Mar. 28, 2003

Address for reprints: Dr. Chih-Cheng Luo, Department of Pediatric Surgery, Chang Gung Children's Hospital, 5-7, Fushing Street, Gueishan Shiang, Taoyuan, Taiwan 333, R.O.C. Tel.: 886-3-3281200 ext. 8227; Fax: 886-3-3288957; E-mail: lifen@cgmh.org.tw

were inserted into the upper abdomen under the suspicion of tension pneumoperitoneum. The radiological examination revealed severe pneumomediastinum and pneumoperitoneum (Fig. 2). An esophagogram was not arranged because of the critical condition. An emergent right thoracotomy along the previous operative scar was performed through an



**Fig. 1** Contrast study of the esophagus demonstrating esophageal stricture (arrow) before the dilatation procedure.



**Fig. 2** The infant with tension pneumoperitoneum which was relieved by insertion of two #18 needles (arrows).

intrapleural approach to find the tear in the esophagus, which was just proximal to the stenotic region. The perforated esophagus required resection and reanastomosis without tension using a single layer of interrupted 5-0 Vicryl sutures, therefore no other conduit was needed. Chest drainage was accomplished using a #12 thoracotomy tube. An esophagogram on postoperative day 10 showed no leakage, and the patient was discharged on the 16th postoperative day, at which time he was tolerating a formula diet. A follow-up esophagogram showed no evidence of a stricture, and the infant has had normal swallowing function. The body weight had increased to 7.4 kg at 9 months old (10th-25th percentile).

## DISCUSSION

Esophageal perforation in adults is a serious and often catastrophic condition, requiring urgent surgical intervention. It is regarded by many as the most serious perforation of the intestinal tract, and the most rapidly fatal, if not diagnosed promptly and operated on early.<sup>(1,2)</sup> Numerous options are available for the management of esophageal injuries, including nonoperative treatment, primary repair, an esophagectomy, and exclusion and diversion.<sup>(3)</sup> Direct repair of the perforation with tissue buttress reinforcement is the preferred approach in children. Primary repair helps avoid the need for a reoperation to restore esophageal continuity and has been associated with a reduction in mortality rates from esophageal injuries.<sup>(4)</sup>

Instrumental perforation of the esophagus with distal obstruction is a complex problem. The lumen of the esophagus is constantly in communication with the mediastinum and pleural cavity. Perforation leads to contamination of the 2 compartments with oral secretions. Thus, both chemical and bacterial invasion ensues with localized or widespread infection and, if left untreated, it is usually rapidly fatal. The stenotic lesion also needs to be treated together with the perforation. Resection, although aggressive, has been found to be most helpful in such cases. This was proven by Moghissi and Pender<sup>(5)</sup> who reported a mortality rate of 83% among 12 patients with prestenotic perforations treated by various forms of conservative management, including primary closure and drainage. For the other 11, in whom

the obstruction was resected, a reduction in the mortality rate to 18% was observed.

Esophageal stricture is a common complication of anastomosis of the esophagus in children with esophageal atresia. Sequential dilatation of esophageal stricture is the treatment of choice as described in our case. The most common iatrogenic complication of stricture dilatation is instrumental esophageal perforation. A review of the literature<sup>(6)</sup> revealed that fever, dyspnea, tachypnea, dysphagia, and subcutaneous emphysema are common clinical presentations. Tension pneumoperitoneum with severe respiratory distress occurring during dilatation of an esophageal stricture under general anesthesia is unusual. We postulated that it occurred partly because of air inflation from the endoscopic procedure, and partly because of a previous extrapleural approach for esophageal repair, such that most of the air leaked from the pleura and chest wall to the abdomen. The emergent needle tapping to relieve tension pneumoperitoneum is life saving for such patients. Since the condition in our case was recognized early, a right thoracotomy with resection and reconstruction of the esophagus was immediately

performed, with an uneventful recovery. This report highlights the importance of immediate and aggressive operative treatment for tension pneumoperitoneum after instrumental perforation of the obstructed intrathoracic esophagus.

## REFERENCES

1. Foster JH, Jolly PC, Sawyers JL, Daily WJ. Esophageal perforations: diagnosis and treatment. *Ann Surg* 1965; 161:701-9.
2. Sarr MG, Pemberton JH, Payne WS. Management of instrumental perforations of the esophagus. *J Thorac Surg* 1982;84:211-8.
3. Engum SA, Grosfeld JL, West KW. Improved survival in children with esophageal perforation. *Arch Surg* 1996; 131:604-11.
4. Bufkin BL, Miller JI, Mansour KA. Esophageal perforation: emphasis on management. *Ann Thorac Surg* 1996; 61:1447-52.
5. Moghissi K, Pender D. Instrumental perforations of the esophagus and their management. *Thorax* 1988;43:642-6.
6. Whyte RI, Iannettoni MD, Orringer MB. Intrathoracic esophageal perforation: the merit of primary repair. *J Thorac Cardiovasc Surg* 1995;109:140-6.

## 器械性破裂發生於嬰兒阻塞性食道而導致緊張性氣腹

駱至誠 江文山<sup>1</sup> 趙舜卿<sup>1</sup> 吳宛昭<sup>1</sup>

四個月大的嬰孩因食道閉鎖併食道氣管瘻管，出生時在外院接受修復手術。術後因餵食不佳及復發性肺炎而住進我們醫院。食道攝影顯示嚴重的食道狹窄，在麻醉下接受食道鏡的擴張術，術中發生突發性的呼吸窘迫併腹部腫脹。X光檢查顯示嚴重的氣腹。嬰兒胸腔內的食道破裂而導致緊張性氣腹的臨床表現非常罕見。我們報告一例食道狹窄作食道擴張時破裂而併發緊張性氣腹而且治療成功的病例。(長庚醫誌 2003;26:768-71)

**關鍵字：**緊張性氣腹，食道破裂。

---

長庚兒童醫院 台北院區 兒童外科，<sup>1</sup>兒童內科；長庚大學 醫學院

受文日期：民國91年12月13日；接受刊載：民國92年3月28日。

索取抽印本處：駱至誠醫師，長庚兒童醫院 兒童外科。桃園縣333龜山鄉復興街5-7號。Tel.: (03)3281200轉8227; Fax: (03)3288957; E-mail: lifen@cgmh.org.tw