

Early Postoperative Capsular Block Syndrome

Jau-Der Ho, MD; Jiahn-Shing Lee, MD, PhD; Hung-Chiao Chen, MD;
Cheng-Lien Ho, MD; San-Ni Chen, MD

Background: Postoperative capsular block syndrome (CBS) is a unique and rare complication of continuous curvilinear capsulorhexis (CCC). The purpose of this study was to analyze the clinical characteristics and results of early postoperative CBS.

Methods: Patients who developed early postoperative CBS after cataract surgery from October 1998 through September 2002 were retrospectively identified. All eyes underwent smooth phacoemulsification after anterior CCC. An intraocular lens (IOL) was implanted into the capsular bag. Neodymium:YAG (Nd:YAG) laser peripheral anterior capsulotomy or posterior capsulotomy was performed when resolution did not occur or the intraocular pressure was elevated.

Results: Eight eyes of eight patients were included in the study. These patients presented with a shallow anterior chamber, anteriorly displaced IOL, distended capsular bag, and myopic shift within the first week after the surgery. One eye was associated with secondary angle-closure glaucoma. No CBS resolved without intervention during the follow-up period. The Nd:YAG laser peripheral anterior capsulotomy (4 eyes) and posterior capsulotomy (4 eyes) were successful in resolving the CBS in all eyes, and normalized the intraocular pressure in the eye with secondary angle-closure glaucoma.

Conclusion: Postoperative CBS did not resolve spontaneously in most cases. Only a small percentage of early postoperative CBS was associated with secondary glaucoma. The Nd:YAG laser peripheral anterior capsulotomy and posterior capsulotomy were successful in treating postoperative CBS.

(*Chang Gung Med J* 2003;26:745-53)

Key words: capsular block syndrome, continuous curvilinear capsulorhexis, phacoemulsification, cataract.

Capsular block syndrome (CBS) is a unique and rare complication of cataract surgery with implantation of a posterior chamber intraocular lens (PCIOL) after an anterior continuous curvilinear capsulorhexis (CCC). It is characterized by capsular hyperextension, intraocular lens (IOL) displacement

anteriorly, anterior chamber shallowing, and unexpected postoperative myopic shift in refractive status. It was first described by Davison.⁽¹⁾ Holtz and Masket each reported similar cases.^(2,3) It has also been reported to have developed during cataract surgery⁽⁴⁾ and even years after cataract surgery.^(5,6)

From the Department of Ophthalmology, Chang Gung Memorial Hospital, Taipei.

Received: Apr. 24, 2003; Accepted: Jun. 9, 2003

Address for reprints: Dr. San-Ni Chen, Department of Ophthalmology, Chang Gung Memorial Hospital, 5, Fushing Street, Gueishan Shiang, Taoyuan, Taiwan 333, R.O.C. Tel.: 886-3-3281200 ext. 8666; Fax: 886-3-3287798; E-mail: jauder@adm.cgmh.org.tw

Miyake and associates proposed a classification of CBS (intraoperative, early postoperative, and late postoperative) based on the time of onset.⁽⁷⁾ The methods of treatment differ for each type. Yeoh and Theng further divided the intraoperative type into two stages.⁽⁸⁾ Our current study was restricted to cases with early postoperative CBS (onset between 1 day and 2 weeks after the surgery).

CBS is characterized by blockage of viscoelastic substance or particulate matter within the capsular bag.^(9,10) The contents are prevented from passing between the optic the IOL and the anterior capsule. They possibly draw in water and lead to capsular expansion, anterior displacement of IOL and iris diaphragm, anterior chamber shallowing, unexpected postoperative myopic shift in refraction, as well as increased space between the IOL and the posterior capsule of the crystalline lens.^(11,12) The treatment of CBS includes neodymium:YAG (Nd:YAG) laser peripheral anterior capsulotomy and posterior capsulotomy. In this study, we present eight cases of postoperative CBS noted within a 4-year period. All eyes had typical presentations of CBS. Only one eye developed elevated intraocular pressure. CBS resolved in all eyes after Nd:YAG laser anterior capsulotomy or posterior capsulotomy.

METHODS

We retrospectively reviewed and analyzed the medical records of eight eyes in eight patients with CBS after phacoemulsification and IOL implantation, which were performed between October 1998 and September 2002. Patients with capsular distension, anterior chamber shallowing, anterior displacement of the IOL and iris diaphragm, occlusion of the anterior capsular opening by the IOL and onset within 2 weeks after the surgery were included in this study.

All of these cases underwent smooth phacoemulsification using a 2-handed technique after anterior CCC. After removal of the cortical materials, viscoelastic material was injected into the capsular bag. The viscoelastic materials used included sodium hyaluronate 3%-chondroitin sulfate 4% (Viscoat®, Alcon, Fort Worth, Tex, USA) and 1.4% sodium hyaluronate (Healon GV®, Pharmacia, Kalamazoo, Mich, USA). The IOL was implanted into the capsular bag. The viscoelastic material was

then removed and the wound was closed using 10-0 nylon or without any suture. Patients were followed on the first postoperative day, weekly for the first month, monthly to bimonthly for 6 months and as indicated by clinical condition. Examination included refraction, best corrected visual acuity, slit lamp biomicroscopy of the anterior segment, intraocular pressure measurement by pneumatic tonometer, and fundus examination. Once the CBS was diagnosed, the eye was followed up first without laser intervention unless it was associated with secondary glaucoma. The Nd:YAG laser anterior capsulotomy or posterior capsulotomy was performed at least 1 month after the operation, except in one case that was associated with secondary glaucoma.

RESULTS

All eight patients (3 men and 5 women) had nuclear sclerosis with posterior subcapsular opacity preoperatively in the operated eyes. The mean age was 68.4 ± 7.4 years old (from 59 to 83 years old). The patient characteristics are summarized in Table 1. Polymethyl methacrylate PMMA IOLs (812A, Pharmacia) were implanted in two eyes. The other eyes were implanted with foldable acrylic IOLs (MB30BA, Alcon). The CCC size ranged from 4.5 to 5 mm. The viscoelastic materials used included sodium hyaluronate 3%-chondroitin sulfate 4% (Viscoat®) in six eyes and 1.4% sodium hyaluronate (Healon GV®) in two eyes. One eye was associated with secondary angle-closure glaucoma. The others had normal intraocular pressure during the follow-up period. No CBS resolved without intervention during the follow-up period (>1 month after the diagnosis for the eyes with normal intraocular pressure). The Nd:YAG laser anterior capsulotomy (4 eyes) and posterior capsulotomy (4 eyes) were successful in resolving the CBS in all eyes, and normalized the intraocular pressure in the eye with secondary angle-closure glaucoma. All eyes were associated with myopic refractive error (spherical equivalent of -3.38 (0.82 D) in the presence of CBS. This myopic shift was reduced after laser capsulotomy (spherical equivalent of -0.44 ± 0.87 D).

Case 1

A 72-year-old woman with history of coronary artery disease presented with gradual blurring of

Table 1. Clinical Characteristics on Eight Cases with Early Postoperative Capsular Block Syndrome

Patient No.	Age (years)/ Sex	BCVA		Refractive Status (D)		IOP (mmHg)	
		pre-Nd:YAG	post-Nd:YAG	pre-Nd:YAG	post-Nd:YAG	pre-Nd:YAG	post-Nd:YAG
1	72/F	0.9	1.0	-3.0 -1.75 × 166	+0.5 -0.25 × 10	11	10
2	65/F	0.6	0.9	-2.25-1.0 × 20	- 0.5 -0.5 × 30	11	14
3	59/F	0.5	0.7	-3.25-1.0 × 90	- 0.25-0.5 × 75	10	15
4	65/M	0.1	0.7	-1.25-1.25 × 33	+1.0 -0.5 × 15	36	10
5	71/F	0.8	0.8	-3.0 -0.75 × 15	- 0.25-0.25 × 179	16	14
6	83/M	0.4	0.5	-4.25-0.75 × 138	- 1.25-1.75 × 106	14	13
7	62/M	0.7	0.7	-3.25-0.75 × 40	- 0.75-0.25 × 11	12	16
8	70/F	0.6	0.8	-2.5 -1.25 × 105	+0.5 -1.0 × 118	10	14

Abbreviations: BCVA: best corrected visual acuity; Nd:YAG: Neodymium:YAG anterior or posterior capsulotomy; IOP: intraocular pressure.

vision in her left eye. The best corrected visual acuity was 0.1 and slit lamp examination revealed cataract with posterior capsular opacities. She underwent phacoemulsification with an acrylic IOL implantation into the bag uneventfully. Viscoat® was used during the surgery. A shallow anterior chamber was noted 1 day after the operation. There was no wound leakage and the intraocular pressure was within the reference range. The anterior chamber remained shallow and the IOL was displaced anteriorly during the follow-up period. The best corrected visual acuity 3 weeks after operation was 0.9 with -2.5-1.37 ± 156. The patient was satisfied with the near vision in her left eye. Therefore, she was followed without laser intervention. Seventeen months after the operation, the patient complained of blurred vision in the right eye which she used for far vision. Slit lamp examination revealed cataract in her right

eye. Examination of left eye still revealed a shallow anterior chamber and an anteriorly displaced PCIOL. The posterior capsule was displaced far posteriorly and the capsular bag was distended (Fig. 1A). The refraction was -3.0-1.75 ± 166. To improve the far vision in her left eye by reversing the myopic shift, Nd:YAG laser posterior capsulotomy was performed. Upon rupture of the posterior capsule by the laser, the anterior chamber deepened, the PCIOL and posterior capsule returned to its normal position (Fig. 1B). The posterior capsule returned to just behind the PCIOL. One week after the Nd:YAG laser posterior capsulotomy was performed, the best corrected visual acuity was 1.0 with +0.5-0.25 × 10.

Case 2

A 65-year-old woman with hypertension underwent phacoemulsification with PCIOL implantation

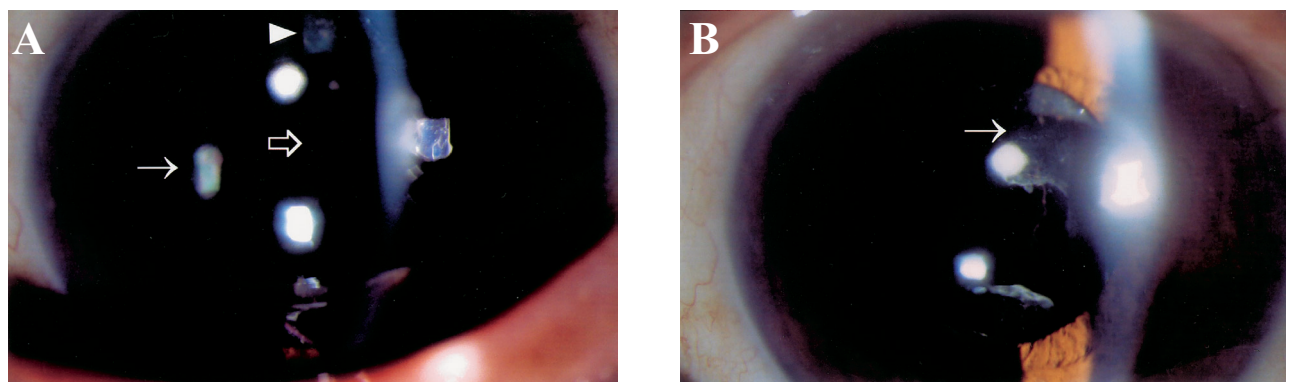


Fig. 1 Patient 1 at 17 months after the cataract surgery. (A) The posterior capsule was displaced far posteriorly (arrow) and the capsular bag was distended. The anterior capsule (arrowhead) is adhering to the optic of the IOL (hollowed arrow). (B) Immediately after the Nd:YAG laser posterior capsulotomy, the posterior capsule returned to its normal position just behind the PCIOL (arrow).

into the bag smoothly. Viscoat® was used during the surgery. One week after the surgery, slit lamp examination revealed a shallow anterior chamber, anteriorly displaced IOL and apparent adhesion between the anterior capsule opening and the PCIOL. The intraocular pressure was 11 mmHg and the best corrected visual acuity was 0.6 with $-2.25-1.0 \times 20$. These presentations persisted for 4 weeks. Nd:YAG laser posterior capsulotomy was performed. The anterior chamber deepened immediately after the capsulotomy. The best corrected visual acuity was 0.9 with $-0.5-0.5 \times 30$.

Case 3

A 59-year-old woman with diabetes mellitus was diagnosed with cataract in the right eye. The best-corrected visual acuity preoperatively was 0.08. Phacoemulsification with implantation of an acrylic foldable IOL in the capsular bag using Viscoat® was performed in the right eye uneventfully. Shallowing of anterior chamber with anterior displacement of PCIOL was noted 2 days after the operation. The wound was intact without leakage. Mydriatics was administered, however, the shallowing of anterior chamber did not improve. The anterior chamber remained shallow for 3 weeks after the operation. The refraction was $-3.25-1.0 \times 90$ and the best cor-

rected visual acuity was 0.5. Gonioscopic examination revealed neither peripheral anterior synchiae nor angle neovascularization. The intraocular pressure remained within reference range. The anterior chamber had become shallower at 6 weeks after the operation. The capsular bag was markedly distended and the posterior capsule was located far behind the IOL. Ultrasound biomicroscopy showed a shallow anterior chamber, iridopseudophakic touch, and capsular bag distension (Fig. 2A). The intraocular pressure remained normal (10 mmHg). Nd:YAG laser anterior capsulotomy was performed to open the capsular block. The anterior chamber deepened and the iris was separated from the IOL after the anterior capsulotomy (Fig. 2B). The myopia was also reduced (refraction: $-0.25-0.5 \times 75$).

Case 4

A 65-year-old man with cataract received phacoemulsification after CCC in the right eye smoothly. An acrylic foldable IOL of 21.5 D was implanted in the bag. The axial length was 22.45 mm. The preoperative intraocular pressure was 11.5 mmHg. The patient reported ocular fullness sensation and blurred vision 3 days after the operation. On slit lamp examination, the cornea appeared edematous. The capsular opening was apparently adhering to the

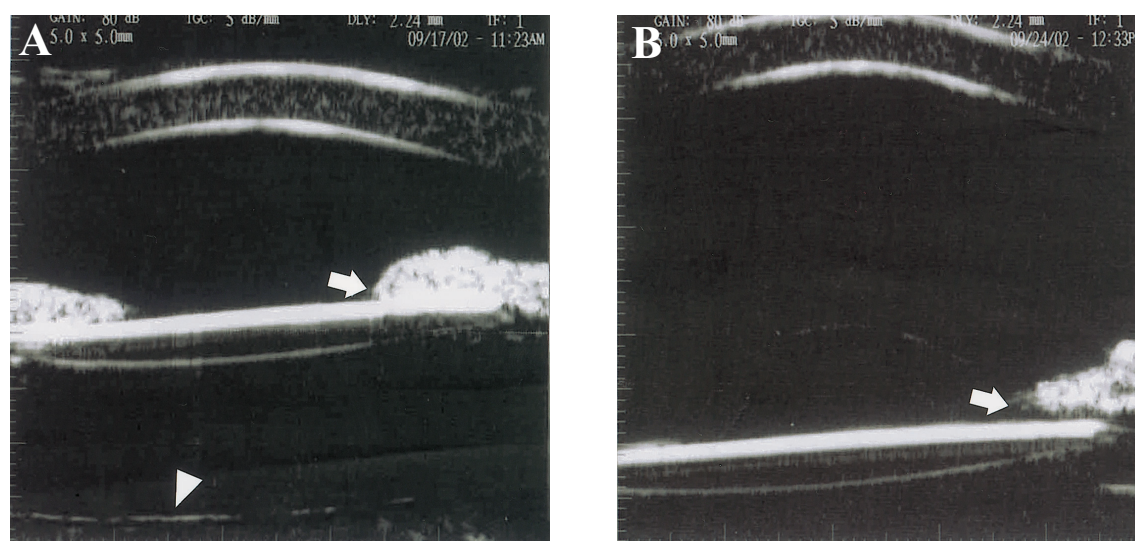


Fig. 2 Ultrasound biomicroscopy of patient 3. (A) Six weeks after the cataract surgery, the anterior chamber is shallow. There was iridopseudophakic touch (arrow) with capsular bag distension. The posterior capsule (arrowhead) is displaced far behind the PCIOL. (B) One week after Nd:YAG laser anterior capsulotomy, the anterior chamber deepened and the iris is separated from the IOL (arrow).

IOL optic. The capsular bag was distended with the posterior capsule far behind the IOL optic. The anterior chamber was uniformly shallow (Fig. 3A, B). The intraocular pressure was 36 mmHg and the best corrected visual acuity was 0.1 with $-1.25-1.25 \times 33$. A clinical diagnosis of CBS associated with secondary angle-closure glaucoma was made. Nd:YAG laser anterior capsulotomy was performed. The distended capsular bag collapsed and the anterior chamber deepened a little immediately after the laser treatment (Fig. 3C). Five days after the laser treatment, the best corrected visual acuity was 0.7 with $+1.0-0.5 \times 15$ and intraocular pressure returned to reference range (10 mmHg). Slit lamp revealed a clear cornea and a deep anterior chamber (Fig. 3D).

Case 5

A 71-year-old woman had uneventful phacoemulsification with in-the-bag PMMA IOL placement in her right eye. On the first postoperative day,

mild shallowing of the anterior chamber was noted. No wound leakage was found. There was a large space between the anteriorly displaced IOL and the posteriorly displaced posterior capsule. She was followed without laser intervention. Six weeks after the operation, the best corrected visual acuity was 0.8 with $-3.0-0.75 \times 15$. Nd:YAG anterior capsulotomy was performed. The anterior chamber deepened. The best corrected visual acuity was 0.8 with $-0.25-0.25 \times 179$ one week after the capsulotomy.

Case 6

An 83-year-old man with cataract received phacoemulsification and in-the-bag implantation of an acrylic IOL in his left eye. The operative course was smooth. A shallow and clear anterior chamber and a distended capsular bag were noted at 1 week after the operation. The anterior chamber remained shallow for another 5 weeks. The intraocular pressure was 14 mmHg. The PCIOL shifted anteriorly. The

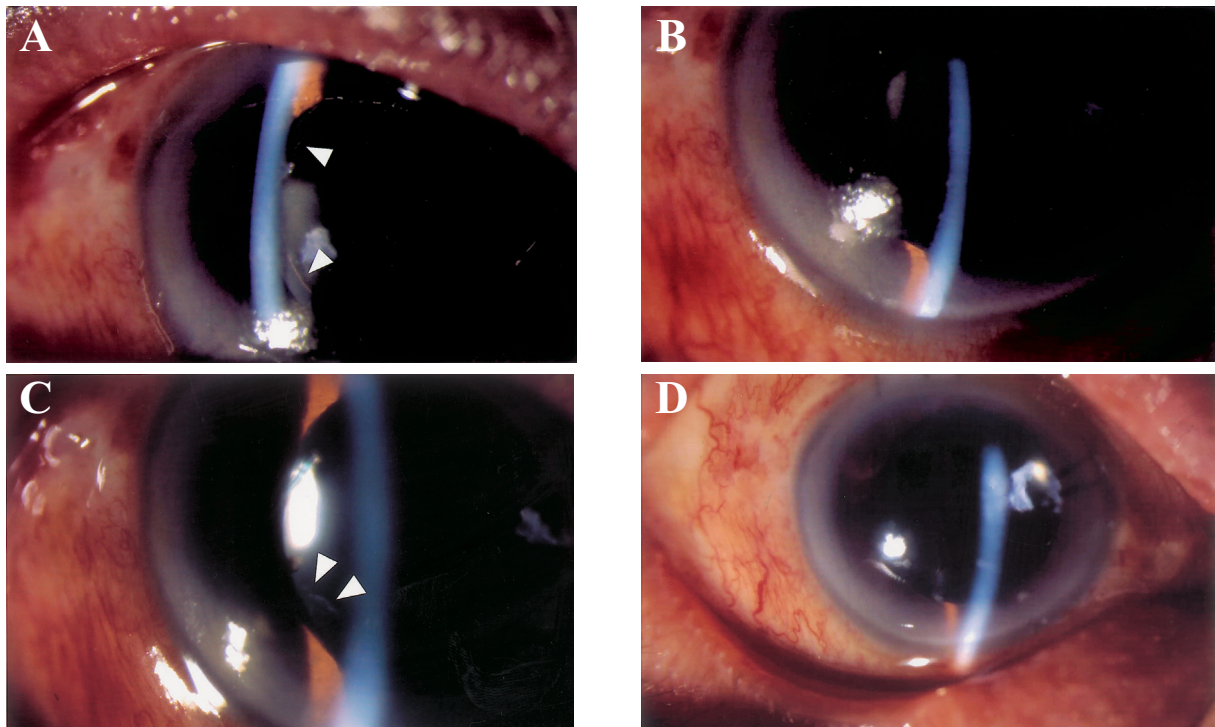


Fig. 3 Patient 4 at 3 days after the cataract surgery. (A, B) The capsular opening is apparently adhering to the IOL optic (arrowhead). The anterior chamber is uniformly shallow, and the cornea appears edematous. (C) Immediately after Nd:YAG laser peripheral anterior capsulotomy, the anterior chamber deepened a little and the CCC margin was disrupted by the laser (arrowhead). (D) Five days after Nd:YAG laser anterior capsulotomy, the anterior chamber deepened and the cornea is clear.

refraction was $-4.25-0.75 \times 138$. Under the impression of CBS, Nd:YAG laser posterior capsulotomy was done. The anterior chamber deepened immediately after the capsulotomy and the refraction changed to $-1.25-1.75 \times 106$.

Case 7

A 62-year-old man complained of blurred vision in his right eye. Cataract was diagnosed and the best corrected visual acuity was 0.1. He underwent phacoemulsification with a PMMA PCIOL implantation into the capsular bag. There was no rupture of the lens capsule during the surgery. Healon GV[®] was used in the surgery. Shallow anterior chamber was found 1 week after the operation. The PCIOL was displaced anteriorly. The best corrected visual acuity was 0.7 with $-3.25-0.75 \times 40$. The intraocular pressure was 12 mmHg. These signs persisted for another 1 month while the intraocular pressure remained within reference range. Nd:YAG laser anterior capsulotomy was performed. The anterior chamber deepened and the PCIOL returned back to a normal position. The best corrected visual acuity was 0.7 with $-0.75-0.25 \times 11$ at 1 month after the laser capsulotomy.

Case 8

A 70-year-old woman underwent uneventful phacoemulsification with in-the-bag acrylic foldable IOL implantation in her left eye. Shallow anterior chamber, anteriorly displaced PCIOL, and distended capsular bag was found 1 week after the operation. No wound leakage was noted. Two months after the cataract surgery, the best corrected visual acuity was 0.6 with $-2.5-1.25 \times 105$. Under the diagnosis of CBS, Nd:YAG posterior capsulotomy was performed. The anterior chamber deepened. The best corrected visual acuity was 0.8 with $+0.5-1.0 \times 118$ 1 week after the capsulotomy.

DISCUSSION

In the eight cases of CBS included in this study, standard phacoemulsification and in-the-bag PCIOL implantation were performed smoothly after an intact CCC. The CCC size ranged from 4.5 to 5 mm in diameter and tended to be small. This made it possible to have the entire edge of the IOL optic in contact with the anterior capsule. This phenomenon was

observed in all cases in this study. Viscoelastic materials were used in all of the patients. Viscoat was used in six cases and Healon GV was used in two cases. The IOL used included acrylic foldable IOL (6 eyes) and one-piece PMMA IOL (2 eyes). The CBS resolved in all cases after Nd:YAG anterior peripheral capsulotomy or posterior capsulotomy.

When performing phacoemulsification, CCC is the preferred and most popular method of anterior capsulotomy.⁽¹³⁻¹⁵⁾ CCC helps maintain the integrity of the capsule during the surgery. It also made it possible to insert the PCIOL in the capsular bag securely, and reduce the incidence of IOL malposition. However, complications unique to CCC and in-the-bag PCIOL implantation have been reported.^(1-3,5,6,10,11,16) These included CBS, which was first described by Davison⁽¹⁾ and then by Holtz⁽²⁾ as a postoperative complication of capsular bag distension. The term of capsular block syndrome was first presented by Masket.⁽³⁾ In their cases, Davison and Holtz reported that transparent liquid accumulated between the posterior capsule and PCIOL just after phacoemulsification and PCIOL implantation. Additional complications include that CBS has been observed intraoperatively, and as long as 5 years after the surgery.⁽⁴⁻⁶⁾ It has also been reported to develop after sulcus fixation of an IOL.⁽¹⁷⁻¹⁹⁾

The etiology of postoperative CBS is not clear. Davison suggested that the fluid in the capsular bag is produced by oncotic pressure created by lens epithelial cells and their proteinaceous by-products, possibly by retained cortical materials, and less likely by viscoelastic material.⁽¹⁾ Masket⁽³⁾ and Durak et al.⁽¹²⁾ suggested that the viscoelastic material retained in the capsular bag was responsible for drawing fluid into the space in the capsular bag. The accumulated liquid distended the capsular bag during the postoperative period. Sugiura et al.⁽⁹⁾ aspirated the liquid in the distended capsular bag of postoperative CBS and analyzed it using high-performance liquid chromatography. The results indicated that the major ingredient of transparent liquid in the capsular bag was sodium hyaluronate. The lens capsule acts as a barrier to large non-electrolyte molecules and an osmotic gradient across the capsule is established.⁽²⁰⁾ The aqueous humor is drawn into the capsular bag by this osmotic gradient and leads to distension of the capsular bag. The distended bag causes anterior displacement of the IOL and a myopic shift in refraction.

tion. Another possible etiology involves saccadic eye movement.^(21,22) It was suggested that a valve-like mechanism formed by the CCC rim that partially adheres to the IOL optic can occur postoperatively. Under these conditions, saccadic eye movement can increase intracapsular pressure by a unidirectional inertial displacement of fluid into the capsular bag. Since the etiology of postoperative CBS may include the residual viscoelastic material in the capsular bag that persists after the cataract operation, thorough aspiration of viscoelastic material from the posterior chamber may prevent CBS. One sign of complete removal of viscoelastic material from the capsular bag is the wrinkles that appear parallel to the IOL axis during aspiration of the viscoelastic material.⁽²³⁾

Sugiura et al.⁽⁹⁾ thought that postoperative CBS was more likely to occur when a PCIOL with a sticky surface and a heavy-molecular-weight viscoelastic material were used. However, postoperative CBS has been reported with IOL of various materials and designs.^(1-3,5-9,11,12,24) The materials of the IOLs we implanted included acrylic and PMMA. The optic diameter was 5.5 mm. The haptic angle was 5° (acrylic IOL) and 6° (PMMA IOL), respectively. The viscoelastic materials we used included Viscoat® and Healon GV®.

The clinical presentations of CBS (shallow anterior chamber, anterior displacement of the iris) may be similar to those of papillary block. In most cases of CBS, the intraocular pressure is within reference range. Seven of eight eyes in this study had normal intraocular pressure. However, one (case 4) of our patients presented with elevated intraocular pressure (36 mmHg). The association of CBS and angle-closure glaucoma has been reported.⁽²⁴⁾ The anteriorly displaced iris-PCIOL plane may cause angle closure. Therefore, close follow-up and intraocular pressure measurement is mandatory for patients with CBS.

Postoperative CBS is treated by performing an anterior peripheral capsulotomy or a posterior capsulotomy.^(1,2,5,11,12) Creating a communication between the intracapsular and extracapsular space breaks the capsular block. Resolution of the CBS returns the IOL to a normal position and reduces the myopic shift. The average reduction in the myopic shift after CBS resolution ranged from 2.52 to 3.6 D.^(2,11,12) In our study, the average reduction in the myopic shift was 2.94 D after laser capsulotomy. Holtz⁽²⁾ reported seven cases of early CBS. The CBS resolved sponta-

neously in two eyes. Nd:YAG laser anterior capsulotomy was performed successfully in three eyes. No intervention was necessary in two eyes. In another report, Omar et al.⁽¹¹⁾ described nine eyes with CBS. They performed Nd:YAG laser posterior capsulotomy in all cases with successful results. Durak et al.⁽¹²⁾ followed early postoperative CBS without intervention for 1 month. Spontaneous resolution occurred in 15.4% of their cases. In our study, no eyes were noted to have spontaneous recovery. All eyes underwent laser capsulotomy to relieve CBS. No complications of capsulotomy were found in our eight patients. Since posterior capsulotomy has the potential for complications such as cystoid macular edema and an increased risk of retinal detachment,^(25,26) it may be prudent to perform anterior capsulotomy first. The laser posterior capsulotomy can be reserved for when the CBS persists after anterior capsulotomy or when there is difficulty in performing anterior capsulotomy.

The increasing use of phacoemulsification with CCC and in-the-bag IOL implantation is likely to be accompanied by a similar increase in the number of cases of CBS. Complete aspiration of viscoelastic material from the posterior chamber may prevent CBS. Follow-up without treatment is not effective in most cases. Nd:YAG laser peripheral anterior capsulotomy or posterior capsulotomy is an effective and safe treatment.

REFERENCES

1. Davison JA. Capsular bag distension after endophacoemulsification and posterior chamber intraocular lens implantation. *J Cataract Refract Surg* 1990;16:99-108.
2. Holtz SJ. Postoperative capsular bag distension. *J Cataract Refract Surg* 1992;18:310-7.
3. Masket S. Postoperative complications of capsulorhexis. *J Cataract Ref Surg* 1993;19:721-4.
4. Updegraff SA, Peyman GA, McDonald MB. Pupillary block during cataract surgery. *Am J Ophthalmol* 1994;117:328-32.
5. Nishi O, Nishi K, Takahashi E. Capsular bag distension syndrome noted 5 years after intraocular lens implantation. *Am J Ophthalmol* 1998;125:545-7.
6. Starr MB. Capsular bag distension syndrome noted 5 years after intraocular lens implantation (letter). *Am J Ophthalmol* 1999;127:244-5.
7. Miyake K, Ota I, Ichihashi S, Miyake S, Tanaka Y, Terasaki H. New classification of capsular block syndrome. *J Cataract Refract Surg* 1998;24:1230-4.

8. Yeoh R, Theng J. Capsular block syndrome and pseudoexpulsive hemorrhage. *J Cataract Refract Surg* 2000;26:1082-4.
9. Sugiura T, Miyauchi S, Eguchi S, Obata H, Nanba H, Fugino Y, Masuda K, Akura J. Analysis of liquid accumulated in the distended capsular bag in early postoperative capsular block syndrome. *J Cataract Refract Surg* 2000;26:420-5.
10. Eifrig DE. Capsulohexis-related lacteocrumenasia. *J Cataract Refract Surg* 1997;23:450-4.
11. Omar O, Eng CT, Chang A, Durcan FJ, Liss RP, Stark BI. Capsular bag distension with an acrylic intraocular lens. *J Cataract Refract Surg* 1996;22:1365-7.
12. Durak I, Ozbek Z, Ferliel ST, Oner FH, Soylev M. Early postoperative capsular block syndrome. *J Cataract Refract Surg* 2001;27:555-9.
13. Gimbel HV. Divide and conquer nucleofractis phacoemulsification: development and variations. *J Cataract Refract Surg*. 1991;17:281-91.
14. Koch PS. Techniques and instruments for cataract surgery. *Curr Opin Ophthalmol*. 1994;5:33-9.
15. Gimbel HV, Neuhann T. Development, advantages, and methods of the continuous circular capsulorhexis technique. *J Cataract Refract Surg*. 1990;16:31-7.
16. Miyake K, Ota I, Miyake S, Horuguchi M. Liquefied after cataract; a complication of continuous curvilinear capsulorhexis and intraocular lens implantation in the lens capsule. *Am J Ophthalmol* 1998;125:429-35.
17. Geyer O, Goldstein M, Rothkoff L, Lazar M. Capsular bag distension associated with sulcus implantation of intraocular lenses. *J Cataract Refract Surg* 1998;24:1538-40.
18. Miyake K, Ota I, Miyake S, Terasaki H. Capsular block syndrome with external blockage of the capsular opening by a ciliary sulcus fixated posterior chamber lens. *Am J Ophthalmol* 1999;127:605-7.
19. Basti S, Nayak H, Mathur U. Capsular bag distention after optic capture of a sulcus-fixated intraocular lens. *J Cataract Refract Surg* 1999;25:293-5.
20. Ozaki L. The barrier function of the posterior capsule. *J Am Intraocul Implant Soc* 1984;10:182-4.
21. Zacharias J. Early postoperative capsular block syndrome related to saccadic-eye-movement-induced fluid flow into the capsular bag. *J Cataract Refract Surg* 2000;26:415-9.
22. Tognetto D, Toto L, Michieli C, Ravalico G. Capsular block syndrome associated with horizontal jerk nystagmus. *J Cataract Refract Surg* 2002;28:1487-9.
23. Durak I, Oner FH. Clue to complete removal of OVD during phacoemulsification. *J Cataract Refract Surg* 2000;26:633-4.
24. Liu TY, Chou PI. Capsular block syndrome associated with secondary angle-closure glaucoma. *J Cataract Refract Surg*. 2001;27:1503-5.
25. Steinert RF, Puliafito CA, Kumar SR, Dudak SD, Patel S. Cystoid macular edema, retinal detachment, and glaucoma after Nd:YAG laser posterior capsulotomy. *Am J Ophthalmol* 1991;112:373-80.
26. Peterson AM, Bluth LL, Campion M. Delayed posterior dislocation of silicone plate-haptic lenses after neodymium:YAG capsulotomy. *J Cataract Refract Surg* 2000;26:1827-9.

早發性術後水晶體包囊阻塞症候群

何昭德 李建興 陳泓橋 何正廉 陳珊霓

- 背景：**術後水晶體包囊阻塞症候群為一和白內障手術中使用連續性前囊切開術 (CCC) 有關之獨特但罕見之併發症。本研究將探討該併發症之臨床表現及治療。
- 方法：**採回溯性研究，收集自1998年10月至2002年9月發生之早發性術後水晶體包囊阻塞症候群之病例。所有個案均曾接受超音波晶體乳化術合併人工水晶體植入，於術中均曾使用連續性前囊切開術 (CCC)。在發生該症候群後，若於追蹤期間並未自行緩解或產生眼壓升高之現象時，則施行鉗：雅各雷射前囊或後囊切開術。
- 結果：**本研究共收集4年內共8位病患〈8隻眼睛〉，這些眼睛在接受白內障手術後一週內均表現有前房變淺、人工水晶體向前位移、水晶體包囊膨脹以及近視度數加深之情況，其中一眼合併有續發性隅角閉鎖性青光眼。在追蹤期間，該症候群並無自行緩解之現象。施行鉗：雅各雷射前囊切開術〈4隻眼睛〉或後囊切開術〈4隻眼睛〉均可有效治療該症候群，並使合併有青光眼之病例之眼壓恢復正常。
- 結論：**在大部分情況下，術後水晶體包囊阻塞症候群並不會自行緩解；另一方面，只有一小部份之眼睛會合併有青光眼之現象，鉗：雅各雷射前囊或後囊切開術可以成功治療此症候群。
- (長庚醫誌 2003;26:745-53)

關鍵字：術後水晶體包囊阻塞症候群，連續性前囊切開術，超音波晶體乳化術，白內障。