

## Amniotic Membrane Grafts Following Excision of Corneal and Conjunctival Intraepithelial Neoplasia

Lung Kun Yeh, MD; Hsin Chiung Lin, MD; David Hui-Kang Ma, MD, PhD

**Background:** We evaluated the efficiency of amniotic membrane grafts (AMGs) for reconstructing the conjunctival surface following excision of corneal and conjunctival intraepithelial neoplasia (CIN).

**Methods:** This was a retrospective, noncomparative, interventional study. Five eyes in 5 patients were treated between April 1996 and September 2002 with the same procedure to apply amniotic membrane grafts after excising CIN. According to a standard protocol, the amniotic membrane was harvested and processed under sterile conditions. The amniotic membrane graft was applied over the excised bare scleral area and anchored with 10-0 nylon interrupted sutures. Patient data and clinical photographs were reviewed and analyzed.

**Results:** The mean follow-up period was 27 (range, 6-69) months. Ocular surface healing was rapid and complete in all cases. No recurrence was found.

**Conclusion:** Amniotic membrane graft is an effective and safe alternative adjunctive treatment for primary CIN. Further studies with longer follow-up are recommended to evaluate the risk of recurrence and other adverse effects.

(*Chang Gung Med J* 2003;26:737-44)

**Key words:** corneal and conjunctival intraepithelial neoplasia, amniotic membrane graft, recurrence.

Corneal and conjunctival intraepithelial neoplasias (CINs) are uncommon tumors of the ocular surface. Traditionally, these lesions were regularly treated with complete surgical excision with or without adjunctive therapy in an effort to reduce the rate of recurrence. However, the recurrent rate may reach 50% of cases when the pathology of the excised margin is not confirmed.<sup>(1)</sup> Many adjunctive treatments such as cryotherapy, beta irradiation, Mohs' technique, mitomycin-C, 5-fluorouracil, and interferon have been introduced to try to reduce the recurrence rate.<sup>(1-6)</sup> However, potential complications resulting from adjunctive therapies cannot be

ignored. In this report, we present patients with pathologically proven CIN treated with amniotic membrane grafts following primary surgical excision of their lesions. Our results show satisfactory outcomes for conjunctival surface reconstruction by amniotic membrane grafts.

### METHODS

#### Patients

Five patients were included in this study between April 1996 and September 2002. Informed consent from all patients was obtained prior to the

---

From the Department of Ophthalmology, Chang Gung Memorial Hospital, Taipei.

Received: Feb. 19, 2003; Accepted: May 6, 2003

Address for reprints: Dr. David Hui-Kang Ma, Department of Ophthalmology, Chang Gung Memorial Hospital, 5, Fushing Street, Gueishan Shiang, Taoyuan, Taiwan 333, R.O.C. Tel.: 886-3-3281200 ext. 8666; Fax: 886-3-3287798; E-mail: davidhkma@yahoo.com

study. One eye in each patient was afflicted with CIN. All patients underwent the same procedure of lesion excision followed by an amniotic membrane (AM) graft. The operations were performed by two of the authors (DHKM and HCL) in Chang Gung Memorial Hospital, Linkou, Taiwan, using standard surgical procedures.

#### **Tumor excision and amniotic membrane grafting**

Under retrobulbar anesthesia, lesions were removed using the technique of a superficial keratectomy with a 3-4 mm tumor-free margin at the corneal and conjunctival side. The AM was prepared and preserved as described previously.<sup>(7,8)</sup> After 1999, to meet new US FDA requirements, AM donors were examined for human immunodeficiency virus (HIV) 6 months after delivery; the AMs were purchased from Bio-Tissue (Miami, FL, USA). The AM was sutured to the adjacent conjunctiva and episcleral tissue using interrupted 10-0 nylon sutures with the basement membrane side facing up. Following AM grafting, Maxitrol ointment (Alcon), 2 to 4 times a day, and 25 mg oral indomethacin and antacid, 4 times a day, were administered during the first week. During the second week, only Maxitrol was administered, but if there was excessive irritation due to the stitches, lubricants such as Tear Naturale or Balanced Salt Solution (Alcon) were also administered. Essentially all the stitches were removed at the end of 2 weeks. Thereafter, the eye drops were changed to 0.1% fluorometholone (CIBA Vision, Hettlingen, Switzerland) q.i.d. for 1 month, then decreased to b.i.d. for another month, and then changed to 0.02% fluorometholone (Santen, Osaka, Japan) q.i.d. to b.i.d. for the following 3 months.

#### **Pathology**

All excised tumors were sent for a pathological examination at the Department of Pathology, Chang Gung Memorial Hospital. All tumors were confirmed to be CIN.

## **RESULTS**

We studied 5 patients with pathologically proven primary CIN. A representative lesion is shown in Fig. 1A,B (case 1). Patients were treated with an AM graft following excision of their tumors.

During a follow-up period of 6 to 69 (mean,  $27 \pm 24.87$ ) months, no clinical evidence of recurrence was observed. In 2 cases, short-term hyperemia and redness occurred within the first 2 weeks after surgery. Clinical data obtained from the 5 patients are listed in Table 1. Histopathological results showed that cases 1 and 2 had carcinoma in situ (CIN, grade III) while cases 3, 4, and 5 had mild dysplasia (CIN, grade I).

#### **Case 1**

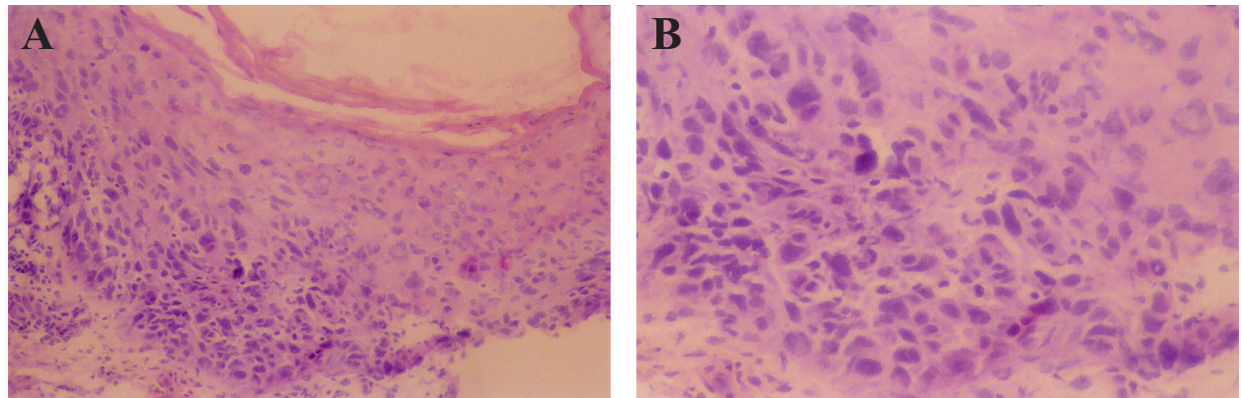
A 76-year old man was referred to our clinic with a hyperemic mass on his right eye, which he had had for months. His medical history was unremarkable. Uncorrected visual acuity was 20/100 in his right eye and 20/800 in his left eye. Biomicroscopy of his right eye showed a papilloma-like lesion with a neovascular ingrowth. The corneal lesion was 10×4 mm in size and extended from the 4- to the 8-o'clock position (Fig. 2A). He received superficial keratectomy, cryotherapy, and then AM grafting. Postoperative complications were minimal except for red eye and hyperemia within the first 2 weeks following surgery (Fig. 2B). No recurrence occurred during 69 months of follow-up.

#### **Case 2**

A 71-year-old man, with no special medical conditions, had experienced blurred vision and foreign body sensation in his right eye for 10 months. Examination showed that his visual acuity was 20/70 in his right eye and 20/50 in his left eye. Biomicroscopy showed a leukoplakic-like lesion which extended from the 7- to the 2-o'clock position (Fig. 3A, B). The conjunctival portion of the lesion measured about 10×6 mm, with a 2-mm extension into the corneal side. After tumor removal and AM grafting, there was complete reepithelialization within 15 days. To the present, the patient has been followed up for 11 months after surgery without recurrence.

#### **Case 3**

A 71-year-old woman with a history of red left eye with bloody discharge (OS) for 2 weeks was referred to our institute from a local clinic for further treatment. The corrected visual acuity in her affected eye had deteriorated to 20/100. Slit lamp biomicroscopy showed a leukoplakic pannus-like lesion



**Fig. 1** (A) Histologic sections showing soft tissue focally lined by squamous epithelium with changes of carcinoma in situ. (H&E stain; original magnification,  $\times 100$ ) (B) The epithelial layer replaced by atypical, often bizarre, pleomorphic, epithelial cells with loss of polarity. (H&E stain; original magnification,  $\times 400$ )

**Table 1.** Clinical Manifestations of Five Patients with CIN Following Excision and AMG

Case no.	Gender /age	Position (o'clock) Size (mm)	Primary treatment	Follow-up	Retreatment (month)	Recurrence	Complications
1	M/76	4 10 $\times 4$	Excision + cryotherapy + AMG, OD	69	-	-	Red eye, hyperemia
2	M/71	7 10 $\times 6$	Excision + AMG, OD	11	-	-	-
3	F/71	8 15.5 $\times 6$	Excision + cryotherapy + AMG, OS	24.5	-	-	-
4	M/74	2 4 $\times 4$	Excision + AMG, OD	24.5	-	-	-
5	F/31	2.5 5 $\times 3$	Excision + Mit-C + AMG, OD	6	-	-	Red eye

**Abbreviations:** CIN: corneal and conjunctival intraepithelial neoplasia; AMG: amniotic membrane graft; Mit-C: mitomycin-C.

with engorged vessels spanning the area from the 8- to the 4-o'clock position with a 4-mm-wide extension into the corneal side (Fig. 4A). She received superficial keratectomy, cryotherapy, and AM grafting. Complete corneal and conjunctival reepithelialization over the AM was observed in 2 weeks. There was no recurrence after 2 years of follow-up (Fig. 4B).

#### Case 4

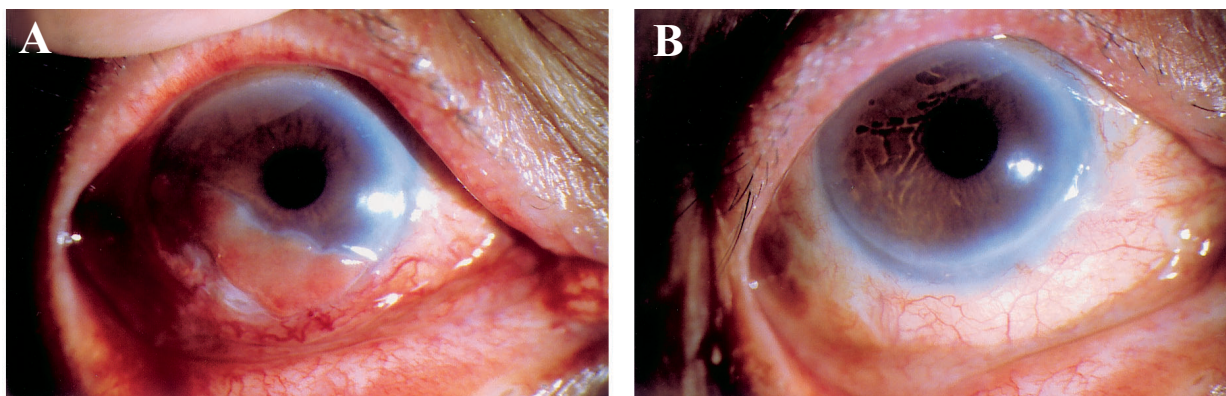
A 74-year-old man had redness and irritation in his right eye for 1 week. His medical history was unremarkable. Uncorrected visual acuity was 20/50 in his right eye and 20/70 in his left eye. Slit lamp examination showed an elevated nodular lesion over the temporal side of his right cornea, extending 2 mm from the limbus. After lesion excision followed

by AM grafting, no recurrence was observed during a follow-up period of 24.5 months.

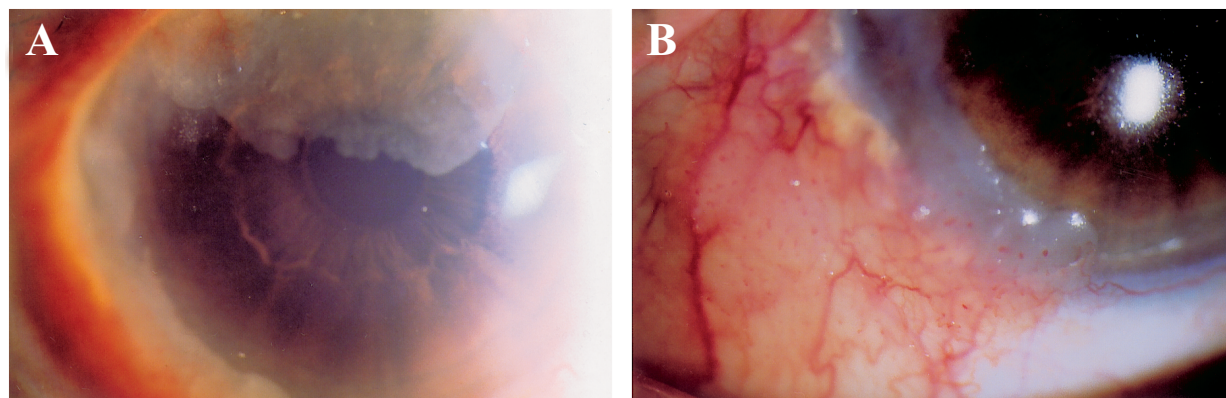
#### Case 5

A 31-year-old young woman had suffered from periodic red eye and foreign body sensation (OD) in her eye for 1 year. Slit lamp biomicroscopy showed a papilloma-like lesion with engorged vessels spanning the area from the 7- to the 9 o'clock position, with a 2-mm extension into the corneal side. After excision of this tumor, the area was soaked with mitomycin-C (0.02%) for 1 min followed by AM grafting to cover the bare scleral area. No recurrence occurred after 6 months of follow-up, but occasional redness of the eye occurred within the first 2 weeks following surgery.

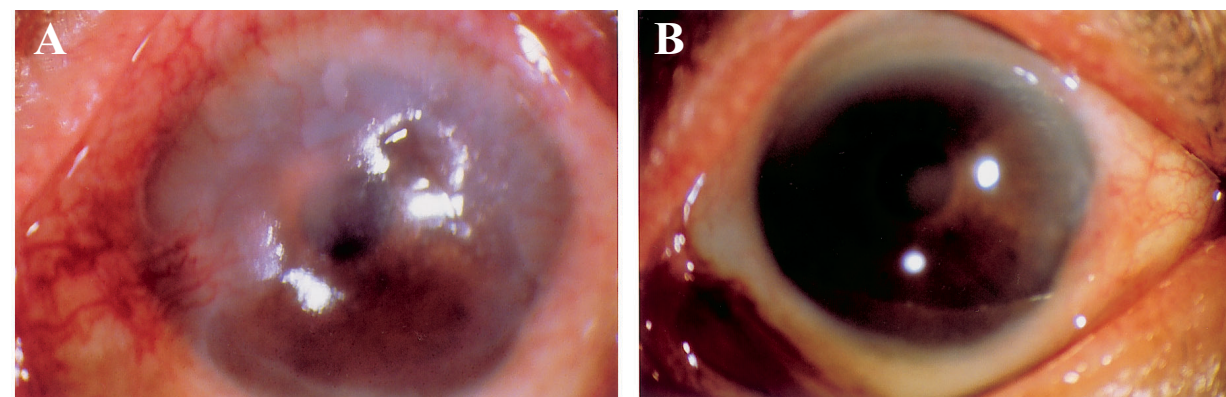




**Fig. 2** (A) Pretreatment view of the left eye showing a papilloma-like lesion with neovascular ingrowth. (B) Mild hyperemia and congestion within 2 weeks after the operation.



**Fig. 3** (A) Case 2 presenting a leukoplakic-like lesion with extension from the 7- to the 2-o'clock position. (B) The corneal and conjunctival lesion measuring about 10×6 mm with a 2-mm extension onto the corneal side.



**Fig. 4** (A) Case 3 showing a leukoplakic pannus-like lesion with engorged vessels involving the area from the 8- to the 4-o'clock position with extension onto the corneal side with a 4-mm width. (B) Complete corneal and conjunctival reepithelialization over the amniotic membrane which was completed in 2 weeks. The cosmetic appearance was quite good.

## DISCUSSION

CIN, a precancerous lesion of squamous cell carcinoma on the ocular surface, is slowly progressive with a low malignant potential.<sup>(2,9)</sup> CIN usually involves the limbal area. It is characterized by nodular, gelatinous, papilliform, flat and superficial or elevated leukoplakic lesions in a diffuse invasive fashion combined with tufts of engorged blood vessels.<sup>(10,11)</sup> Traditionally, the treatment modality for CIN involved surgical excision with or without adjunctive treatment such as cryotherapy, radiation, topical mitomycin, 5-FU, interferon (by a topical or intralesional injection), and phototherapeutic keratectomy by excimer laser, which have been used in an effort to reduce the recurrence rate.<sup>(1,2,4-6,12,13)</sup> In spite of this, the recurrence rate of CIN and conjunctival squamous cell carcinoma ranges from 15% to 52%.<sup>(14)</sup> In addition, complications such as corneal edema, fibrosis, iris atrophy, and intraocular inflammation have been reported to be associated with cryotherapy.<sup>(2)</sup> Side effects of radiation therapy include scleral necrosis, cataracts, dry painful eye, and even visual loss as a result of radiation vasculopathy.<sup>(15)</sup> Mitomycin-C has been introduced to treat CIN. However, serious complications such as scleral melting, infection, cataract formation, and limbal deficiency are possible with this treatment.<sup>(16)</sup> Acute transient toxic keratoconjunctivitis was observed in 5-FU-treated cases.<sup>(17)</sup> Side effects of interferon treatment are mild to moderate conjunctival hyperemia and follicular conjunctivitis, myalgia, and occasionally overnight fevers.<sup>(12)</sup> As the side effects of these adjunctive procedures cannot be ignored, larger study populations and longer follow-up periods were suggested to assess the risk of recurrence and adverse effects with these therapies. In addition to the side effects of adjunctive therapies, complications due to the surgical removal of the tumors themselves are common. These include corneal scarring, symblepharon, ocular hypotony, and iris atrophy.<sup>(18)</sup> Symblepharon is the most common surgical complication, which requires a large conjunctival flap or buccal mucosal graft to reconstruct the ocular surface.<sup>(11)</sup> Moreover, extensive excision of the tumor followed by the above-mentioned adjunctive treatment may also lead to limbal deficiency because of impaired limbal stem cell function. The latter is characterized by conjunctival epithelium ingrowth,

vascularization, and chronic inflammation.

Cryopreserved human AM contains a thick natural basement membrane and an avascular stroma, which may provide an optimal microenvironment to allow epithelial cell proliferation and differentiation. AM has recently been proposed as a new substrate for ocular surface reconstruction surgeries such as in pterygium, symblepharon, conjunctivochalasis, scarring, neoplasia, advanced chemical burns, Stevens-Johnson syndrome, ocular cicatricial pemphigoid, persistent epithelial defects, and corneal ulcers.<sup>(19-24)</sup> AM grafting promotes epithelialization and restores ocular surface integrity without inflammation or scarring. The AM stromal matrix suppresses signal activity of transforming growth factor  $\beta$  in human corneal and conjunctival fibroblasts<sup>(25,26)</sup> and can also induce apoptosis of leucocytes as shown in an animal study.<sup>(27)</sup> The AM contains protease inhibitors indicating that it can reduce inflammation-associated proteolytic activity after application.<sup>(22)</sup>

In order to prevent subsequent conjunctival ingrowth and corneal vascularization following extensive tumor excision, both autograft and allograft limbal transplantations have been proposed.<sup>(28,29)</sup> An AM graft alone has been demonstrated for reconstruction of the ocular surface in eyes with partial limbal stem cell deficiency.<sup>(23,30)</sup> Moreover, the advantages of AM grafts over traditional buccal mucosal autografts are the excellent cosmetic outcome and a normal conjunctival epithelial phenotype as demonstrated by impression cytology.<sup>(31)</sup>

In this study, all cases had good results with no special complications. Only limited short-term complications such as redness and hyperemia occurred. Complete epithelialization occurred within 2 weeks. After a mean following-up period of 27 months, no recurrence was noted, and the cosmetic outcome was good. This study demonstrates the usefulness of AM grafts for the treatment of corneal and conjunctival CIN. The application of AM grafts is considered safe as long as the AM is prepared according to the standard protocol. The transparency of the AM allows for a good cosmetic appearance and ease of monitoring tumor recurrence.<sup>(32)</sup>

Nevertheless the immunogenic characteristics of AM remain unclear. Gabler and Messmer showed the presence of hypopyon after AM transplantation.<sup>(33,34)</sup> In the present study, no one was found to have hypopyon after AM grafts. Also, severe com-

plications such as bacterial contamination of the AM were not observed in this study.

In conclusion, an AM graft is an effective adjunctive therapy for reducing the recurrence of CIN following primary excision of tumors. Larger population studies with longer follow-up periods are recommended to further assessing the risk of recurrence and other possible side effects.

### Acknowledgements

The authors thank Professor Ray Jui-Fang Tsai for his effort to introduce and promote the clinical application of amniotic membranes, and for serving as the inspiration for the present study.

### REFERENCES

1. Erie JC, Campbell RJ, Liesegang TJ. Conjunctival and corneal intraepithelial and invasive neoplasia. *Ophthalmology* 1986;93:176-83.
2. Pizzarello LD, Jakobiec FA. Bowen's disease of the conjunctiva: a misnomer. In: Jakobiec FA, ed. *Ocular and adnexal tumors*. Birmingham: Aesculapius, 1978:553-71.
3. Buus DR, Tse DT, Folberg R. Microscopically controlled excision of conjunctival squamous cell carcinoma. *Am J Ophthalmol* 1994;117:97-102.
4. Wilson MW, Hungerford JL, George S, et al. Topical mitomycin C for the treatment of CIN. *Am J Ophthalmol* 1997;124:303-11.
5. Yeatts RP, Ford JG, Stanton GA, Reed JW. Topical application of 5-fluorouracil in treating epithelial neoplasia of the conjunctiva and cornea. *Ophthalmology* 1995;102:1338-44.
6. Hu FR, Wu MJ, Kuo SH. Interferon treatment for corneolimbal squamous dysplasia. *Am J Ophthalmol* 1998;125:118-9.
7. Tseng SCG, Prabhasawat P, Lee SH. Amniotic membrane transplantation for conjunctival surface reconstruction. *Am J Ophthalmol* 1997;124:765-74.
8. Prabhasawat P, Barton K, Burkett G, Tseng SCG. Comparison of conjunctival autografts, amniotic membrane grafts, and primary closure for pterygium excision. *Ophthalmology* 1997;104:974-85.
9. Grossniklaus HE, Green WR, Luckenbach M, et al. Conjunctival lesion in adults: a clinical and histopathologic review. *Cornea* 1987;6:78-116.
10. Sanders N, Bedotto C. Recurrent carcinoma in situ of the conjunctiva and cornea. *Am J Ophthalmol* 1972;74:688-93.
11. Murat T, Devron HC, Brooks C, Theodore M. Intraepithelial and invasive squamous cell carcinoma of the conjunctiva: analysis of 60 cases. *Br J Ophthalmol* 1999;83:98-103.
12. Schechter BA, Schrier A, Nagler RS, Smith EF, Velasquez GE. Regression of presumed primary conjunctival and corneal intraepithelial neoplasia with topical interferon Alpha-2b. *Cornea* 2002;21:6-11.
13. Dausch D, Landes M, Schroeder E. PTK in recurrent corneal intraepithelial dysplasia. *Arch Ophthalmol* 1994;112:22-3.
14. Lee GA, Hirst LW. Ocular surface squamous neoplasia. *Surv Ophthalmol* 1995;39:429-50.
15. Kersley JH, Fitchew RS, Taylor RG. Adjunctive radiotherapy with strontium-90 in the treatment of conjunctival squamous cell carcinoma. *Int J Radiat Oncol Biol Phys* 1988;14:435-43.
16. Rubinfeld RS, Pfister RR, Stein RM, Foster CS, Martin NF, Stoleru S, Talley AR, Speaker MG. Serious complications of topical mitomycin C after pterygium surgery. *Ophthalmology* 1992;99:1647-54.
17. Midea E, Angeli CD, Valenti M, De Belvis V, Boccato P. Treatment of conjunctival squamous cell carcinoma with topical 5-fluorouracil. *Br J Ophthalmol* 2000;84:268-72.
18. Fraunfelder FT, Wingfield D. Management of intraepithelial conjunctival tumors and squamous cell carcinomas. *Am J Ophthalmol* 1983;95:359-63.
19. Prabhasawat P, Barton K, Burkett G, Tseng SCG. Comparison of conjunctival autograft, amniotic membrane graft, and primary closure for pterygium excision. *Ophthalmology* 1997;104:974-85.
20. Ma DHK, See LC, Liao SB, Tsai RJF. Amniotic membrane graft for primary pterygium: comparison with conjunctival autograft and topical mitomycin C treatment. *Br J Ophthalmol* 2000;84:973-8.
21. Meller D, Maskin SL, Pires RTF, Tseng SCG. Amniotic membrane transplantation for symptomatic conjunctivochalasis refractory to medical treatment. *Cornea* 2000;19:796-803.
22. Espana EM, Prabhasawat P, Grueterich M, Solomon A, Tseng SCG. Amniotic membrane transplantation for reconstruction after excision of large ocular surface neoplasias. *Br J Ophthalmol* 2002;86:640-5.
23. Tsubota K, Satake Y, Ohyama M, Toda I, Takano Y, Ono M, Shinozaki N, Shimazaki J. Surgical Reconstruction of The Ocular Surface in Advanced Ocular Cicatricial Pemphigoid and Stevens-Johnson Syndrome. *Am J Ophthalmol* 1996;122:38-52.
24. Shwu-Huey Lee, Scheffer C.G. Tseng. Amniotic membrane transplantation for persistent epithelial defects with ulceration. *Am J Ophthalmol* 1997;123:303-12.
25. Tseng SCG, Li D-Q, Ma X. Suppression of transforming growth factor isoforms, TGF- $\beta$  receptor II, and myofibroblast differentiation in cultured human corneal and limbal fibroblasts by amniotic membrane matrix. *J Cell Physiol* 1999;179:325-35.
26. Lee S-B, Li D-Q, Tan DTH, Meller DC, Tseng SCG. Suppression of TGF- $\beta$  signaling in both normal conjunctival fibroblasts and pterygial body fibroblasts by amniotic membrane. *Curr Eye Res* 2000;20:325-34.



27. Park WC, Tseng SCG. Modulation of acute inflammation and keratocyte death by suturing, blood and amniotic membrane in PRK. *Invest Ophthalmol Vis Sci* 2000;41:2906-14.
28. Tan DT, Ficker LA, Buckley RJ. Limbal Transplantation. *Ophthalmology* 1996;103:29-36.
29. Douglas J. Coster, Rajesh K, Aggarwal, Keryn A. Williams. Surgical Management of Ocular Surface Disorders Using Conjunctival and Stem Cell Allografts. *Br J Ophthalmol* 1995;79:977-82.
30. Anderson DF, Ellies P, Pires RT, Tseng SCG. Amniotic membrane transplantation for partial limbal stem cell deficiency. *Br J Ophthalmol* 2001;85:567-75.
31. Prabhasawal P, Tseng SCG. Impression cytology study of epithelial phenotype of ocular surface reconstructed by preserved human amniotic membrane. *Arch Ophthalmol* 1997;115:1360-7.
32. Paridaens D, Beekhuis H, Bosch WVD, Remeyer L, Melles G. Amniotic membrane transplantation in the management of conjunctival malignant melanoma and primary acquired melanosis with atypia. *Br J Ophthalmol* 2001;85:658-661.
33. Gabler B, Lohmann CP. Hypopyon after repeated transplantation of human amniotic membrane onto the corneal surface. *Ophthalmol* 2000;107:1344-6.
34. Messmer EM. Hypopyon after amniotic membrane transplantation. *Ophthalmol* 2001;108:1714-5.

## 切除角結膜表皮細胞內腫瘤後以羊膜移植之效果

葉龍坤 林信瓊 馬惠康

**背景：**評估角結膜表皮細胞內腫瘤切除後以羊膜移植重建眼表層之效果。

**方法：**收集5個角結膜表皮細胞內腫瘤病例，在1996年4月至2000年9月由醫師施行相同手術切除後，再施以羊膜移植手術。羊膜以無菌標準程序處理後，覆蓋於術後裸露之鞏膜上，以10-0尼龍線縫合，之後追蹤評估其效果。

**結果：**平均追蹤期27月(6月至69個月)，所有病人眼表層表皮生長及癒合快速，無特別副作用且無一復發病例。

**結論：**羊膜移植手術對角結膜表皮細胞內腫瘤是一有效且安全之輔助治療。對於眼表層表皮生長及重建，有良好的效果。  
(長庚醫誌 2003;26:737-44)

**關鍵字：**角結膜表皮細胞內腫瘤，羊膜移植術，復發。

---

長庚紀念醫院 台北院區 眼科部

受文日期：民國92年2月19日；接受刊載：民國92年5月6日。

索取抽印本處：馬惠康醫師，長庚紀念醫院 眼科部。桃園縣333龜山鄉復興街5號。Tel.: (03)3281200轉8666; Fax: (03)3287798; E-mail: davidhkma@yahoo.com