

## Guided Bone Regeneration for Fenestration Defects in Dental Implants

Hwey-Chin Yeh, DDS, MS; Kuang-Wei Hsu<sup>1</sup>, DDS

Guided bone regeneration has been applied in implant dentistry for increasing the width and height of the alveolar ridge in areas with insufficient bone. Various materials and techniques have been used for this purpose. It refers to a surgical procedure by which utilizing a mechanical barrier to create a secluded space around the defect to permit bone regeneration without the competition of other tissues. This report presents a case with buccal fenestrations on maxillary implant sites observed during a surgical procedure. An allograft and a non-resorbable membrane were concomitantly used to increase the width of the alveolar ridge. Hard tissue regeneration was evident clinically. The implants were restored for functioning and followed for 2 years. Factors affecting outcomes are also discussed. Membrane stability and the space-making effect remain the keys to success. (*Chang Gung Med J* 2003;26:684-9)

**Key words:** guided bone regeneration, membrane, non-resorbable, allograft, demineralized freeze-dried bone.

Guided bone regeneration (GBR) has made the placement of implants possible in sites that were not a part of the original implant protocol. It has been successfully applied for increasing the width and height of the alveolar ridge before implant installation and in the treatment of peri-implant bone defects in experimental animals<sup>(1,2)</sup> and in clinical cases.<sup>(3,4)</sup> Recently, it has been further applied in preserving extraction sockets, in the adjunct to immediate implant placement<sup>(5,6)</sup> or in the treatment of fenestration or dehiscence of implants at sites compromised by insufficient bone.<sup>(2-4,7)</sup>

The GBR technique refers to a surgical procedure by which utilizing porous membranes as a mechanical barrier to create a secluded space around the defects to permit bone regeneration without the competition of other tissue.<sup>(8)</sup> Nonresorbable expanded polytetrafluoroethylene (e-PTFE) membranes, collagen membranes, or other bioabsorbable

polymer barriers have been used for this purpose. These barriers can be used alone or supported by either autogenous bone grafts or various bone substitutes. The efficacy of these various procedures has been evaluated clinically and histologically.<sup>(9-15)</sup>

### CASE REPORT

A 45-year-old woman sought dental treatments with a chief complaint of missing some teeth and looking for a new restoration on her left maxilla. An old cantilevered fixed partial denture was dislodged when the patient presented. Clinical and radiographic examinations revealed that the left maxillary first and second premolars were 2 residual roots. An apical radiolucency was noted on the second premolar. The first and second molars were missing. Extraction of the 2 residual roots was recommended. The edentulous ridge presented a nice ovoid appear-

---

From the Division of Periodontics, <sup>1</sup>Division of Prosthodontics, Department of Dentistry, Chang Gung Memorial Hospital, Taipei.

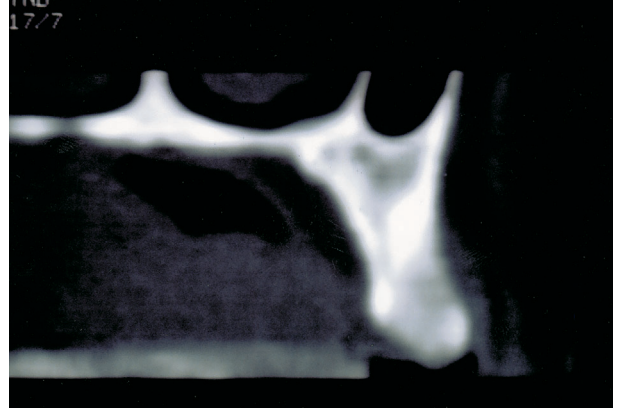
Received: Dec. 5, 2002; Accepted: Mar. 12, 2003

Address for reprints: Dr. Hwey-Chin Yeh, Division of Periodontics, Department of Dentistry, Chang Gung Memorial Hospital, 5, Fushing Street, Gueishan Shiang, Taoyuan, Taiwan 333, R.O.C. Tel.: 886-3-3281200 ext. 8326; Fax: 886-3-3281200 ext. 8320; E-mail: ma3187@cgmh.org.tw

ance regarding the width and height after 8 months of healing of the extraction sockets. The gingiva was pale pink. The masticatory mucosa was sufficient.

Since the patient rejected a removable prosthesis for psychological reasons, a computerized tomography was taken after tooth extraction to evaluate the osseous morphology for implant installation. It revealed sufficient bone height but limited bone width. An area of thick soft tissue, which gave the edentulous ridge a nice wide appearance, was noted on the buccal side (Fig. 1). Considering the alignment and the angulations of the implant fixtures needed for restoring prosthesis of acceptable occlusion, a GBR procedure is most likely indicated in cases of buccal dehiscence or fenestration created during a surgical procedure. However, the patient withdrew from the surgical procedure and cancelled further appointments when she was informed of the details of the GBR.

Six months later she showed up in our clinic and asked for implant therapy again. A full-thickness paracrestal incision was made toward the palatal side of the edentulous ridge. Two buccal vertical releasing incisions were also made. Three smooth-surface pure-titanium implants (Branemark, Nobel Biocare AB, Goteborg, Sweden) were carefully placed according to the standard procedure described by Adell et al.<sup>(16)</sup> Standard 3.75-mm-diameter implants with a length of 13 mm were used. Primary stabilization was achieved by anchoring the implants in the alveolar bone apically. Buccal fenestrations were noted on the second and third implants 5 mm above the crest of bone. Four and seven threads were exposed respectively (Fig. 2A). To provide sufficient blood supply, decorticalization between implants was on the buccal cortical plate using a rotary instrument. To create a space between the barrier and the bone surface, 3 stainless steel tenting screws (OsseoFix, 3I, Palm Beach Gardens, FL, USA) were placed between implants. Demineralized freeze-dried bone allograft (250-500  $\mu$ m, Dembone, Pacific Coast Tissue Bank, Los Angeles, CA, USA) was humidified and grafted onto the fenestration areas. An e-PTFE membrane (GTAM, WL Gore, Flagstaff, AZ, USA) was stabilized onto the grafted site with 4 stainless steel fixation screws (OsseoFix) (Fig. 2B). The buccal flap was partially split. The flaps were closed with a horizontal mattress and interrupted sutures of nonresorbable material (WL

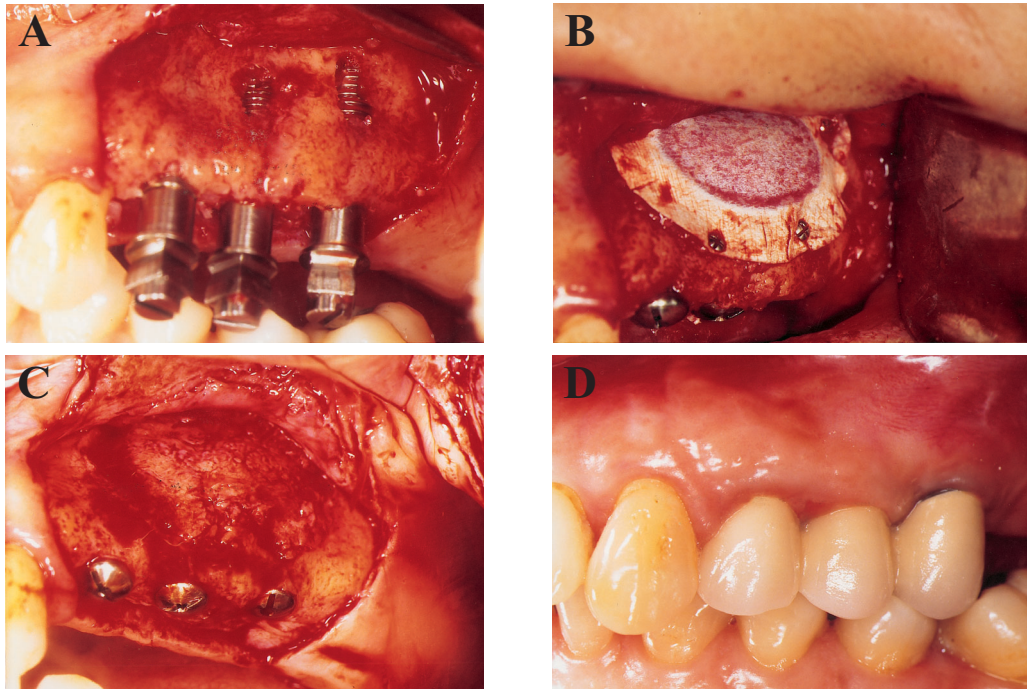


**Fig. 1** The computerized tomography revealed sufficient bone height but limited bone width.

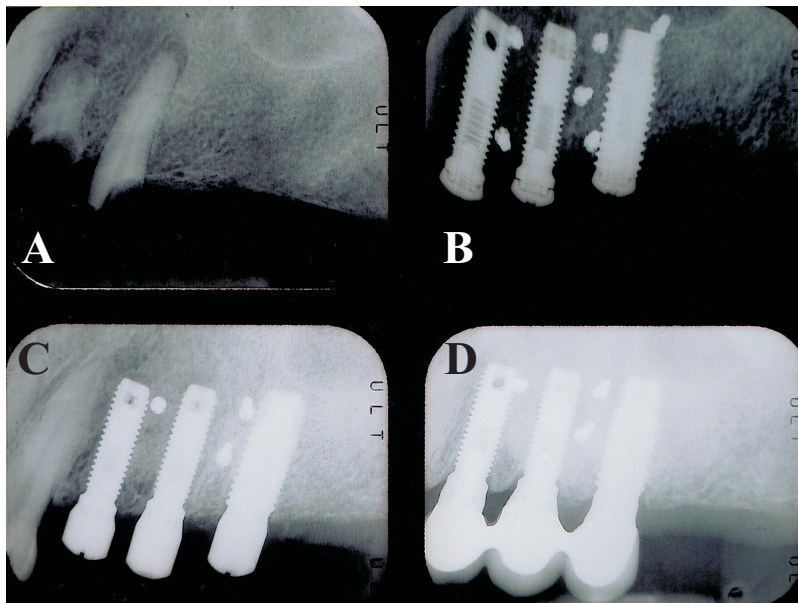
Gore). Postoperatively, 500 mg amoxicillin q.6.h. and 400 mg ibuprofen t.i.d. were given for 14 days. Chlorhexidine (Scodyl, 0.12%, Taipei, Taiwan) mouth rinse was also prescribed. The sutures were removed after 14 days. The patient had no immediate denture through the healing period. She was recalled once a week for the first month and then once a month until the second-stage surgery.

After 10 months of healing, second-stage surgery was performed. The surgical area was reopened with a paracrestal full-thickness incision and 2 vertical releasing incisions. Although the coronal edge of the membrane was slightly elevated during the reflecting procedure, most parts of the membrane had remained intact and firmly attached to the bony surface. The fixation screws were then loosened and removed, and the e-PTFE membrane was also removed. Previously existing fenestrations were covered by newly formed reddish hard tissue (Fig. 2C). The tenting screws were not visible and were thus left in place. The cover screws were replaced by healing abutments. The flap was apically positioned on the buccal side and sutured with silk by interrupted sutures. The wound healed uneventfully.

A 3-unit implant-supported fixed partial prosthesis was inserted 2 months after the second-stage surgery. Slight marginal tissue erythema resulting from insufficient oral hygiene was noted during the recall visits (Fig. 2D). The implant-supported prosthesis was followed-up for 2 years, and it was seen to be in excellent condition and to have good function. Neither symptoms nor signs of clinical infection



**Fig. 2** (A) Three smooth-surface pure-titanium implants were placed. Buccal fenestrations were noted on the second and third implants. (B) The fenestration sites were grafted with demineralized freeze-dried bone allograft, covered by an e-PTFE membrane with 3 tenting screws underlying and stabilized with 4 stainless steel fixation screws. (C) The fixation screws and the membrane were removed after 10 months. Previously existing fenestrations were covered by newly formed reddish hard tissue. The tenting screws were not visible. (D) The 3-unit implant-supported fixed partial prosthesis inserted 12 months after the GBR procedure.



**Fig. 3** Periapical radiographs. (A) initial; (B) implant installation with the GBR technique; (C) membrane removal; (D) after 2 years in function.

were found. A radiographic exam suggested that the bone level was being maintained (Fig. 3). The patient has been very satisfied with the result.

## DISCUSSION

One should never be too cautious about carrying out a very successful surgical procedure with a future treatment plan. When the expected conditions encounter clinical limitations, the clinician usually makes compromises with the treatment plan. In this case, for example, changing the alignment of the fixtures, using angulated abutments, or resulting a compromised occlusal scheme had to be considered. On the other hand, preparing a substitute procedure, such as a GBR technique, to solve the problems challenges the clinician's knowledge and skill and is also limited by the development of biomaterials.

The clinical outcome of this case clearly demonstrated a positive effect of the barrier membrane on bone regeneration around the implant. Several factors could have influenced the quantity of bone formation in a GBR technique. The space-maintaining capability and its duration of the barrier membrane are the most important ones. Dahlin et al.<sup>(13)</sup> demonstrated that the amount of bone regeneration is determined and limited by the available space. Although some absorbable membranes, such as poly lactic acid and poly glycolic acid (PLA/PGA)<sup>(12,15)</sup> or collagen,<sup>(13)</sup> have been applied in the GBR technique, their stiffness and duration have been questioned. Sandberg et al.<sup>(17)</sup> noted that some resorbable membranes used in their study showed a lack of stiffness, resulting in the collapse of the membrane into the defect area, causing the newly formed bone to take on an hourglass shape. Absorbable membranes generally start to resorb after 4 to 6 weeks. With membrane resorption, the barrier effect could decrease too soon to achieve complete bone regeneration. In a comparative histologic human study, Simion et al.<sup>(12)</sup> found that e-PTFE membranes were the most effective barrier material, in that denser and a greater amount of regenerated bone were found. PLA/PGA membranes produced some bone regeneration when compared to control sites, but to a lesser extent compared to e-PTFE sites. It seems that the tenting screws and the stiffness of the e-PTFE membrane as used in this case guarantee the maintenance of an adequate space between the membrane and the dehiscence defect.

Some previous studies have suggested the use of bone graft to avoid barrier deformation. Autogenous bone graft provides the most predictable osteogenic result. However, a second surgical site is needed to harvest the graft material, which discourages patients from the GBR procedure. Bone replacement grafts, such as DFDBA alone,<sup>(9,14)</sup> a composite graft of DFDBA/FDBA,<sup>(15)</sup> or hydroxyapatite (HA),<sup>(13)</sup> have been used with variable results reported. In the evidence of a histologic human study by Simion et al.,<sup>(14)</sup> viable bone was observed in the absence of inflammatory cell infiltrate in regenerated bone by using an e-PTFE membrane with DFDBA. Because of the limited availability of bone substitute, only DFDBA was used in this case. Although no histologic analysis was done, the clinical appearance seemed to be satisfactory and comparable to that of a previous study.

Thicknesses of the soft tissue and primary closure of the flaps are also important aspects of the surgical procedure to maintain wound stability during healing. Early exposure of the membrane, with consequential bacterial contamination of the healing tissues, hinders bone regeneration, despite careful maintenance with chlorhexidine application.<sup>(18)</sup> Nowzari and Slots showed that implant sites with submerged barrier membranes throughout their 9-month study were free of cultivable microorganisms and experienced significantly more osseous healing than sites with prematurely exposed membranes.<sup>(19)</sup> In the present report, the patient had relatively thick soft tissue and maintained intimate closure of the wound throughout the healing period, thus providing a nice environment for bone regeneration without bacterial invasion.

The result of this case suggests that a non-resorbable e-PTFE membrane with DFDBA can be used for treating fenestration defects around implants. The compilation of case series information is ongoing in order to determine whether predictable results maintain long-term stability and clinical benefit.

## REFERENCES

1. Dahlin C, Sennerby L, Lekholm U, Linde A, Nyman S. Generation of new bone around titanium implants using a membrane technique: an experimental study in rabbits. *Int*

- J Oral Maxillofac Implants 1989;4:19-25.
2. Becker W, Becker BE, Handelsman M, Celletti R, Oschenbein C, Hardwick R, Langer B. Bone formation at dehiscence dental implant sites treated with implant augmentation material: A pilot study in dogs. *Int J Periodont Rest Dent* 1990;10:92-101.
  3. Dahlin C, Andersson L, Linde A. Bone augmentation at fenestrated implants by an osteopromotive membrane technique. A controlled clinical study. *Clin Oral Implants Res* 1991;2:159-65.
  4. Dahlin C, Lekholm U, Becker W, Becker B, Higuchi K, Callens A, van Steenberghe D. Treatment of fenestration and dehiscence bone defects around oral implants using the guided tissue regeneration technique: A prospective multicenter study. *Int J Oral Maxillofac Implants* 1995; 10:312-8.
  5. Becker W, Dahlin C, Becker BE, Lekholm U, van Steenberghe D, Higuchi K, Kultje C. The use of e-PTFE barrier membranes for bone promotion around titanium implants placed into extraction sockets: A prospective multicenter study. *Int J Oral Maxillofac Implants* 1994; 9:31-40.
  6. Simion M, Baldoni M, Zaffe D. Jawbone enlargement using immediate implant placement associated with a split-crest technique and guided tissue regeneration. *Int J Periodont Res Dent* 1992;12:463-71.
  7. Jovanovic SA, Spiekermann H, Richter EJ. Bone regeneration around titanium dental implants in dehiscence defect sites: A clinical study. *Int J Oral Maxillofac Implants* 1992;7:233-45.
  8. Dahlin C, Linde A, Gottlow J, Nyman S. Healing of bone defects by guided tissue regeneration. *Plast Reconstr Surg* 1988;5:672-6.
  9. Nevins M, Mellonig J. Enhancement of the damaged edentulous ridge to receive dental implants: A combination of allograft and the Gore-Tex membrane. *Int J Periodontics Restorative Dent* 1992;12:97-111.
  10. Callan DP, Rohrer MD. Use of bovine-derived hydroxyapatite in the treatment of edentulous ridge defects: A human clinical and histologic case report. *J Periodontol* 1993;64:575-82.
  11. Jovanovic SA, Nevins M. Bone formation utilizing titanium-reinforced barrier membranes. *Int J Periodontics Restorative Dent* 1995;15:57-69.
  12. Simion M, Scarano A, Gionso L, Piattelli A. Guided bone regeneration using resorbable and nonresorbable membranes: A comparative histological study in humans. *Int J Oral Maxillofac Implants* 1996;11:735-42.
  13. Brunel G, Brocard D, Duffort JF, Jacquet E, Justumus P, Simonet T, Benque E. Bioabsorbable materials for guided bone regeneration prior to implant placement and 7-year follow-up: Report of 14 cases. *J Periodontol* 2001;72:257-64.
  14. Simion M, Trisi P, Piattelli A. GBR with an e-PTFE membrane associated with DFDBA: Histologic and histochemical analysis in a human implant retrieved after 4 years of loading. *Int J Periodontics Restorative Dent* 1996;16:338-47.
  15. Rosen P, Reynolds MA. Guided bone regeneration for dehiscence and fenestration defects on implants using an absorbable polymer barrier. *J Periodontol* 2001;72:250-6.
  16. Adell R, Lekholm U, Branemark P-I. Surgical procedures. In: Branemark P-I, Zarb GA, Albrektsson T (eds). *Tissue-Integrated Prostheses: Osseointegration in Clinical Dentistry*. Chicago: Quintessence, 1985:199.
  17. Sandberg E, Dahlin C, Linde A. Bone regeneration by the osteopromotion technique using bioabsorbable membranes: An experimental study in rats. *J Oral Maxillofac Surg* 1993;51:1106-14.
  18. Simion M, Baldoni M, Rossi P, Zaffe D. Comparative study of the effectiveness of GTAM membranes with and without early exposure during the healing period. *Int J Periodont Rest Dent* 1993;14:167-80.
  19. Nowzari H, Slots J. Microorganism in polytetrafluoroethylene membranes for guided tissue regeneration. *J Clin Periodontol* 1994;21:203-10.

## 牙科植體周圍骨開窗之引導骨增生術

葉惠津 徐光蔚<sup>1</sup>

近來，引導骨增生術已被廣泛應用於牙科植體手術中，以增加齒槽骨嵴高度或寬度之不足。目前已知之技術包括應用各種不同的屏障膜，如可吸收或不可吸收的增生膜等，或加以骨性替代物支撐其下之空間，以達到阻斷軟組織及引導骨性細胞生長的目的。本篇報告一例因上顎顎骨寬度不足，於種植牙科植體時發生頰側骨開窗，而以不可吸收增生膜及冷凍乾燥骨進行骨引導增生術，並於贖復後追蹤兩年之結果。文末並對影響其成功之因素加以探討，增生膜的穩定性與其所能提供之空間應是決定引導骨增生術成功的重要因素。(長庚醫誌 2003;26:684-9)

**關鍵字：**引導骨增生術，增生膜，不可吸收，同種異質移植體，脫鈣冷凍乾燥骨粉。

---

長庚紀念醫院 台北院區 牙科系 牙周病科 <sup>1</sup>贖復牙科

受文日期：民國91年12月5日；接受刊載：民國92年3月12日。

索取抽印本處：葉惠津醫師，長庚紀念醫院 牙科系 牙周病科。桃園縣333龜山鄉復興街5號。Tel.: (03)3281200轉8326; Fax: (03)3281200轉8320; E-mail: ma3187@cgmh.org.tw