

## Malignant Hypertensive Retinopathy-Clinical and Fundus Manifestations in Patients with New Onset or Acute Exacerbation of Chronic Hypertension

Yi-Hao Chen, MD; Hsi-Kung Kuo, MD; Min-Lun Kao, MD

**Background:** We attempted to review the clinical and fundus findings in patients with malignant hypertension (MHT).

**Methods:** Charts and fundus photographs of patients with malignant hypertensive retinopathy from 1995 to 2000 were retrospectively reviewed. Data of patients were included when their color fundus photographs revealed findings suggestive of malignant hypertension (MHT). There had to have been at least 1 high blood pressure reading recorded in the chart during the period when the symptoms occurred. Data were excluded from patients with diseases such as diabetes mellitus, blood dyscrasia, and autoimmune and infectious diseases which can mimic the fundus findings of MHT.

**Results:** Fourteen patients were included in our study. Patients were divided into 2 groups according to whether or not they had a history of hypertension. Group 1 included 6 patients with no hypertension history, while group 2 included 8 patients with a known hypertension history. In group 1, MHT was diagnosed by an ophthalmologist in 4 patients, and the other 2 patients were referred from the Gynecology and Nephrology Departments. Between the 2 groups, there were no significant differences in age, or systolic and diastolic blood pressures. There were more complications such as renal failure and stroke in group 2 patients.

**Conclusion:** Funduscopy has decisive significance in the diagnosis and monitoring of MHT. In order to accurately diagnose and achieve early control of this critical condition, a detailed fundus examination and blood pressure monitoring are mandatory.

*(Chang Gung Med J 2003;26:669-77)*

**Key words:** malignant hypertension, malignant hypertensive retinopathy.

Hypertension is ranked as the fourth greatest mortality risk factor in the world. Acute hypertension of any cause can enter an accelerated or malignant stage. Three different levels of ocular fundic lesions are altered by arterial hypertension including

hypertensive retinopathy, choroidopathy, and optic neuropathy.<sup>(1)</sup> Keith et al. used the term malignant hypertension (MHT) for the first time in the English literature in 1928 when they reported on a series of patients with the presence of retinitis, marked hyper-

---

From the Department of Ophthalmology, Chang Gung Memorial Hospital, Kaoshiung.

Received: Feb. 18, 2003; Accepted: Apr. 24, 2003

Address for reprints: Dr. Hsi-Kung Kuo, Department of Ophthalmology, Chang Gung Memorial Hospital, 123, Dabi Road, Niasung Shiang, Kaohsiung, Taiwan 833, R.O.C. Tel.: 886-7-7317123 ext. 2801; Fax: 886-7-7317123 ext. 2830; E-mail: d2767@cgmh.org.tw

tension, and fairly adequate renal function.<sup>(2)</sup> By 1939, Keith et al. had classified patients with hypertensive retinopathy into 4 groups. They described the course and prognosis of these patients with hypertension according to the degree of retinopathy. Group I was restricted to minimal constriction of the retinal arterioles with some tortuosity in mildly hypertensive patients. Group II included arteriovenous nicking, while group III included hemorrhaging and exudates. Group IV included papilledema.<sup>(1,3)</sup> MHT is a clinical syndrome characterized by severe systolic and diastolic hypertension, usually appearing progressively over a period of several weeks to several months; it is often associated with significant and progressive deterioration in cardiac or renal function, and there is evidence of encephalopathy.<sup>(4)</sup>

The World Health Organization (WHO) criteria are probably the most useful for MHT; it now differentiates hypertensive retinopathy on the basis of 2 grades of changes in the fundus, fundus hypertonicus and fundus hypertonicus malignus.<sup>(5)</sup> Patients diagnosed as having malignant hypertension have severe hypertension with bilateral retinal hemorrhages and exudates. Papilledema, unless florid, is an unreliable physical sign and was of no additional prognostic importance in patients treated for hypertension who already had bilateral hemorrhaging and exudates.<sup>(6)</sup> Diastolic blood pressure is usually greater than 130 mmHg, but there is no absolute level above which MHT always develops and below which it never occurs.<sup>(7)</sup>

The object of this study was to review the clinical and fundic manifestations in MHT patients with new onset or acute exacerbation of chronic hypertension. Funduscopy may offer the chance to detect previously existing and newly occurring vascular damage at a low cost and with little effort. The investigation also sought to determine if funduscopy has decisive significance in the diagnosis of MHT. So we searched for patients with MHT, before the target organ damage had occurred or during early progression, when patients complained of such manifestations of the fundus as an acute or sub-acute decrease in vision. Thus, we hope to be able to suggest early interventions for blood pressure control.

## METHODS

We retrospectively reviewed the charts and fun-

dus photographs of patients with hypertensive retinopathy from 1995 to 2000. All patients had visited an ophthalmologic clinic with the chief complaint of blurred vision. Data of patients were included when their color photographs of the fundus were judged to indicate hypertensive retinopathy grade III or IV by an experienced ophthalmologist. There had to have been at least 1 high blood pressure reading recorded in the chart during the period when the symptoms occurred. Data were excluded from patients with such diseases as diabetes mellitus, blood dyscrasia, and autoimmune and infectious diseases which can mimic the fundus findings of MHT.

## RESULTS

Fourteen patients were included in our study (Table 1). There were 4 males and 10 females. The patients were divided into 2 groups according to whether or not they had a history of hypertension (Table 2). Group 1 (cases 1 to 6) included 6 patients with no history of hypertension, while group 2 (cases 7 to 14) included 8 patients with a known history of hypertension. The ages ranged from 12 to 47 (mean, 31.2) years in group 1 and 22 to 56 (mean, 43.1) years in group 2. Systolic blood pressures ranged from 163 to 228 (mean, 206) mmHg in group 1 and 160 to 249 (mean, 196) mmHg in group 2. Diastolic blood pressure ranged from 100 to 160 (mean, 143) mmHg in group 1 and 90 to 156 (mean, 115) mmHg in group 2. Patients in group 2 had a hypertension history with or without receiving medication for it. They had been warned that they had poorly controlled blood pressure, and it had been suggested that they visit their internists for further treatment. There were no significant differences in ages, or systolic and diastolic blood pressures between the 2 groups. Case 6 (group 1) developed renal failure 1 month after MHT was diagnosed, although he was admitted for intensive medical blood pressure control. Two patients in group 2 experienced cerebral vascular accidents during the period when MHT was diagnosed. Case 7 developed a central retinal artery occlusion (OS) contemporaneously with MHT being diagnosed.

### Case illustration

#### Case 2.

This 12-year-old boy was first diagnosed with

**Table 1.** Clinical Finding of Patients with Malignant Hypertension

Case No.	Gender	Age (years)	Symptoms	Initial VA (OD/OS)	Final VA (OD/OS)	BP (mmHg)	Fundus findings	Past history	Comments/etiology
1	M	40	Color vision ↓, metamorphosia	0.6/0.5	-	210/160	Splitting hemorrhage, CWS <sup>†</sup> , disc hyperemia, macular edema (OS)	(-)	EH <sup>†</sup>
2	M	12	VA ↓, BWL, fatigue	0.05/0.05	1.0/1.0	228/180	Disc edema, CWS <sup>†</sup> , macular star	(-)	pheochromocytoma
3	M	30	VA ↓	CF>100 cm	1.0/1.0	239/162	Macular star, CWS <sup>†</sup> , blot hemorrhage, disc edema	(-)	EH <sup>†</sup>
4	F	26	Blurred vision	0.1/0.03	1.0/0.5	200/120	Flame-shaped hemorrhage, CWS <sup>†</sup> , macular star, disc edema, choroidopathy in FAG	(-)	RH <sup>±</sup>
5	F	32	Headaches, VA ↓	0.05/0.05	0.2/0.2	163/100	Disc edema, dot and blot hemorrhage, exudative RD	(-)	PIH**
6	M	47	Blurred vision, vomiting, floaters	0.7/0.7	1.0/1.0	195/135	CWS <sup>†</sup> , blot and flame-shaped hemorrhage, papillomacular bundle involved	(-)	RH <sup>±</sup> , renal failure 1 month later
7	F	41	Blurred vision	0.4/HM	1.0/HM	249/156	Disc edema (ou), CRAO (os)	EH <sup>†</sup> for 8 years	EH <sup>†</sup>
8	F	22	Blurred vision	0.2/0.2	1.0/1.0	173/100	Disc edema, CWS <sup>†</sup> , flame-shaped hemorrhage	Hypertension	RH <sup>±</sup>
9	F	43	Seizures, VA ↓	0.01/0.2	0.1/0.6	200/100	Dot and blot hemorrhage, CWS <sup>†</sup> , macular star	Hypertension	PIH** stroke (occipital infarction)
10	F	38	Blurred vision	0.7/0.6	1.0/1.0	190/130	Dot hemorrhage, CWS <sup>†</sup> , macular star, disc edema	Preeclampsia	PIH**
11	F	56	Blurred vision	CF 25 cm/0.2	-	160/90	A-V crossing, macular star (os), blot hemorrhage	Hypertension	EH <sup>†</sup> , pontine hemorrhage
12	F	41	Blurred vision	0.5/0.2	0.6/0.4	200/110	Macular star, blot and flame-shaped hemorrhage	Renal failure, RH <sup>±</sup>	RH <sup>±</sup>
13	F	48	VA ↓	0.2/0.3	0.2/0.3	200/120	Disc edema, CWS <sup>†</sup> , blot and flame-shaped hemorrhage	Hypertension	RH <sup>±</sup> , died 2 years later
14	F	56	Blurred vision	CF 5 cm/0.3	CF 50 cm/0.5	198/112	Blot hemorrhage, disc edema, macular star	Hypertension	EH <sup>†</sup> , VF constricted (od), FAG: choroidopathy, optic neuropathy

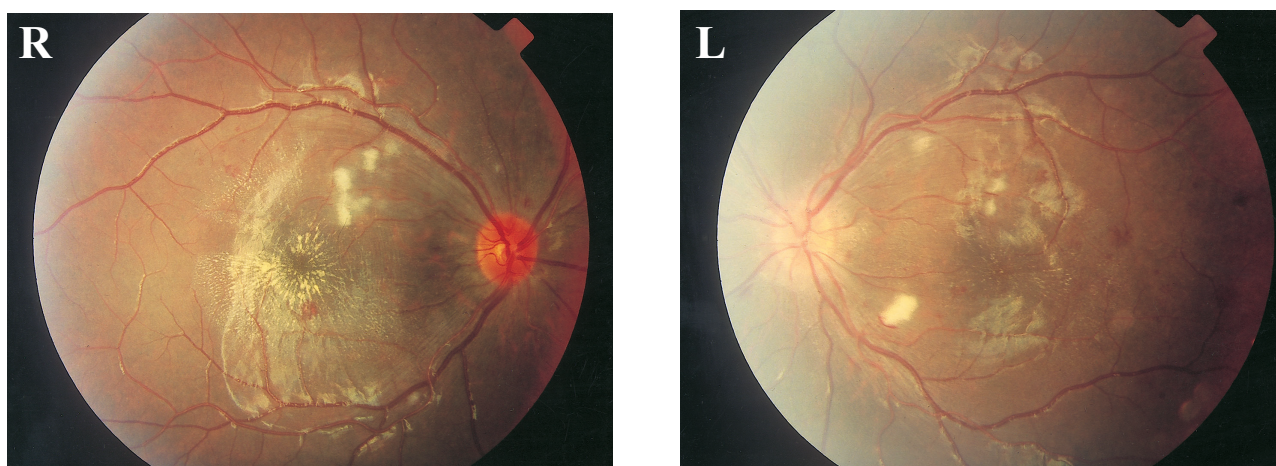
**Abbreviations:** BWL: body weight loss; CWS: cotton wool spots; EH: essential hypertension; RH: renogenic hypertension; PIH: pregnancy-induced hypertension; CF: counting finger; HM: hand motion

MHT in our ophthalmologic clinic. He had the chief complaint of acute blurred vision for several days. He also complained of headaches, fatigue, and body weight loss. His uncorrected visual acuity was 20/400 in both eyes. Slit lamp examinations were normal. Intraocular pressures were normal.

Ophthalmoscopy showed disc edema, macular star, intraretinal hemorrhage, and cotton wool spots at the posterior pole and the mid-peripheral retina in both eyes (Fig. 1). We immediately referred the patient to the pediatric department under a diagnosis of MHT. Wide fluctuations in blood pressure were observed

**Table 2.** Summary of General Data between the 2 Groups

	Group 1	Group 2	<i>p</i> value (Student's <i>t</i> -test)
No. of cases	6	8	
Mean age (year)	31 (range, 12~47)	43 (range, 22~56)	0.076
Mean systolic pressure (mmHg)	206 (range, 163~228)	196 (range, 160~249)	0.513
Mean diastolic pressure (mmHg)	143 (range, 100~180)	115 (range, 90~156)	0.060
Gender (F/M)	2 / 4	8 / 0	
Etiology (No.)	Essential hypertension (2) Renal disease (2) Pheochromocytoma (1) Pregnancy-induced hypertension (1)	Essential hypertension (3) Renal disease (3) Pregnancy-induced hypertension (2)	



**Fig. 1** Typical malignant hypertensive retinopathy in both eyes of a pheochromocytoma patient (case 2). Dot and blot hemorrhaging, cotton wool spots, mild disc swelling and hyperemia, hard exudates, and a macular star were revealed at the posterior pole and at the mid-periphery of the retina.

during hospitalization, varying from maximal systolic and diastolic pressures of 249 and 175 mmHg to minimums of 131 and 70 mmHg, respectively. Bilateral adrenal pheochromocytoma was diagnosed. One month after tumor resection and adequate blood pressure control, his uncorrected vision had improved to 20/20 in both eyes. The fundus lesions remained stable since that time, and only some macular exudates were noted 6 months later (Fig. 2).

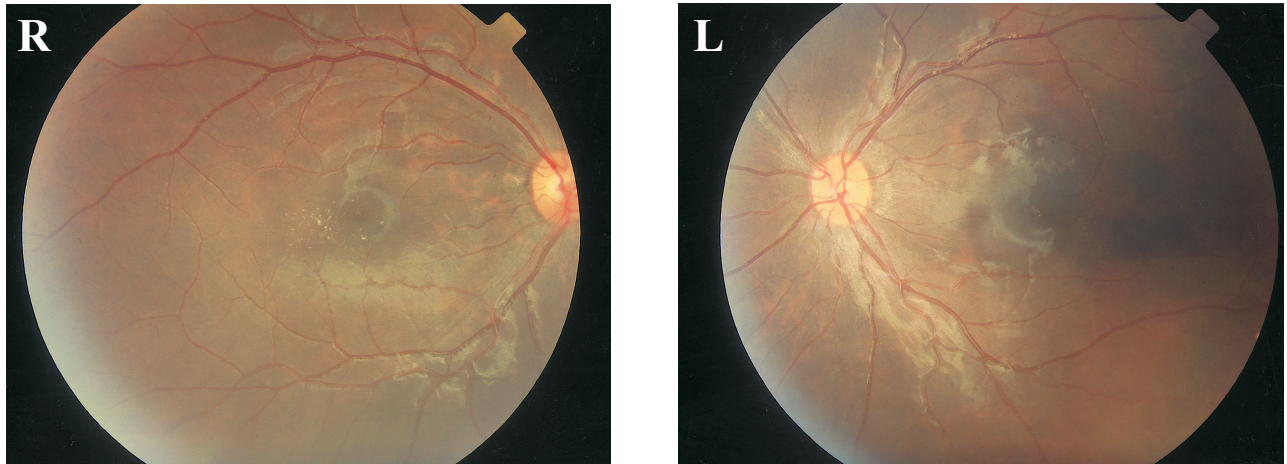
**Case 4.**

This 26-year-old female patient complained of blurred vision associated with nausea and headaches for 2.5 months. Acute renal failure was diagnosed when she visited our emergency room (ER). The

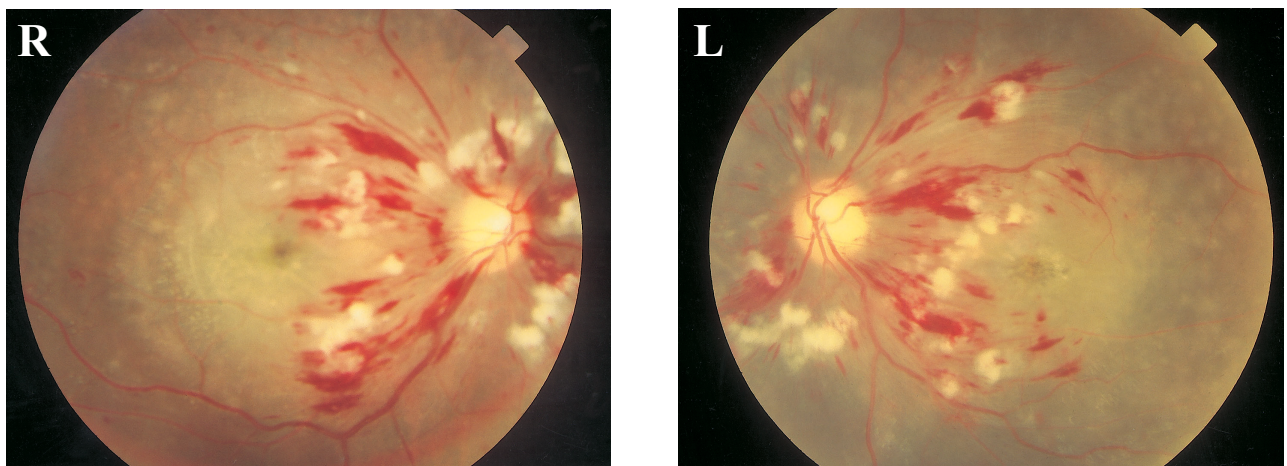
blood pressure first recorded in the ER was 200/120 mmHg. Her visual acuity through a pinhole was 20/200 (OD) and 20/700 (OS). The fundus photographs revealed flame-shaped, dot, and blot hemorrhaging as well as fluffy cotton wool spots. Mild disc edema and a macular star (OU) were also noted (Fig. 3). Fluorescence angiography also indicated choroidopathy (early dye leakage). After adequate blood pressure control and regular hemodialysis, her best-corrected visual acuity became 20/20 (OD) with a -5.00 D spectacle and 20/40 with -4.5 D spectacle (OS), where it remains.

**Case 5.**

This 32-year-old woman was a patient in whom



**Fig. 2** Six months later after a bilateral adrenalectomy had been performed and blood pressure was under control (case 2). The retinopathies showed nearly complete regression except for some hard exudates in the macula (OD).



**Fig. 3** Fundus photographs in an acute renal failure patient with MHT revealing flame-shaped, dot and blot hemorrhaging, and fluffy cotton wool spots around the discs. Mild disc edema and a macular star can also be noted.

pregnancy had induced hypertension. She was referred to our clinic for blurred vision associated with headaches for 4 days. Her best-corrected visual acuity (BCVA) was 20/400 in both eyes. The fundus photographs revealed dot hemorrhaging and mild disc edema. Exudative retinal detachment was noted in the inferior part of the fundus. Five days after her blood pressure was controlled, the bullous retinal detachment regressed. Three months later after her condition had stabilized, her BCVA was 20/100 in both eyes, and the fundic lesions had almost com-

pletely recovered except for some pigmentary change.

#### **Case 7.**

This 41-year-old female patient had a hypertension history for 8 years. She had taken no hypertension medicine and had paid no attention to her blood pressure. She suffered from a sudden onset of blurred vision, especially in her left eye for 1 day. Her uncorrected visual acuity was 20/50 (OD) and hand motion (HM) (OS); her blood pressure was

249/156 mmHg. The fundic lesions were disc edema in both eyes and a cherry red spot was noted in the left eye. She has been regularly followed-up in the hypertension clinic since that time. Her visual acuity was 20/20 (OD) and HM (OS) 6 months later.

## DISCUSSION

A number of different terms have been applied to severe, acute elevations in blood pressure. A hypertensive emergency is defined as a sudden increase in systolic and diastolic blood pressure associated with end organ damage of the central nerve system, the heart, or the kidneys, and clinical evidence that a life-threatening event is present or nearly at hand.<sup>(8)</sup> Ahemd et al.<sup>(9)</sup> investigated the clinical features and survival rate of 200 consecutive patients with malignant hypertension and accelerated hypertension and with fundus lesions of grade 3 or 4, and they concluded that malignant and accelerated hypertension were the same disease with similar clinical features and prognoses.

In order to remind ourselves of the importance of early detection and intervention with acute hypertension before definite target organ damage occurs, we reviewed the clinical and ophthalmologic findings of patients with malignant hypertension. According to the WHO classification, patients were included in our investigation when the observed severe hypertensive retinopathy was in stages III or IV. The systolic pressure in these patients should be higher than 160 mmHg, and the diastolic pressure higher than 90 mmHg. Hermann and Schubert reviewed past ophthalmologic studies and reported that the most frequently used definition of high blood pressure used in those studies was an elevated systolic blood pressure of 160 mmHg or higher, or a diastolic blood pressure of 95 mmHg or higher, in the absence of antihypertensive medicine.<sup>(10-13)</sup> Herein, we included patients whose systolic blood pressure had reached 160 mmHg or higher, or whose diastolic blood pressure had reached 90 mmHg or higher. The blood pressure recorded in group 2 patients might actually have been underestimated, because they were occasionally taking an antihypertensive agent. The blood pressure levels of some subjects were not as high as that found in normal malignant hypertension, but we know that it had occurred in our patients based on the clinical find-

ings and fundic lesions. Also, we know that there is no absolute level above which MHT always develops and below which it never occurs. Our patients visited ophthalmologists with symptoms of reduced visual acuity, and they considered their blood pressure to be normal or well controlled. According to the fundic lesions and a check of blood pressure, we know they actually were in a condition of uncontrolled high blood pressure or "false normotensive"--a life-threatening condition if no adequate treatment is administered. All of our patients were referred to internists for further blood pressure control (Two patients were lost follow up 6 and 10 months later, respectively, and 1 died of sepsis 2 years after MHT was diagnosed). The visual acuity of all patients subjectively or objectively improved.

The prevalence of malignant hypertension is unknown, but is generally accepted as being extremely rare. It can occur in patients of any age, but rarely does so in those older than 70 years. Patients may visit ophthalmologists with symptoms that include reduced visual acuity secondary to either hypertensive retinopathy, choroidopathy, or optic neuropathy, or because of cortical disease causing transient loss of color vision, visual hallucinations, and ocular motility disorders.<sup>(14)</sup> Heidbreder et al. found that severe hypertensive retinopathy was observed in patients with renal hypertension, especially in focal segmental sclerosis and membranoproliferative glomerulonephritis.<sup>(15)</sup> Mild hypertensive retinopathy was more prevalent in essential hypertension. Although the number of cases in the present cohort was small, it seemed that essential and renogenic hypertension remained the major etiology of MHT in our observations (The hypertension in 5 patients was renogenic, and was essential hypertension in the other 5).

There is no definition for typical "malignant hypertensive retinopathy" (MHR). Hayreh et al. distinguished retinopathy, choroidopathy, and optic neuropathy based on an animal model of malignant renal arterial hypertension.<sup>(16)</sup> Retinopathy appeared significantly earlier than did either choroidopathy or optic neuropathy. Hayreh et al. also described focal intraretinal periarterial transudates (FIPTs) as the specific retinal lesion of MHT.<sup>(17)</sup> However, only rarely have FIPTs been reported in the literature, perhaps because they are harder to detect in humans. Kahn et al. reported a case of MHT with fundus find-

ings that were compatible with FIPTs.<sup>(18)</sup> Wu et al. also presented a patient with pheochromocytoma and MHT, and they concluded that FIPTs are one of the early specific characteristic fundus lesions.<sup>(19)</sup> Fundus findings in systemic diseases such as systemic lupus erythematosus, diabetes mellitus, and other collagen vasculopathies may be similar to those in hypertensive retinopathy. The overlapping findings in malignant hypertensive retinopathy and in diabetic retinopathy can be confusing. MHR can cause optic nerve head swelling; and the optic nerve head will appear hyperfluorescent with fluorescein angiography (FAG). The typical microaneurysms with FAG strongly suggest diabetic retinopathy. The exudative retinopathy manifested in diabetes tends to affect the deep capillaries, while hemorrhaging accumulates in the outer plexiform and inner nuclear layer.<sup>(20)</sup> However, the hemorrhaging due to hypertension frequently arises from the superficial capillaries in the nerve fiber layer. All of these changes distinguish hypertensive retinopathy from that which is primarily diabetic. A systemic survey, including blood pressure and glycosylated hemoglobin (HbA1c), can provide an important clinical differential diagnosis. We excluded patients with systemic diseases whose fundus manifestations might have caused confusion.

As studied by Browning et al.<sup>(21)</sup> the worst visual prognosis was associated with the highest presented blood pressure, the worst visual acuity at presentation, and the longest duration of symptoms. It is likely that the visual prognosis is affected by factors present at the time of presentation. So, early recognition is essential. In our group 1 patients, the visual prognosis was satisfactory when the blood pressure and underlying disease were controlled. However, the blurred vision in some group 2 patients did not recover (cases 7, 13, and 14). They all had relatively higher blood pressure. MHT was complicated with a left central retinal artery occlusion in case 7 and with right anterior ischemic optic neuropathy in case 14. Case 9 had an occipital infarction, and case 11 had a pontine hemorrhage in spite of intensive treatment. It seems that there were more complications in group 2 patients. Maybe those patients had had a relatively longer duration of high blood pressure, and that resulted in more complications and related poorer prognoses.

Once hypertensive retinopathy is suspected in a

patient with acute vision decrease in both eyes, blood pressure should be checked immediately. An accurate and reliable measurement of blood pressure helps establish a diagnosis of MHT. Funduscopy is important in patients with hypertension because it offers the only possibility of detecting previously existing and newly occurring vascular damage at low cost and with little effort. In order to accurately diagnose and achieve early control of this critical condition, especially in patients with variable fluctuations in blood pressure, a detailed fundus examination and frequent blood pressure monitoring are mandatory.

## REFERENCES

1. Schachat PA. Medical Retina. Ed. III. Mosby, Inc. 2001; 1404-9.
2. Keith NM, Wagener HP, Kernohan JW. The syndrome of malignant hypertension. *Arch Intern Med* 1928;41:141-88.
3. Keith NM, Wagener HP, Barker NW. Some different types of essential hypertension: their course and prognosis. *Am J Med Sci* 1939;197:332-9.
4. Richard JG. Current therapy in nephrology and hypertension. The CV Mosby Company. 1984-1985;324-33.
5. World Health Organization. Arterial hypertension. World Health Organ Tech Rep Ser 1978;628:7-56.
6. McGregor E, Isles CG, Jay J L, Lever AF, Murray GD. Retinal changes in malignant hypertension. *Br. Med J* 1986;63292:233-4.
7. Catto MD. Management of renal hypertension. Lancaster: MTP, 1988:41-74.
8. Lawrence R K. Management of the hypertensive patient. Churchill Livingstone Inc. 1995;195-204.
9. Ahmed ME, Walker J M, Beevers DG, Beevers M. Lack of difference between malignant and accelerated hypertension. *Br Med J* 1986;292:235-7.
10. Hermann D, Schubert HD. Ocular manifestations of systemic hypertension. *Curr Opin Ophthalmol* 1998;9:69-72.
11. Klein R. Retinopathy in a population-based study. *Trans Am Ophth Soc* 1992;90:561-94.
12. Klein R, Klein B, Moss SE, Wang Q. Hypertension and retinopathy, arteriolar narrowing and arteriovenous nicking in a population. *Arch Ophthalmol* 1994;112:92-8.
13. Yu T, Mitchell P, Berry G, Li W, Wang J. Retinopathy in older persons without diabetes and its relationship to hypertension. *Arch Ophthalmol* 1998;116:83-9.
14. Mathews KD. Hypertensive encephalopathy in childhood. *J Child Neurol* 1996;11:193-6.
15. Heidbreder E, Huller U, Schafer B, Heidland A. Severe hypertensive retinopathy. Increased incidence in renoparenchymal hypertension. *Am J Nephrol* 1987;7:394-

- 400.
16. Hayreh S, Servais G, Viridi P, Macus M, Rojas P, Woolson R. Fundus lesions in malignant hypertension: III. Arterial blood pressure, biochemical, and fundus changes. *Ophthalmology* 1986;93:45-59.
  17. Hayreh S, Servais S, Viridi P. Fundus lesions in malignant hypertension: IV Focal intraretinal periarterial transudates. *Ophthalmology* 1986;93:60-73.
  18. Kahn MT, Liao HR. Focal intraretinal periarteriolar transudates in malignant hypertensive retinopathy- A case report. *Transactions of the ophthalmological society of the Republic of China* 1987;26:474-7.
  19. Wu WC, Chen ZJ, Wang HZ. The early characteristic finding in malignant hypertensive retinopathy. *J Clin Ophthalmology* 1988;6:5-6 (in Chinese).
  20. Olk RJ. *Diabetic retinopathy*. J.B. Lippincott Company. 1993;176-7.
  21. Browning AC, Mengher LS, Gregson RM, Amoaku WM. Visual outcome of malignant hypertension in young people. *Arch Dis Child* 2001;85:401-3.



## 惡性高血壓病人之臨床及眼底表現

陳怡豪 郭錫恭 郭明倫

**目的：** 呈現惡性高血壓病人之臨床及眼底表現。

**方法：** 回顧及分析於1995到2000年在高雄長庚醫院的高血壓性視網膜病變之病人。並由視網膜科醫師再判斷彩色眼底攝影圖，篩選出惡性高血壓性視網膜病變之病人共14位。在病人症狀發生時，至少要有一次高血壓數值被記錄在病歷上。可能影響判斷的全身性疾病均被排除。

**結果：** 共有14個病人。其中6人(group 1)並無高血壓病史。另8位(group 2)是曾有高血壓病史但並未服用藥物，或尚無適當而有效治療者。病人因視力模糊而求診。兩組惡性高血壓病人的年齡及血壓並無明顯差異。Group 2病人發生眼或腦中風或腎衰竭者似乎較多。

**結論：** 早期診斷惡性高血壓病人，眼底檢查及血壓的測量是重要的。對於血壓變動較大的病人，其眼底表現是有追蹤價值的。  
(長庚醫誌 2003;26:669-77)

**關鍵字：** 惡性高血壓，惡性高血壓性視網膜病變。

---

長庚紀念醫院 高雄院區 眼科

受文日期：民國92年2月18日；接受刊載：民國92年4月24日。

索取抽印本處：郭錫恭醫師，長庚紀念醫院 眼科。高雄縣833鳥松鄉大埤路123號。Tel.: (07)7317123轉2801; Fax: (07)7317123轉2830; E-mail: d2767@cgmh.org.tw