

Transitional Cell Carcinoma Metastasis to Arm Skin from the Renal Pelvis

Chin-Yew Lin, MD; Chiung-Tsung Lee¹, MD; Jen-Seng Huang², MD;
Liang-Che Chang, MD

Metastases of renal pelvic transitional cell carcinoma (TCC) to the skin and subcutaneous tissues are extremely rare. Similar to metastases from other genitourinary tract organs, they commonly affect middle-aged or elderly men, generally herald a rapid progression, and are associated with a poor outcome. Skin metastatic lesions present as painful or nontender nodules, and a vascular or even a zosteriform appearance may occasionally be noted. The latter is often confused with herpes zoster infection. The diagnosis is usually confirmed by histopathological findings of biopsy specimens. Cutaneous metastases generally carry a dismal prognosis, with survival of only several months. We herein present a case of renal pelvic TCC with cutaneous metastases to the bilateral arms and epigastric region 1.5 years after diagnosis of the primary lesion. The patient's condition rapidly deteriorated, and she expired 4 weeks later. We present this rare case to highlight the possibility of cutaneous metastases from renal pelvis TCC and with the hope to increase awareness of the rapidly fatal course of such patients. (*Chang Gung Med J* 2003;26:525-9)

Key words: transitional cell carcinoma, renal pelvis, cutaneous metastasis.

Transitional cell carcinoma (TCC) of the genitourinary system rarely metastasizes to the skin. Most reported cases originate from the urinary bladder rather than the renal pelvis. The incidence is reported to be less than 1%, and ranges from 0.18% to 2.0% for TCC of the urinary bladder.⁽¹⁾ The rate of skin metastasis from renal pelvic TCC remains unknown.⁽²⁾ Overall, there is a male predominance, mainly middle-aged or elderly men, with a lower incidence for women.⁽³⁻⁵⁾ It may occur at the time of diagnosis, or appear months or even years after the primary lesions are found.⁽⁶⁾ Rarely, it may present as the first symptom of the disease.⁽⁷⁾ In general, survival time after the presence of skin metastases from the genitourinary system is short.^(1,5,6,8,9)

We present a rare case of renal pelvic TCC with multiple cutaneous metastases involving the bilateral

arms and the epigastric region. The patient died of the disease 4 weeks after the cutaneous metastases were diagnosed.

CASE REPORT

A 68-year-old woman was admitted to our hospital presenting bilateral arm nodules and an epigastric mass. The lesions were tender, slightly firm, and fixed. Excisional biopsies of lesions on both arms revealed metastatic TCC (Fig. 1A, B).

One and half years before this admission, she had undergone a right nephroureterectomy procedure due to a renal pelvic tumor. The final diagnosis was renal pelvic TCC, grade III, invading the renal parenchyma (Fig. 2). No angiolymphatic vessel invasion was found at that time, and the ureter was

From the Department of Pathology, ¹Department of General Surgery, ²Department of Oncology, Chang Gung Memorial Hospital, Keelung.

Received: Sep. 9, 2002; Accepted: Jan. 6, 2003

Address for reprints: Dr. Chiung-Tsung Lee, Department of General Surgery, Chang Gung Memorial Hospital, 222, Maijin Rd., Anle Chiu, Keelung, Taiwan 204, R.O.C. Tel.: 886-2-24313131 ext. 2640; Fax: 886-2-24313131 ext. 2640; E-mail: naga66@cgmh.org.tw

tumor free. One year after the operation, local recurrent lesions involving the duodenum, right psoas muscle, and a portion of the pancreatic head were found by abdominal computed tomography (CT) scans. She then received palliative chemotherapy with the regimen of 50 mg/m² methotrexate (MTX) and 50 mg/m² cisplatin (CDDP) and palliative radiotherapy with a dosage of 180 cGy per fraction over the unresectable recurrent lesions, including the para-aortic lymph nodes with accumulative doses up to 5040 cGy from August to October 2001. No complications were noted.

On this admission for the cutaneous mass, fur-

ther study using abdominal sonography and CT showed multiple nodular lesions measuring up to 4 cm in diameter in the liver parenchyma. Few of them showed central tumor necrosis. Transartery embolization of the liver tumors with 3 ml lipiodol was smoothly performed. In addition, the left kidney was also invaded by tumor cells. Due to cardiomegaly and dyspnea, a 2-dimensional cardiac ultrasonographic examination was performed. Pericardial effusion (200 ml) and numerous pericardial nodular lesions were noted. Chest radiography showed a soft tissue mass over the right lower lung with bilateral pleural effusion. No further histologi-

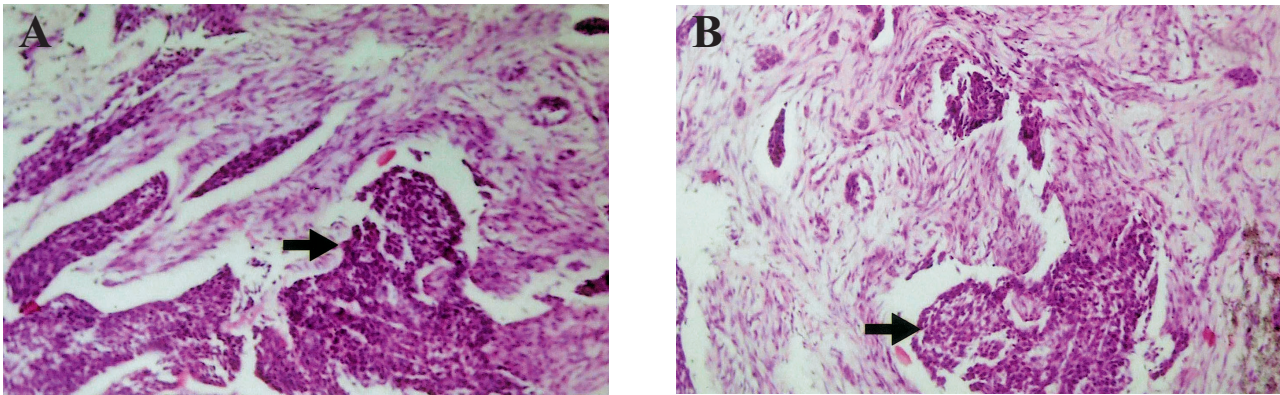


Fig. 1 (A) Photomicrograph of a right arm nodular lesion revealing infiltrating sheets or nests of metastatic neoplastic transitional cells (arrow) among desmoplastic stroma (H&E stain, 200 \times). (B) Microscopic features of a left arm nodular lesion displaying similar features as shown in Fig. 1A. Sheets of neoplastic cells are shown by the arrow (H&E stain, 200 \times).

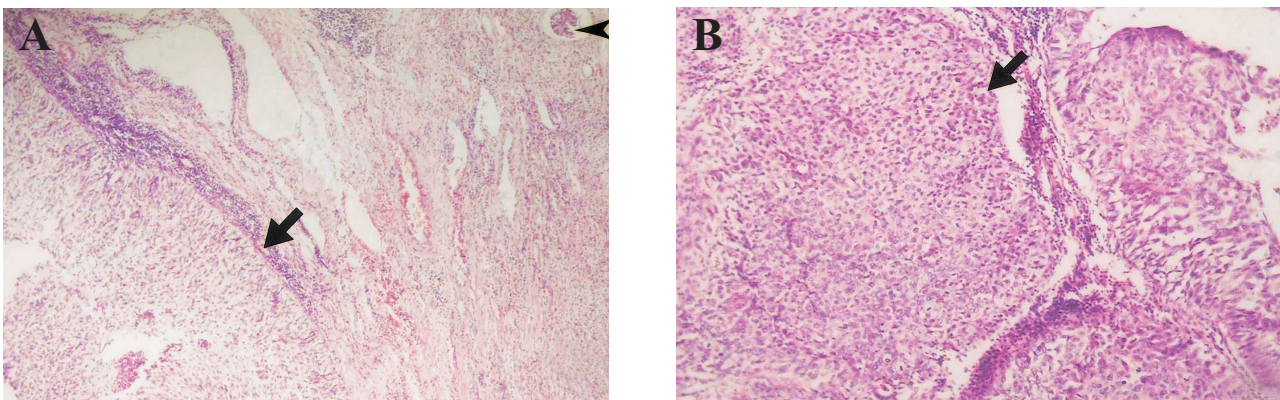


Fig. 2 (A) Photomicrograph of the renal pelvis showing the presence of neoplastic cells resembling high-grade transitional cell carcinoma (arrow). The malignant cells have invaded the renal parenchyma. The renal stroma shows increased chronic inflammatory cell infiltration and mild fibrosis. A remnant glomerulus can be seen (arrowhead) (H&E stain, 100 \times). (B) Higher magnification of microscopic features reveals solid nests (arrow) of tumor cells with pleomorphic nuclei and a moderate amount of eosinophilic cytoplasm. Chronic inflammatory cell infiltrates are present within the thin fibrous septa (H&E stain, 200 \times).

cal examination was made in any lesions. The patient's condition rapidly deteriorated, and she expired 4 weeks after the occurrence of the cutaneous metastases.

DISCUSSION

TCC of the genitourinary tract with cutaneous metastases is a rare condition, especially in the case of TCC of the renal pelvis. The most frequent metastatic sites are regional lymph nodes, such as the iliac, obturator, and hypogastric nodes in urinary bladder TCC.^(7,8,10,11) Distant metastases to lungs, bones, liver, kidneys, peritoneum, heart, and brain are also commonly seen.^(10,12) The mechanisms of metastasis include direct implantation via lymphatic channels, as well as hematogenous spread.^(5,8,10)

The patterns of metastatic cutaneous lesions vary enormously. They are generally solitary or multiple in appearance. Brownstein et al. described 3 clinical features of metastatic cutaneous lesions, including a nodular type, inflammatory type (carcinoma erysipelatoides), and sclerodermoid type.⁽¹³⁾ In addition, a rarer zosteriform lesion has also been documented.^(2,9,12,14) An associated epidermal nevus or a painful, vascular-appearing cutaneous nodule may occur on occasion.^(9,15)

Metastatic skin lesions from genitourinary TCC are always located on the head, face, neck, trunk, abdomen, suprapubic region, or extremities.^(2,7-9,13,16) Occasionally, scrotal skin and even ocular region involvement has also been reported.^(10,17) Our case revealed solitary, hard, firm nodular lesions over the skin of the bilateral arms and epigastric region.

Diagnosis is usually established by microscopic examination of excisional biopsy specimens. There is one case report of tumor diagnosis by fine needle aspiration cytology alone, however.⁽¹¹⁾ Among reported cases, cutaneous metastases of TCC almost exclusively show high-grade differentiation of histological grading at the primary genitourinary sites.^(1,5,7,11,16) Furthermore, the invasiveness of malignant cells into the renal parenchyma, as in our case, with or without angiolymphatic involvement, may increase the possibility of cutaneous metastasis.^(2,6)

To date, there are no definitive clinical laboratory data available for early detection of the lesion. In spite of aggressive treatment, patients inevitably die within a short time from the disease after cutaneous

metastases occur. Currently, no effective treatment can be recommended.

TCC of the renal pelvis has a similar epidemiology, clinical features, and pathologic findings to those of TCC of the bladder.^(3,4) The prognosis is usually indicated by histological grading, stage, and multiplicity of the tumor.⁽¹⁸⁾ Our patient showed TCC of the renal pelvis with grade III differentiation and direct invasion of the renal parenchymal and stromal tissue but without lymphatic involvement at the primary site. One year after the nephroureterectomy, local recurrence had progressed and involved the pancreas and liver. Eventually, skin metastases developed. Hematogenous or lymphatic spread is a reasonable pathway for our case, although lymphatic invasion was not initially identified in the resected kidney. As described in previous reports, the prognosis is extremely dismal, and survival times are normally measured in months rather than in years. Our patient survived for 4 weeks after the appearance of the cutaneous metastases.

In conclusion, skin metastases may occur at any time after the initial diagnosis at the primary site. They should be considered to be a late event and represent an extremely rare complication in the case of advanced genitourinary tract TCC, especially that of the renal pelvis. Their occurrence is a sign of short survival.

REFERENCES

1. Fujita K, Sakamoto Y, Fujime M, Kitagawa R. Two cases of inflammatory skin metastasis from transitional cell carcinoma of the urinary bladder. *Urol Int* 1994;53:114-6.
2. Ando K, Goto Y, Kato K, Murase T, Matsumoto Y, Ohashi M. Zosteriform inflammatory metastatic carcinoma from transitional cell carcinoma of the renal pelvis. *J Am Acad Dermatol* 1994;31:284-6.
3. Kvist E, Lauritaen AF, Bredesen J, Luke M, Sjolin KE. A comparative study of transitional cell tumors of the bladder and upper urinary tract. *Cancer* 1988;61:2109-12.
4. Mazeman E. Tumors of the upper urinary tract calyces, renal pelvis and ureter. *Eur Urol* 1976;2:120-8.
5. Safer LF, Pirozzi DJ. Extensive cutaneous metastases from urinary bladder carcinoma. *Cutis* 1980;26:485-500.
6. Chitale SV, Morrow DR, Patel R, Gaches CGC, Ball RY. Cutaneous metastases from transitional cell carcinomas of the bladder and renal pelvis. *Br J Urol* 1997;79:292-3.
7. Serel TA, Ozdemir G, Yaman LS, Ozdemir H. Skin metastasis of bladder carcinoma. A case report. *Mater Med Pol* 1994;26:113-4.

8. Beautyman EJ, Garcia CJ, Sibulkin D, Snyder PB. Transitional cell bladder carcinoma metastatic to the skin. *Arch Dermatol* 1983;119:705-7.
9. Zirwas MJ, Hunt S, Logan TF, Abernethy JL, Seraly MP. A painful cutaneous nodule as the presentation of metastatic transitional cell carcinoma of the renal pelvis. *J Am Acad Dermatol* 2000;42:867-8.
10. Saito S. Solitary cutaneous metastasis of superficial bladder cancer. *Urol Int* 1998;61:126-7.
11. Kumar PV, Salimi B, Musallaye A, Tadayyon A. Subcutaneous metastases from transitional cell carcinoma of bladder diagnosed by fine needle aspiration biopsy. A case report. *Acta Cytol* 2000;44:657-60.
12. Elston DM, Tuthill RJ, Pierson J, Marden JD, Bergfeld WF. Carcinoma erysipeloides resulting from genitourinary cancer. *J Am Acad Dermatol* 1996;35:993-5.
13. Brownstein MH, Helwig EB. Spread of tumors to the skin. *Arch Dermatol* 1973;107:80-6.
14. Jaworsky C, Bergfeld WF. Metastatic transitional cell carcinoma mimicking zoster sine herpete. *Arch Dermatol* 1986;122:1357-8.
15. Rongioletti F, Rebora A. Epidermal nevus with transitional cell carcinomas of the urinary tract. *J Am Acad Dermatol* 1991;25:856-8.
16. Kubota Y, Mir LB, Nakada T, Sasagawa I, Suzuki H, Aoyama N. Successful treatment of metastatic skin lesions with electrochemotherapy. *J Urol* 1998;160: 1426.
17. Resnick MI, O'Connor VJ Jr, Grayback JT. Metastases to the eye from transitional cell carcinoma of the bladder. *J Urol* 1975;114:722-4.
18. Corrado F, Ferri C, Mannini D. Transitional cell carcinoma of the upper urinary tract: Evaluation of prognostic factors by histopathology and flow cytometric analysis. *J Urol* 1991;145:1159-63.

腎盂移行上皮細胞癌轉移到雙側手臂皮膚

林進耀 李炯宗¹ 黃仁聖² 張良慈

腎盂移行上皮細胞癌轉移到皮膚與皮下組織的案例相當罕見。如同其他生殖泌尿系統之移行上皮細胞癌，它好發於中年或老年男性，病程相當快速且預後極差，通常只有幾個月的存活率。皮膚的轉移癌不一定會有疼痛的感覺；有時，也會以血管或以類皰疹形態來呈現；後者通常易與帶狀皰疹混淆，但經由病理組織切片檢查即可做出正確的診斷。在此，我們提出一個罕見之腎盂移行上皮細胞癌，於診斷一年半後，轉移到兩側手臂皮膚的案例。病人的病情快速惡化並於四週後死亡。我們提出此個案，希望能提醒大家，腎盂移行上皮細胞癌與膀胱移行上皮細胞癌一樣，可轉移到皮膚；一旦發生，預後都很差，應多加留意。(長庚醫誌 2003;26:525-9)

關鍵字：移行上皮細胞癌，腎盂，皮膚轉移。

長庚紀念醫院 基隆院區 病理科，¹一般外科，²腫瘤科

受文日期：民國91年9月9日；接受刊載：民國92年1月6日。

索取抽印本處：李炯宗醫師，長庚紀念醫院 一般外科。基隆市麥金路222號。Tel.: (02)24313131轉2640; Fax: (02)24313131轉2640; E-mail: naga66@cgmh.org.tw