

## Endogenous *Candida* Endophthalmitis after Two Consecutive Procedures of Suction Dilatation and Curettage

Travis Shih-Yen Chang, MD; William Chen-Yen Chen, MD;  
Henry Shen-Li Chen, MD; Howard Wen-Hao Lee, MD

Endogenous *Candida* endophthalmitis (ECE) is a rare disease. We present a patient with *Candida* endophthalmitis after two consecutive procedures of suction dilatation and curettage for elective abortion. A 24-year-old single woman who received a suction dilatation and curettage one week ago developed pain and blurred vision in the right eye. Endogenous *Candida* endophthalmitis was diagnosed and treated with oral fluconazole and pars plana vitrectomy with adjunction of intravitreal amphotericin B injection. The vitreous culture revealed *Candida albicans*. The vitreous inflammation subsided greatly after the initial treatment but flared up after the second dilatation and curettage for incomplete abortion 5 days after the vitrectomy. The oral fluconazole was replaced by intravenous amphotericin B, and a second vitrectomy with injection of intravitreal amphotericin B was performed. Postoperatively, the intraocular inflammation resolved gradually. Six months after the second vitrectomy, the best-corrected visual acuity in the right eye was 20/25. The excellent visual acuity of this patient was attributed to the early diagnosis and aggressive treatment. For patients with mild disease, less toxic oral fluconazole as the systemic antifungal agent instead of more toxic intravenous amphotericin B has been recommended. For those with advanced disease, intravitreal amphotericin B in conjunction with vitrectomy has been advocated by many eye surgeons. (*Chang Gung Med J* 2002;25:778-82)

**Key words:** endophthalmitis, *Candida albicans*, suction dilatation and curettage.

Endogenous *Candida* endophthalmitis (ECE) has rarely been reported after induced abortion and in the postpartum states in young healthy women.<sup>(1,2)</sup> It is usually noted in immunocompromised patients or intravenous drug abusers. In healthy women after the procedure of suction dilatation and curettage, ECE was reported once in the literature. We present a patient who received two consecutive procedures of suction dilatation and curettage for incomplete abortion and developed ECE after the first suction dilatation and curettage. In spite of heavy vitreous inflammation, the final visual acuity of the patient

was excellent due to the early diagnosis and aggressive treatment.

### CASE REPORT

A 24-year-old woman presented to our clinic with a 2-day history of blurred vision and pain in the right eye. Tracing her history, she received a suction dilatation and curettage 1 week prior to the onset of symptoms. There was no previous ocular or medical history. On initial examination, her best-corrected visual acuity was light-sense positive only in the

---

From the Department of Ophthalmology, Chang Gung Memorial Hospital, Taipei.

Received: Jul. 31, 2001; Accepted: Mar. 4, 2002

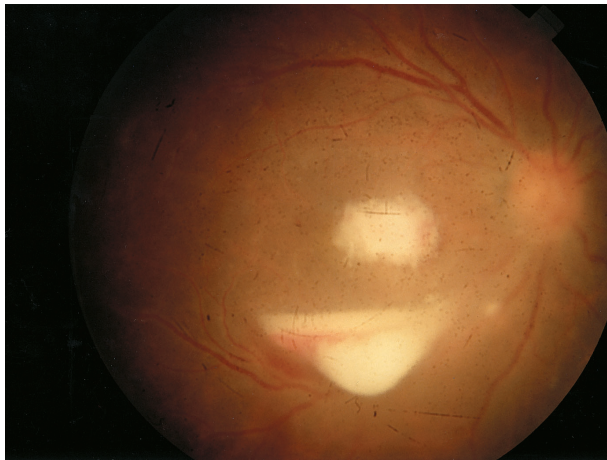
Address for reprints: Dr. Howard Wen-Hao Lee, Department of Ophthalmology, Chang Gung Memorial Hospital, 199, Tung-Hwa North Road, Taipei 105, Taiwan, R.O.C. Tel.: 886-2-27135211 ext. 3431; Fax: 886-2- 27191194; E-mail: Lee393aa@ms31.hinet.net

right eye and 20/20 in the left eye. The slit lamp examination of the right eye showed a mild edematous cornea with diffuse keratic precipitates. The anterior chamber was deep with 3+ cells and flared, trace hypopyon with exudative membrane over the pupil. The fundoscopic examination of the right eye showed fluffy vitreous opacity, subhyaloidal hypopyon and dense submacular infiltration (Fig. 1). Findings from the left eye were normal.

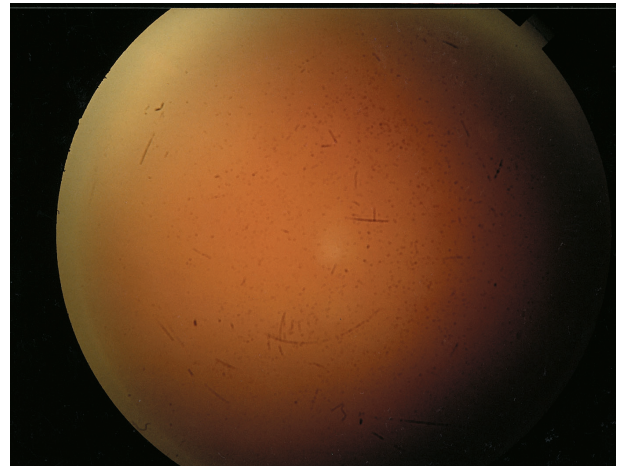
Based on the clinical features, 200 mg of oral fluconazole per day was initiated promptly under the impression of ECE. The trans pars plana vitrectomy was performed to remove the intravitreal fungal balls and abscess on the second day. The endophotocoag-

ulation was performed while peeling the adhesive membrane. At the end of the surgery, the intravitreal amphotericin B and antibiotics were injected. The vitreous sample was sent for smear and culture. The Gram stain showed abundant yeast-like microorganism and the fungal culture grew *Candida albicans* (Fig. 2). The blood culture was negative. The vitreous inflammation and subretinal infiltration were greatly resolved after the surgery.

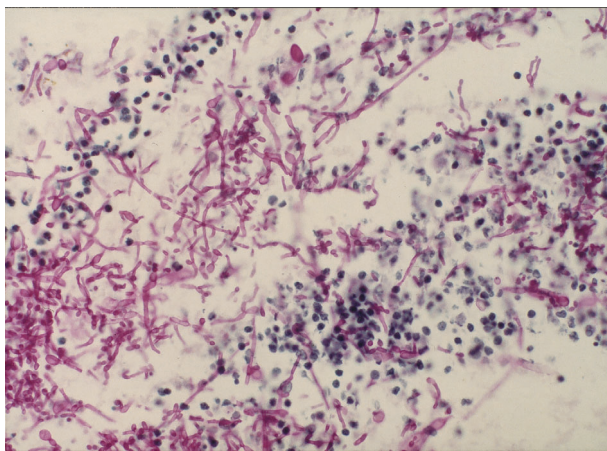
The gynecologist was consulted and the transvaginal echography revealed a gestational sac structure in the uterus. A second suction dilatation and curettage was performed 5 days after the vitrectomy under the impression of incomplete abortion.



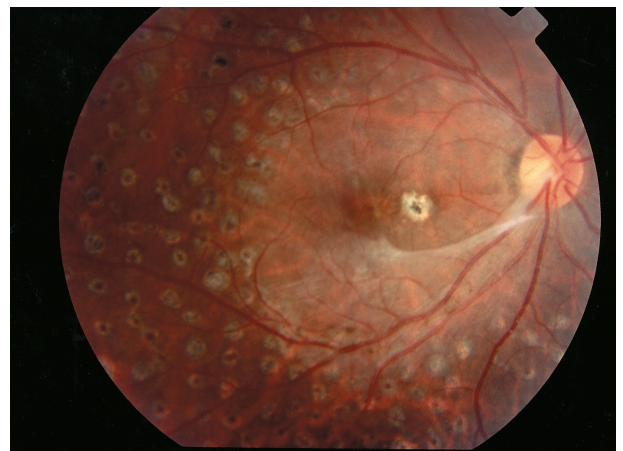
**Fig. 1** Initial presentation with dense submacular infiltration and subhyaloidal hypopyon.



**Fig. 3** Diffuse vitreous opacity with posterior pole obscured.



**Fig. 2** Gram stain of the vitreous sample revealed abundant yeast-like organism ( $\times 400$ ).



**Fig. 4** A residual fibrotic band at the inferior macula with delicate epimacular membrane and a parafoveal scar.

However, 3 days after the suction dilatation and curettage, the vitreous inflammation became more severe, and some exudate-like linear opacities which were difficult to differentiate with retinal detachment were noted on the echographic examination (Fig. 3). A second vitrectomy with intravitreal injection of amphotericin B was performed, and an increment of 10 mg intravenous amphotericin B per day to up to 25 mg per day was initiated. Postoperatively, the intraocular inflammation gradually subsided. Six months after the second vitrectomy, her best-corrected visual acuity was 20/25 in the right eye. A residual traction band with delicate epimacular membrane and a parafoveal scar were noted (Fig. 4). The optical coherence tomography demonstrated a flat fovea and a parafoveal epimacular membrane.

## DISCUSSION

Endogenous *Candida* endophthalmitis has typically been noted in patients with debilitating illness, compromised immune states, intravenous drug addiction, and prolonged usage of indwelling catheters and antibiotics.<sup>(3-5)</sup> It has rarely been reported after undergoing suction dilatation and curettage.<sup>(1)</sup> Especially rare, as in this patient, the vitreous inflammation flared up after the second suction dilatation and curettage. The rate of development of ECE in patients with candidemia has been reported to range from 28% to 45%.<sup>(6)</sup> In spite of negative results of blood cultures, we presumed that the candidemia following dilatation and curettage increased the intravitreal fungal load on the basis of the temporal relationship.

For the treatment of ECE, antifungal agents were used systemically or locally with or without the adjunction of vitrectomy. The intravenous amphotericin B has been the treatment of choice for systemic *Candida* infection. However, when given systemically, it has poor vitreous penetration and a variety of side effects such as nephrotoxicity and anemia.<sup>(7,8)</sup> It is recommended that amphotericin B is administered intravitreally at the time of vitrectomy and intravenously for disseminated candidiasis.<sup>(9)</sup> Fluconazole, an azole derivative, has good intraocular penetration, anti-fungal activity and minimal toxicity. The successful treatment of ECE with only oral fluconazole in patients with mild cases of the disease or oral fluconazole combined with vitrectomy in

patients with advanced cases of the disease has been reported.<sup>(10,11)</sup> Courses of 6-12 weeks of therapy are typically required.<sup>(12)</sup> Thus, less toxic orally administered anti-fungal agents in conjunction with vitrectomy and intravitreal amphotericin B have generally been recommended.<sup>(6,9)</sup>

In this patient, the initial vitreous inflammation was marked with fluffy balls and subhyaloidal hypopyon. Oral fluconazole was administered promptly and pars plana vitrectomy with intravitreal amphotericin B injection was performed. The unusual relapse of vitreous inflammation after the second suction dilatation and curettage was cleared with the second vitrectomy in conjunction with intravitreal and intravenous amphotericin B. It has been reported that the incidence of endogenous fungal endophthalmitis may be reduced if candidemia is treated promptly with intravenous amphotericin B.<sup>(6)</sup> The fluconazole was replaced by intravenous amphotericin B because of a highly suggested treatment failure of systemic candidiasis with fluconazole.

The visual prognoses of ECE vary greatly. Final outcomes of visual acuity depend mostly on the site of initial choroiditis. If the macula is spared and pre-retinal membranes can be effectively removed, visual acuity results can be exceedingly good.<sup>(13)</sup> Also, it depends on the severity of the vitritis and the treatment method used. According to the classification proposed by Ishibashi, half of the eyes in which vitrectomy had been performed at stage IIb achieved a postoperative visual acuity of 20/40 or better and none had a visual acuity of less than 20/700.<sup>(14)</sup> In addition, we emphasize that final vision is better in patient with a shorter interval between onset of symptoms and initiation of antifungal treatment.<sup>(9,15)</sup> The final vision of this patient was excellent when compared with patient results in previous reports, especially, when considering the relapsed inflammation. It was worth noting that in case of endogenous endophthalmitis, when vitreous inflammation flares up after an invasive procedure, it should be managed promptly and aggressively.

## REFERENCES

1. Chen SJ, Chung YM, Liu JH. Endogenous *Candida* endophthalmitis after induced abortion. *Am J Ophthalmol* 1998;125:873-5.
2. Cantrill HL, Rodman WP, Ramsay RC, Knobloch WH.

- Postpartum *Candida* Endophthalmitis. JAMA 1980; 243:1163-5.
3. Stanbury RM, Chignell AH, Graham EM. Endogenous *Candida* endophthalmitis with no apparent predisposing factors. Eye 1998;12:21-3.
  4. Augsten R, Konigsdorffer E, Strobel J. Endogenous endophthalmitis in severe generalized diseases. Ophthalmologe 1997;94:397-400.
  5. Klein A, Haller-Schober EM, Faulborn J. *Candida* endophthalmitis in drug abuse: case report. Ophthalmologe 2000;97:619-22.
  6. Essman TF, Flynn HW, Smiddy WE, Brod RD, Murray TG, Davis JL, Rubsamen PE. Treatment outcomes in a 10-year study of endogenous fungal endophthalmitis. Ophthalmic Surg Lasers 1997;28:185-94.
  7. Green WR, Bennett JE, Goos RD. Ocular penetration of amphotericin B. Arch Ophthalmol 1965;73:769-75.
  8. Utz JP, Bennet JC, Brandriss MW, Butler WT, Hill GJ. Amphotericin B toxicity: combined clinical staff conference at the National Institute of Health. Ann Intern Med. 1964;61:334-8.
  9. Brod RD, Flynn HW Jr, Clarkson JG. Endogenous *Candida* endophthalmitis: management without intravenous amphotericin B. Ophthalmology 1990;97:666-74.
  10. Penk A, Pittrow L. Status of fluconazole in the therapy of endogenous *Candida* endophthalmitis. Mycoses 1998;41 Suppl 2:41-4.
  11. Christmas NJ, Smiddy WE. Vitrectomy and systemic fluconazole for treatment of endogenous fungal endophthalmitis. Ophthalmic Surg Lasers 1996;27: 1012-8.
  12. Rex JH, Walsh TJ, Sobel JD, Filler SG, Pappas PG, Dismukes WE, Edwards JE. Practice guidelines for the treatment of candidiasis. Clin Infect Dis 2000;30:662-78.
  13. Smiddy WE. Treatment outcomes of endogenous fungal endophthalmitis. Curr Opin Ophthalmol 1998;9:66-70.
  14. Sato Y, Miyasaka S, Shimada H. Prognosis of endogenous fungal endophthalmitis and utility of Ishibashi's classification. Jpn J Ophthalmol 2001;45:181-6.
  15. Schrader W. Endogenous *Candida* endophthalmitis. Early diagnosis and early vitrectomy improve the prognosis. Fortschritte der ophthalmologie 1990;87:331-5.



## 二次人工流產後造成內生性念珠菌眼內炎

張世彥 陳成彥 陳賢立 李文浩

內生性念珠菌眼內炎是一種少見的疾病，多見於處於免疫功能低落狀態之病患，發生於健康年輕女性接受人工流產之後則屬罕見。而此案例是不完全流產，再接受第二次人工流產後，眼內炎反應又惡化。

一位24歲女性，因未婚懷孕而接受人工流產，4天後發生右眼紅痛及視力下降，診斷為內生性念珠菌眼內炎。經口服抗黴菌藥物fluconazole，及玻璃體切除術併施打玻璃體內amphotericin B治療後，發炎現象得到緩解。玻璃體抽取物培養證實為白色念珠菌。陰道超音波發現有不完全流產現象，於玻璃體切除術後第5天，接受第二次人工流產。於人工流產後第3天，眼內發炎反應突然增強，而必須接受第二次玻璃體切除術與玻璃體內和靜脈amphotericin B注射。之後眼內發炎逐漸消除，手術後6個月，患眼矯正視力恢復至0.8。

內生性念珠菌眼內炎須以全身性抗黴菌藥物治療，之前使用靜脈注射之amphotericin B因全身性副作用大，目前在輕度念珠菌眼內炎多先以口服fluconazole治療；眼內炎嚴重者須施以玻璃體切除術及玻璃體內amphotericin B注射。由此案例可知：早期診斷及積極治療是決定視力預後的重要因素。(長庚醫誌 2002;25:778-82)

**關鍵字：**眼內炎，念珠菌，人工流產。