Primary Carcinoid Tumor of the Testis: Case Report

Ying-Hsu Chang, MD; Cheng-Keng Chuang, MD, PhD; Chun-Te Wu, MD; Kwai-Fong Ng[1], MD, Shuen-Kuei Liao[2], PhD

Carcinoid tumor of the testis is exceedingly rare. Most carcinoid tumors occur in the appendix or ileocecal region (85%), while others are found in the lung, liver, and genitourinary tract (15%). A primary carcinoid testis tumor may originate from argentaffin or Kulchitsky's cells, which are located in the Lieberkuhn crypt. Preoperative ultrasound may show a solid, hypoechoic, well-defined margin mass combined with calcification or a cyst. Differential diagnosis of the ultrasound appearance is testicular tumor (teratoma/embryonal cell carcinoma), epidermoid tumor, tuberculous epididymo-orchitis, and the result of trauma. Radical orchiectomy remains the main treatment for a carcinoid testis tumor. Grossly, surgical removal of the tumor presents with a solid mass, tan to white in color. Immunohistochemical study shows that tumor cells are diffusely reactive to antibodies to keratins AE1 and AE3, chromogranin-A, neuron-specific enolase (NSE), and synaptophysin. A pure primary testicular carcinoid tumor has been treated as a benign lesion, while metastatic carcinoid tumor has a poor prognosis regardless of the primary site. To rule out the possibility of metastasis resulting from an extra-testicular primary carcinoid, careful and thorough postoperative whole body surveys are important. Chest X-ray, chest computed tomogram (CT), abdominal and pelvic CT, and octreotide scintigraphy are indicated. We herein describe a case of primary carcinoid tumor of the testis and review the literature. *(Chang Gung Med 2002;25:695-9)*

Key words: carcinoid tumor, testis tumor, ultrasound.

Most carcinoid tumors occur in the gastrointestinal tract, especially in the appendix or ileocecal region (85%), while others are found in the lung, liver, and genitourinary tract (15%).(1) Carcinoid tumors of the testis are quite rare, and account for 0.23% of testis tumors.(2) In 1930, Cope reported the first case of metastatic testicular carcinoid tumor from the small bowel,(3) and in 1954, Simon et al. reported the first case of primary carcinoid tumor.(4) The clinical presentation of carcinoid tumor of the testis is usually of a painless testicular mass, most common in the left testis. Reported ages range from 10 to 83 years, with most patients in the fifth to seventh decades, which are older than those reported for primary germ cell tumors. The few studies which have reported the ultrasound features of a carcinoid tumor of the testis revealed cases similar to ours with a solid hypoechoic intratesticular mass, containing dense calcification. We describe a case of primary carcinoid tumor of the testis, discuss the ultrasound appearance, and briefly review the literature.

CASE REPORT

A 45-year-old Taiwanese man incidentally found a painless hard mass about 1-2 cm in dimen-

From the Division of Urology, Department of Surgery, [1]Department of Pathology, Chang Gung Memorial Hospital, Taipei; [2]Graduate Institute of Clinical Medicine, Chang Gung University, Taoyuan.
Received: Dec. 4, 2001; Accepted: Feb. 5, 2002
Address for reprints: Dr. Cheng-Keng Chuang, MD, PhD, Division of Urology, Department of Surgery, Chang Gung Memorial Hospital, Kweishan, Taoyuan 333, Taiwan, R.O.C. Tel.: 886-3-3281200 ext. 2103; Fax: 886-3-3285818; E-mail: chuang89@cgmh.org.tw

sion in his right testis. Scrotal ultrasound disclosed a heterogenous hypoechoic lesion with calcification (Fig. 1A). The epididymis had a normal contour. The left testis appeared normal. Laboratory data showed beta HCG of <3 (normal <5) mIU/ml, AFP of 3 (normal <20) ng/ml, and PSA of 0.09 (normal <4) ng/ml. Under the impression of testis tumor, a right radical orchiectomy was performed.

The tumor was a firm, yellowish-white, well-defined mass, measuring 1.4 ¡ 1.2 ¡ 0.8 cm. Cystic degeneration and focal calcification were also noted (Fig. 1B). The tunica albuginea and epididymis were free of tumor. The tumor cells showed argyrophia. Histopathology confirmed a carcinoid tumor with no teratomatous elements (Fig. 2A). In the immunohistochemical study, the tumor cells were strongly positive for keratins AE1 and AE3, neuron-specific enolase (NSE), chromogranin-A (Fig. 2B), and synaptophysin. Postoperative magnetic resonance imaging (MRI) studies of the chest, abdomen, and pelvic

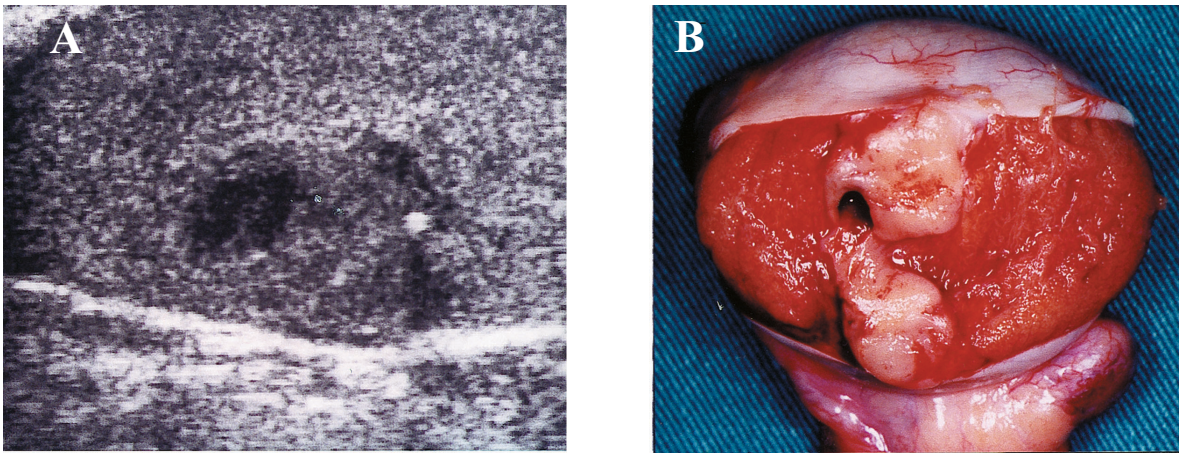

Fig. 1 (A) Ultrasound showing a heterogenous hypoechoic lesion with calcification. (B) Macroscopic appearance of the right testis, showing a yellowish-white, firm, well-defined tumor with cystic degeneration.

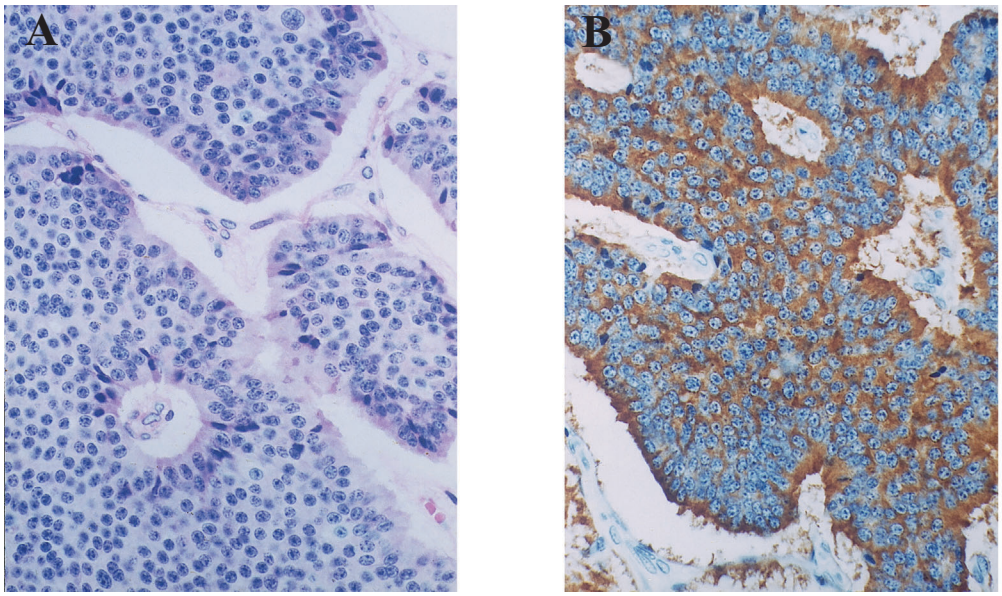

Fig. 2 (A) Photomicrograph of the testicular tumor showing solid islands and acini of cells which are separated by a fibrous stroma. The cells show eosinophilic cytoplasma and round nuclei with coarsely granular chromatin (H&E section, X200). (B) The tumor showing immunoreactivity for chromogranin-A (ABC method, ¡ 200).

regions were unremarkable. No further treatment was administered. The patient was alive and still under careful surveillance at this writing.

DISCUSSION

A carcinoid tumor of the testis is exceedingly rare, and may appear clinically as a primary or metastatic lesion. Most patients present in the fifth to seventh decades, and the left side is dominant.[5] The incidence of carcinoid tumor in the testis is about 0.23% of all testis tumors. Due to the lack of morphologic differences between primary and metastatic carcinoid tumors, it is necessary to exclude the presence of a primary tumor in another organ before confirming the diagnosis of a primary testicular carcinoid tumor. A painless mass and prominent testicular enlargement are the two most-common clinical findings.[5] Other symptoms include a painful testis, hydrocele, undescended testis, and carcinoid syndrome. Carcinoid syndrome (diarrhea, flushing, and bronchospasm) is quite rare; only 7 cases have been reported.[5] One possible reason is that the peptides secreted by the tumor are either in an inactive form or are rapidly metabolized, which results in the atypical clinical presentations.

Three types of testicular carcinoid tumors have been described, namely, primary testicular carcinoid, carcinoid metastasis to the testis, and carcinoid associated with teratoma.[7] A pure primary carcinoid testis tumor may originate from argentaffin or Kulchitsky's cells, which are located in the Lieberkuhn crypt.[7,8] Preoperative ultrasound evaluation may show a solid, hypochoic mass with a well-defined margin combined with calcification or a cyst. Differential diagnosis of the ultrasound appearance is testicular germ cell tumor, especially with teratoma, and embryonal cell carcinomas.[9,10] In seminoma, calcification is quite rare, and occurs only when the tumors are large and necrotic.[9] Benign testicular epidermoid tumors, however, demonstrate ultrasound features indistinguishable from a carcinoid tumor.[11] Intratesticular calcification can also be noted in tuberculous epididymo-orchitis and following trauma.[9] Radical orchiectomy as performed in our case remains the main treatment for carcinoid testicular tumor.[1] Grossly, the tumor presents as a solid mass, tan to white in color, and a cyst or calcification is sometimes noted. Light microscopy of the tumor reveals an eosinophilic granular cytoplasma, and a round to oval uniform nucleus. Immunohistochemical study shows that tumor cells are diffused, and reactive to antibodies to keratins AE1 and AE3, chromogranin-A, NSE, and synaptophysin.

Clinically, pure primary testicular carcinoid tumors have been treated as a benign lesion, while metastatic carcinoid tumors have a poor prognosis regardless of the primary site.[7] A carcinoid tumor is similar to a pheochromocytoma in that the malignant potential cannot be predicted by histological appearance. Testicular carcinoids rarely metastasize, with the overall incidence estimated at 11%.[6] A review of the literature showed that tumor size and the presence of carcinoid syndrome are features associated with a malignant course. Metastatic tumors were larger than those that were not (7.3 vs. 2.9 cm). Fifty percent of carcinoid tumors with metastasis had carcinoid syndrome, compared with only 3 of 51 cases of carcinoids without metastasis.[5] Although an exact preoperative diagnosis was not possible due to the lack of clinical or histological characteristics, the sonographic features of a testicular carcinoid may contribute to an early preoperative diagnosis. To rule out the possibility of a metastasis from an extra-testicular primary carcinoid, careful and thorough postoperative whole body surveys are important. Chest X-ray, chest CT (or MRI), abdominal and pelvic CT (or MRI), octreotide scintigraphy,[12] or a small bowel follow-through should be carried out to detect gastrointestinal tract or extra-intestinal primary or carcinoid metastasis. Octreotide scintigraphy is a recent imaging modality for carcinoid tumors. The octreotide binds to type 2 somatostatin receptors, which are expressed by most carcinoid cells. This investigation can identify about 2/3 of primary and metastatic carcinoid tumors. It may provide another tool for more adequately detecting carcinoid tumors.[12] A review of the literature suggests that metastatic potential exists for such tumors and regular follow up is indicated. It has been suggested to check urine 5-hydroxyindolacetic acid (5-HIAA), review the history, and perform a physical examination every 3 months for 1 year and then yearly thereafter.

REFERENCES

1. Grunshaw ND, Gopichandran TD. Case report: primary

carcinoid tumor of the testis-ultrasound appearances. Clin Radiol 1993;47:290-1.
2. Hee JK, Mee YC, Young NP, Jeong HK. Primary carcinoid tumor of the testis: immunohistochemical, ultrastructural and DNA flow cytometric study of two case. J Korean Med Sci 1999; 14:57-62.
3. Cope Z. Metastasis of an argentaffin carcinoma in the testicle. Br J Urol 1930;2:268-72.
4. Simon HB, McDonald JR, Clup DS. Argentaffin tumor (carcinoid) occurring in a benign cystic teratoma of the testicle. J Urol 1954;72:892-4.
5. Zavala-Pompa A, Ro JY, El-Naggar A, Ordonez NG, Amin MB, Pierce PD, Ayala AG. Primary carcinoid tumor of testis: immunohistochemical, ultrastructural, and DNA flow cytometric study of three cases with a review of the literature. Cancer 1993;72:1726-32.
6. Sutherland RS, Wettlaufer JN, Miller GJ. Primary carcinoid tumor of the testicle: a case report and management schema. J Urol 1992;148:880-2.
7. Terhune DW, Manson AL, Jordon GH, Peterson N, Auman JR, MacDonald GR. Pure primary testicular carcinoid: a case report and discussion. J Urol 1988;139:132-3.
8. Frank RG, Gerard PS, Anselmo MT, Bennett L, Preminger BI, Wise GJ. Primary carcinoid tumor of the testis. Urol Radiol 1991;12:203-5.
9. Martin B, Tubiana JM, Significance of scrotal calcification detected by sonography. J Clinic Ultrasound 1988; 16:545-52.
10. Grantham JC, Charboneau J, James EM, Kirschling RJ, Kvols LK, Segvra JW. Testicular neoplasms: 29 tumours studied by high resolution ultrasound. Radiology 1985;157:775-80.
11. Meiches MD, Nurenberg P. Sonographic appearance of a calcified simple epidermoid cyst of the testis. J Clinic Ultrasound. 1991;19:498-500.
12. Glazier DB, Murphy DP, Barnard MN, Cummings KB, Weiss RE. Primary carcinoid tumour of the testis. BJU international 1999;83:153-4.

原發性睪丸類癌瘤

張英勛　莊正鏗　吳俊德　吳桂芳　廖順奎

睪丸類癌瘤是相當少見的疾病。大部分類癌瘤發生在闌尾或迴盲腸，其餘可發生在肺、肝臟和泌尿生殖系統。原發性睪丸類癌瘤可源自argentaffin 或Kulchitsky細胞。手術前超音波可見到一實心、低回音且邊緣清楚的腫瘤，鑑別診斷包括畸胎瘤、胚胎細胞瘤、表皮樣瘤、結核病型副睪睪丸炎合併外傷。根治性睪丸切除仍然爲睪丸類癌瘤的主要治療方法。大體上，睪丸類癌瘤爲一茶褐色到白色實心腫瘤。在免疫組織化學染色上，睪丸類癌瘤對於Keratin AE1和AE3，chromogranin-A，neuron-specific enolase 和synaptophysin呈陽性反應。在治療上，原發性睪丸類癌瘤一般被當成良性病灶處理，若是轉移性睪丸類癌瘤則預後相當不好。爲了排除睪丸類癌瘤不是從其他地方轉移而來，因此手術後全身檢查是相當重要的。胸部X光，胸部、腹部和骨盆腔電腦斷層掃描，octreotide 閃爍攝影都可加以幫忙。我們提出一睪丸類癌瘤之病例報告，討論其超音波之表現，並回顧文獻之報導。(長庚醫誌 2002;25:695-9)

關鍵字：睪丸類癌瘤，睪丸腫瘤，超音波。

“ł' < ' ´ |¡@¥x¥_ | ˇ ¥< ‡¡ “c§¿<
¤ / /Ø·`¡G¥ˆ Œ 90ƒ~12/º4/Ø¡F¥ˆ Œ 91ƒ~2/º5/ØC
fl`¤œ' ƒL¥»‡B¡G†ł¥¿ˆ ´ fiv¡A“ł' < ' ´ | ¥< ‡¡ “c§¿< ¡Cfi ¶Ø¿/ 333 t/s¶m·_¿‡ 5 „C Tel.: (03)3281200´ 2103; Fax: (03)3285818; E-mail: chuang89@cgmh.org.tw