

## Contradiction of Clinical Expectations in Lymphoscintigraphy Sentinel Node Mapping in Detecting Microscopic Melanoma Metastasis

John WC Chang, MD; Hsui-Fong Chiang, RN; Yung-Feng Lo<sup>1</sup>, MD;  
Chien-Hsun Chen<sup>2</sup>, MD; Pan-Fu Kao<sup>3</sup>, MD, ScM

A 51-year-old man presented with lower back skin pigmentation tag that he had had for 2 years. Physical examination showed a 10 × 10 mm ulcerated, protruding pigmented skin mass at the midline of back at the 4th lumbar spine level. Skin biopsy disclosed a 5 mm thickness nodular melanoma, which had invaded the reticular dermis. In addition, a 20 × 20 mm lymph node in the right inguinal region was noted. A pelvic computed tomography scan revealed no definite evidence of lymph node enlargement in the left inguinal, bilateral iliac or para-aortic region. However, the <sup>99m</sup>Tc-sulfurcolloid dynamic lymphoscintigraphy revealed a sentinel lymph node (SLN) in the left inguinal area. The histological examination of the 4-mm SLN demonstrated a small cluster of metastatic melanoma, which was confirmed using HMB-45 immunohistochemical stain. Meanwhile, no melanoma cells were seen in the right enlarged inguinal lymph node. Subsequently, complete left inguinal lymph node dissection was performed, which confirmed that there was no melanoma metastasis in any of remaining 14 nodes. The patient underwent regular follow-up for 9 months and had no evidence of malignancy recurrence to date. (*Chang Gung Med J* 2002;25:474-9)

**Key words:** Sentinel lymph node, malignant melanoma, microscopic metastasis

Since the 1960s, much information has been accumulated regarding the lymphatic system, its dynamics and circulation. In 1955, Hultborn et al. performed one of the first demonstrations of lymphatic drainage, named lymphoscintigraphy, which is the drainage of the lymph from the breast to the supplying basins.<sup>(1)</sup>

In 1992, Morton et al. formulated the concept of sentinel lymph node (SLN). The concept is that during the spread of melanoma or breast cancer, the metastasis will proceed through the lymph system and deposit some cells in the first or sentinel lymph node.<sup>(2)</sup> Furthermore, the SLN is the node most like-

ly to receive metastatic cells from the primary tumor. During the 1990s, the development of an intraoperative probe has promoted a large quantity of work in the diagnosis and treatment of malignant melanoma based on SLN mapping.<sup>(2-5)</sup> However, it remains problematic for clinical practitioners to determine the direction of the lymphatic drainage when malignant melanoma is located at the midline of the trunk. Herein we present a case of malignant melanoma at midline of the back. The lymphoscintigraphy demonstrated the SLN in the left inguinal area, which is an unexpected contradiction to the clinically suggested palpable right inguinal node. The SLN

---

From the Division of Hematology-Oncology, Department of Internal Medicine; <sup>1</sup>First Division of General Surgery, Department of Surgery; <sup>2</sup>Department of Dermatology, <sup>3</sup>Department of Nuclear Medicine; Chang Gung Memorial Hospital, Taipei.

Received: Jul. 26, 2001; Accepted: Nov. 23, 2001

Address for reprints: Dr. Pan-Fu Kao, Department of Nuclear Medicine, Chang Gung Memorial Hospital, 5 Fu-Shin Street, Kweishan, Taoyuan, Taiwan, R.O.C. Tel.: 886-3-3281200 ext. 2622; Fax: 03-3281320; E-mail: kaopanfu@cgmh.org.tw

histological examination demonstrated nodal microscopic metastasis which resulted in upstaging of the disease.

## CASE REPORT

A 51-year-old man had a lower back skin pigmentation tag for 2 years. Physical examination showed a 10 × 10 mm ulcerated, protruding pigmented skin mass at the midline of back at the 4th lumbar spine level. On October 26, 2000, a skin biopsy disclosed a 5 mm thick nodular melanoma, which had invaded the reticular dermis. The patient underwent a wide excision surgery to remove the melanoma. The pathological examination showed clear margins of the specimen.

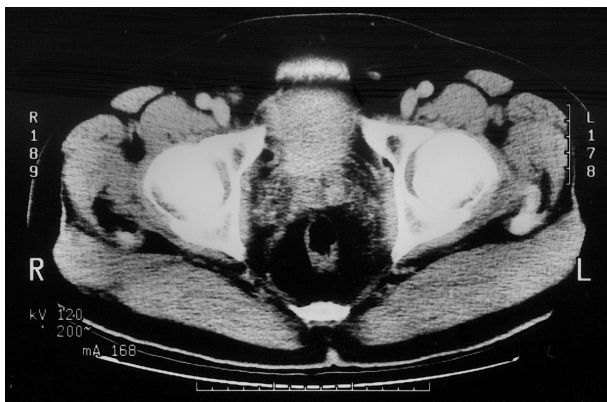
The patient was referred to the Department of Medical Oncology 2 weeks after surgery. During admission, a 20 × 20-mm palpable lymph node at the right inguinal region was discovered. Notably, there was no other skin lesion, hepatomegaly or neurological sign. Contrast-enhanced CT scan of the pelvis (Fig. 1) revealed that although a 20 × 20-mm lymphadenopathy was present in the right inguinal area medial to the femoral vein, the lymph nodes in left inguinal, bilateral iliac and para-aortic regions remained normal.

A lymphoscintigraphy SLN mapping was performed following two subdermal injections, about 0.5 mCi in 0.25 ml for each injection, of <sup>99m</sup>Tc-sulfur-

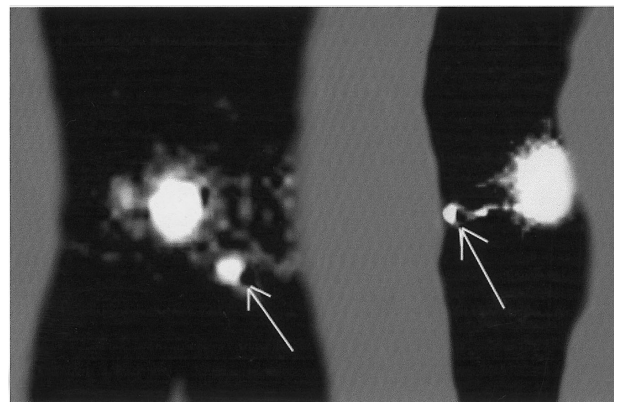
colloid at the upper and lower aspect of the lower back excision site. Fifteen minutes after the radiotracer injection, the dynamic lymphoscintigraphy revealed smooth drainage of the radiotracer anteriorly to the left with visualization of a SLN in the left inguinal area (Fig. 2). The radiotracer did not drain or accumulate in the right inguinal region. Surprisingly, the SLN occurred in the left inguinal region rather than the right enlarged lymph node, which contradicted the initial impression.

Four hours after the lymphoscintigraphy, a hand-held gamma probe system (Navigator GPS, Norwalk Conn, USA) was employed to detect the SLN. A 4 × 4 mm radioactive lymph node, measured at approximately 5000 counts/minute by gamma probe, was discovered and labeled as SLN. The SLN was removed surgically and was subjected to histological examination. Serial sections of the SLN revealed a small nest of melanoma microscopic metastases, which was positive with HMB-45 immunohistochemical stained (Fig. 3). Subsequently, complete left inguinal lymph node basin dissection was performed, which showed no melanoma metastasis in any of the other remaining 14 lymph nodes. To confirm these findings and to rule out the possibility of melanoma metastasis, the enlarged right inguinal lymph node was also dissected. The histological examination did not present melanoma metastasis.

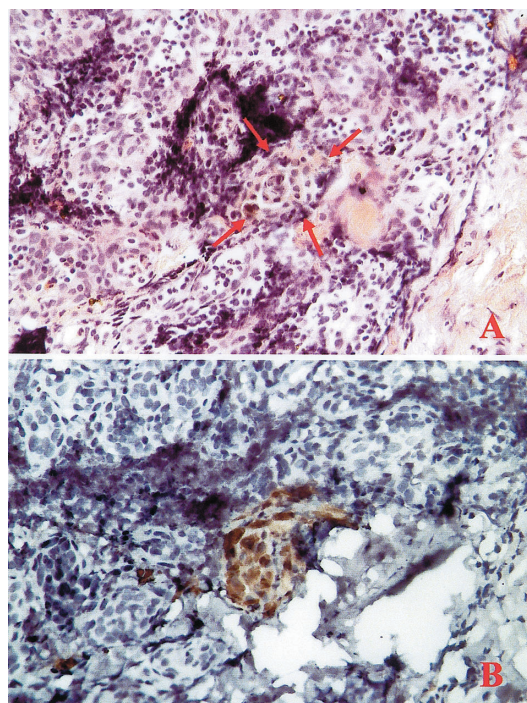
A CT scan that was performed 4 months after



**Fig. 1** Contrast-enhanced CT indicates a 20 × 20 mm lymphadenopathy at the right inguinal area medial to the femoral vein. There was no enlargement of the lymph nodes at the left inguinal, bilateral iliac or para-aortic regions.



**Fig. 2** The (A) anterior and (B) left lateral views of the dynamic lymphoscintigraphy SLN mapping revealed smooth drainage of the radiotracer to the left inguinal area.



**Fig. 3** The high power view (400 $\times$ ) of SLN histological examination with (A) H & E stain and (B) by HMB-45 immunohistochemical stain demonstrated a small nest of melanoma microscopic metastasis.

surgery and disclosed no evidence of tumor recurrence in the pelvic region. The  $^{18}\text{F}$ -fluorodeoxyglucose (FDG) whole body positron emission tomography (PET) scan revealed no abnormal FDG uptake. The patient had regular periodic examinations for 9 months without definite evidence of malignancy recurrence.

## DISCUSSION

For patients with solid neoplasm, the most essential prognostic factor is the metastatic status of the regional lymph nodes, which drain the primary tumor. Sappey was the first to describe the anatomy of the regional lymphatic drainage comprehensively.<sup>(6)</sup> He reported a ventral and dorsal trunk vertical midline zone where lymphatic drainage tended to overlap from both the left and right sides of the body. A similar zone was identified to exist horizontally around the waist, which passes from the umbilicus to

the second lumbar vertebra dorsally; that is known as Sappeys zones.<sup>(6)</sup> Haagensen et al. extended the ambiguous lymphatic drainage zone to a 5-cm band down the midline and around the waist.<sup>(7)</sup> In our case, the melanoma at the midline 4th lumbar spine level was in the ambiguous zone of lymphatic drainage. Therefore, determining lymphatic drainage was paramount for lymphatic dissection and subsequent melanoma metastasis diagnosis. In 1978, Fee et al. confirmed that lymphoscintigraphy accurately predicted the node fields that potentially contained metastatic melanoma.<sup>(8)</sup> Increasing studies began to appear, which recommended expanding the zone of uncertainty around Sappeys zones.<sup>(9)</sup> It also became more apparent that lymphatic drainage could occasionally be identified in lymph nodes that were not previously considered potential metastatic sites on clinical grounds.<sup>(10)</sup> In this case, the clinically palpable right inguinal lymph node was first considered as a metastatic lymph node. Results of SLN mapping and dissection histological examination eventually contradicted the clinical suggestions. That is, a normal sized SLN at the left inguinal area was finally revealed as the only lymph node of melanoma microscopic metastasis.

During the 1990s, Morton et al. developed concepts and sensitive techniques with which to detect SLNs.<sup>(2,8,11)</sup> They reported that the SLN identification rate increased from 81% to 100% with increased exposure to the technique. Furthermore, they recommended that at least a minimum of 30 intraoperative gamma probe SLN mapping practices were required to master the technique.<sup>(12)</sup> In a case of negative SLN sampling, the probability was estimated to be 0-3% metastasis to lymph nodes other than the SLN.<sup>(13,14)</sup> In patients with early-stage melanoma, SLN mapping has detected the most cases of microscopic metastases to regional lymph nodes. Complete lymph node dissection and conventional elective lymph node dissection follow this.<sup>(13,14)</sup>

In the present case, the nodal metastasis would have been overlooked if SLN mapping, followed by immunohistochemical stain, had not been performed. Based on the SLN findings, a complete left but not right inguinal lymph node dissection was performed. Restated, SLN mapping finally proved that within the nodal basin the left node was the only one that a small cluster of melanoma cells had invaded. Delaying therapy may have deprived this patient the



best chance of a cure. Therefore, accurate SLN mapping helps avoid unnecessary inguinal lymph node dissection.

Notably, if lymphatic mapping had not proved the regional node metastasis, lymph node dissection would not have been performed. In patients with negative regional nodal metastasis, Breslow thickness was the standard that determined whether elective lymph node dissection (ELND) would be performed or not. With the advent of lymphatic mapping, Breslow thickness is now considered obsolete.<sup>(15)</sup> In view of the right lymphadenopathy, which physical examination discovered, the clinical staging was N1. Thus, a therapeutic right inguinal lymph node dissection would have been performed.

The histopathological evaluation of the SLN for melanoma was based on results of H&E stain and HMB-45 immunohistochemical stain. HMB-45 is a specific marker for melanoma cells (Fig 3). With the advent of reverse transcriptase polymerase chain reaction (RT-PCR), examining lymph node for the presence of tyrosinase mRNA can detect submicroscopic melanoma metastases.<sup>(16)</sup> Good sensitivity of the RT-PCR assay on archival tissues was demonstrated following a comparison of RT-PCR results on frozen and paraffin-embedded SLNs from 16 melanoma patients.<sup>(17)</sup> However, this molecular approach is still under investigation.

In conclusion, with the detection of microscopic metastasis in SLN, the treatment of melanoma has improved. In particular, the dynamic lymphoscintigraphy for SLN mapping is paramount in determining the direction of lymph flow for patients with body midline melanoma. However, subsequent studies of the clinical significance of microscopic metastasis in Asian patients with malignant melanoma are required.

## REFERENCES

1. Hultborn KA, Larsson LG, Ragnhult I. The lymph drainage from the breast to the axillary and parasternal lymph node: studies with the help of Au-198. *Acta Radiol* 1955;43:52-64.
2. Morton D, Wen D, Wong J, Economou J, Cagle L, Storm F, Foshag L, Cochran A. Technical details of intraoperative lymphatic mapping for early stage melanoma. *Arch Surg-Chicago* 1992;127:392-9.
3. Albertini JJ, Cruse C, Wells K, Berman C, Fenske N, Schroer K, Heller R, Ross M, Lyman G, Cox C, Rapaport D, Seigler H, Balch C. The orderly progression of melanoma nodal metastases. *Ann Surg* 1994;759-67.
4. Leong S, Steinmetz I, Habib F, McMillan A, Gans J, Allen R J, Morita E, el-Kadi M, Epstein H, Kashani-Sabet M, Sagebiel R. Optimal selective sentinel lymph node dissection in primary malignant melanoma. *Arch Surg-Chicago* 1997;132:666-73.
5. Cascinelli N, Morabito A, Santinami M, MacKie R, Belli F. Immediate or delayed dissection of regional nodes in patients with melanoma of the trunk: a randomised trial. WHO Melanoma Programme. *Lancet* 1998;351:793-6.
6. Uren RF, Thompson JF, Howman-Giles R. The history of lymphatic mapping. In: Nieweg OE, Essner R, Reintgen DS, and Thompson JF eds. *Lymphatic Mapping and Probe Applications in Oncology*. New York: Marcel Dekker, Inc. 2000:24.
7. Haagensen C, Feind C, Herter F, Slanetz Jr C, Weinberg J. Lymphatics of the trunk. In: CD Haagensen, ed, *The lymphatics in cancer*. Philadelphia: WB Saunders 1972;437-458.
8. Fee H, Robinson D, Sample W, Graham L, Holmes E, Morton D. The determination of lymph shed by colloidal gold scanning in patients with malignant melanoma: a preliminary study. *Surgery* 1978;84:626-32.
9. Uren RF, Thompson JF, Howman-Giles R. The history of lymphatic mapping. In: Nieweg OE, Essner R, Reintgen DS, and Thompson JF eds. *Lymphatic Mapping and Probe Applications in Oncology*. New York: Marcel Dekker, Inc. 2000:25.
10. Uren RF, Thompson JF, Howman-Giles R. The history of lymphatic mapping. In: Nieweg OE, Essner R, Reintgen DS, Thompson JF eds. *Lymphatic Mapping and Probe Applications in Oncology*. New York: Marcel Dekker, Inc. 2000:28.
11. Wong J, Cagle L, Morton D. Lymphatic drainage of skin to a sentinel lymph node in a feline model. *Ann Surg* 1991;214:637-41.
12. Lotze MT, Dallal RM, Kirkwood JM, Flickinger JC. Cutaneous Melanoma. In: DeVita, Vincent T, Hellman, Samuel, Rosenberg, Steven A. *Cancer: Principles and Practice of Oncology*. 6th ed. Volume 2. Philadelphia: Lippincott Williams and Wilkins, 2001:2037.
13. Essner R, Conforti A, Kelley M, Wanek L, Stem S, Glass E, Morton D. Efficacy of selective lymphadenectomy as a therapeutic procedure for early-stage melanoma. *Ann Surg Oncol* 1999;6:442-9.
14. Cochran A, Wen D, Morton D. Management of the regional lymph nodes in patients with cutaneous malignant melanoma. *World J Surg* 1992;16:214-21.
15. Lotze MT, Dallal RM, Kirkwood JM, Flickinger JC. Cutaneous melanoma, In: DeVita, Vincent T, Hellman, Samuel, Rosenberg, Steven A. *Cancer: Principles and Practice of Oncology*. 6th ed. Volume 2. Philadelphia: Lippincott Williams and Wilkins, 2001:2032.

16. Wang X, Heller R, VanVoorhis N, Cruse C, Glass F, Fenske N, Berman C, Leo-Messina J, Rappaport D, Wells K. Detection of submicroscopic lymph node metastases with polymerase chain reaction in patients with malignant melanoma. *Ann Surg* 1994;220:768-74.
17. Palmieri G, Ascierto PA, Cossu A, Mozzillo N, Motti ML, Satriano SMR, Botti G, Caraco C, Celentano E, Satriano RA, Lissia A, Tanda F, Pirastu M, Castello G. Detection of occult melanoma cells in paraffin-embedded histologically negative sentinel lymph nodes using a reverse transcriptase polymerase chain reaction assay. *J Clin Oncol* 2001;19:1437-43.

# 淋巴閃爍攝影偵測與臨床上預期不同的前哨淋巴結 顯微黑色素細胞瘤轉移

張文震 江雪芳 羅永豐<sup>1</sup> 陳建勳<sup>2</sup> 高潘福<sup>3</sup>

一位51歲男性於背部皮膚第4腰椎身體中線處長一個10×10 mm的結節型黑色素細胞瘤，深度5 mm侵犯至皮膚下層；理學檢查時發現右側腹股溝有一個20×20 mm的淋巴結，骨盆腔電腦斷層檢查並未發現左側腹股溝、兩側腸骨或主動脈旁有淋巴結腫大。淋巴閃爍攝影發現有一個前哨淋巴結在左側腹股溝部位，組織學檢查發現此4 mm前哨站淋巴結有一小群腫瘤細胞，並經由HMB-45免疫組織染色證實為黑色素細胞瘤。而原先右側觸診發現的淋巴結卻沒有被腫瘤細胞侵犯。這位病患隨後接受左側腹股溝淋巴結廓清術，所清除的其餘14顆小淋巴結中未再發現任何腫瘤細胞轉移現象。經過9個月的追蹤此病人目前尚無復發跡象。(長庚醫誌 2002;25:474-9)

**關鍵字：**前哨淋巴結，黑色素細胞瘤，顯微轉移。