

## Isolated Sphenoid Sinus Aspergillosis: Report of Two Cases

Ta-Jen Lee, MD; Shiang-Fu Huang, MD; Chi-Che Huang, MD; Ying-Lin Chen, MD

*Aspergillus* fungus can be found worldwide and is the most common fungal infection of the paranasal sinuses. Despite this ubiquity, aspergillosis of the sphenoid sinus as an isolated disease in an otherwise healthy person is quite rare. We report two cases in this article: one was a 53-year-old woman who suffered from bloody postnasal drip for 2 weeks and the other a 61-year-old woman suffered from facial swelling for 2 months. Central dense areas, which are characteristic for *Aspergillus* sinus infection, were found on their computer tomographs. Both patients were managed by functional endoscopic sinus surgery without recurrence within the 6-month follow-up period. A survey of the reports in the literature indicated that the occurrence of isolated sphenoid sinus aspergillosis was predominantly in elderly females. Hormone changes which occur during this age might play a role in the pathogenesis of fungal infection. Treatment with an anti-fungal agent was not suggested for non-invasive aspergillosis. Instead, surgery played a major role in the treatment. (*Chang Gung Med J* 2002;25:464-8)

**Key words:** sphenoid sinus, aspergillosis.

The *Aspergillus* fungus of the Aschomycetes class is widespread in nature. *Aspergillus* spores are common contaminants of the respiratory tract, making it the most common fungal infection of the paranasal sinuses.<sup>(1)</sup> Aspergillosis of the sphenoid sinus as an isolated disease in an otherwise healthy person is rare. In 1977, Miglets and Saunders reported two cases of sphenoid sinus aspergillosis.<sup>(2)</sup> They noted that only four reports of isolated sphenoid sinusitis were known prior to 1977; among those four, three proved fatal. Due to the intimate anatomical relationship between the central nervous system and the ocular organs, isolated sphenoid sinus aspergillosis usually manifests as severe symptoms such as blurred vision, ptosis or meningitis. We recently treated two patients with isolated aspergillosis of the sphenoid sinus that were managed endoscopically with positive outcomes.

### CASE REPORTS

#### Case 1

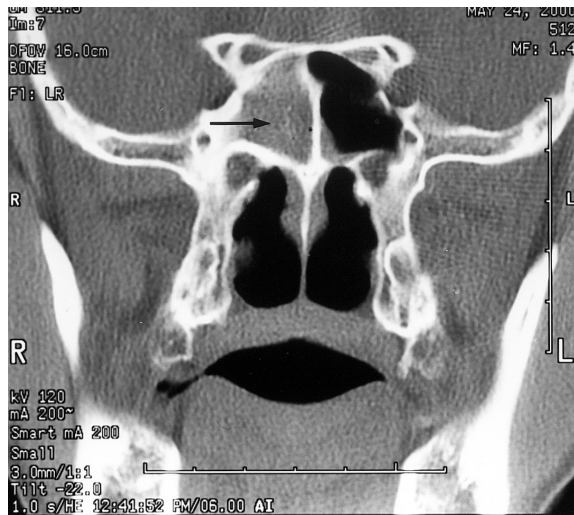
A 53-year-old woman visited our ear, nose and throat clinic principally complaining of bloody postnasal drip which had persisted for 2 weeks. Her symptoms were more evident in the morning. A sensation of fullness in the right ear was also present. She had no history of fever, chills, recent upper respiratory tract infection or mechanical injury to her nose or sinuses. Physical examination of the ear, nose, and throat showed negative findings. No purulent rhinorrhea, polyps nor underlying systemic disease was noted.

A computer tomography (CT) scan performed under the impression of nasopharyngeal carcinoma or sinus disease revealed a soft tissue density containing calcification in the right sphenoid sinus (Fig. 1), and isolated sphenoid sinusitis caused by

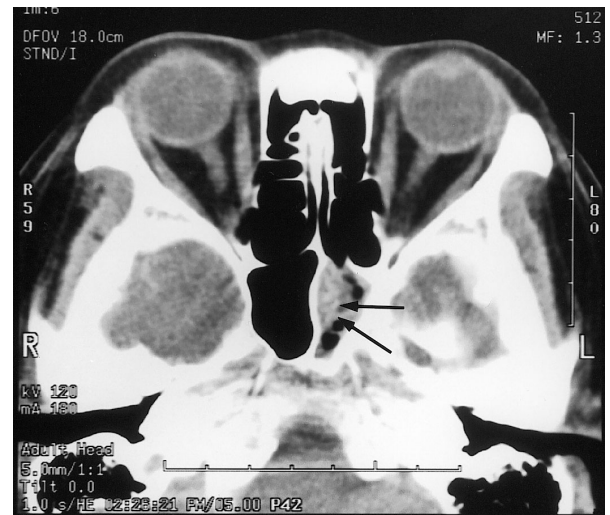From the Department of Otolaryngology, Chang Gung Memorial Hospital, Taipei; Chang Gung University, Taoyuan.

Received: Jun. 7, 2001; Accepted: Dec. 3, 2001

Address for reprints: Dr. Ta-Jen Lee, Department of Otolaryngology, Chang Gung Memorial Hospital, 5 Fu-Shin Street, Kweishan, Taoyuan 333, Taiwan, R.O.C. Tel.: 886-3-3281200 ext. 3967; Fax: 886-3-3979361; E-mail: bigmac@cgmh.org.tw



**Fig. 1** Coronal CT scan, in case 1, reveals complete opacification of the right sphenoid sinus. Extremely high dense particles are observed within the sinus (arrow).



**Fig. 2** Axial CT scan, in case 2, reveals opacification of the left sphenoid sinus. Dense particles within sinus are also observed (arrows).

fungal infection. Laboratory test results revealed blood glucose of 5.16 mmol/L (fasting) and anti-human immunodeficiency virus antibody test were negative.

We arranged functional endoscopic sinus surgery for this patient. We first resected the inferior third of the middle turbinate. The anterior sphenoid sinus wall was sclerotic, and consequently a posterior ethmoidotomy was performed. Through posterior ethmoidotomy, the natural ostium of the sphenoid sinus was entered. Brownish cheesy materials were found in the antrum. The materials were removed with forceps followed by warm saline irrigation and sent for pathologic examination. The sphenoidotomy was extended with curret and back-bite forceps. The wound was packed with Surgicels and Kaltostat®. The packings were removed the next day, and the patient was subsequently discharged.

Histological sections from the specimens demonstrated fungal hyphae. Oral antibiotics (amoxicillin 1 g/day) were administered to prevent bacterial infection for 2 weeks, combined with local nasal treatment. No recurrence took place during the 6-month follow-up period.

## Case 2

A 61-year-old woman visited our clinic report-

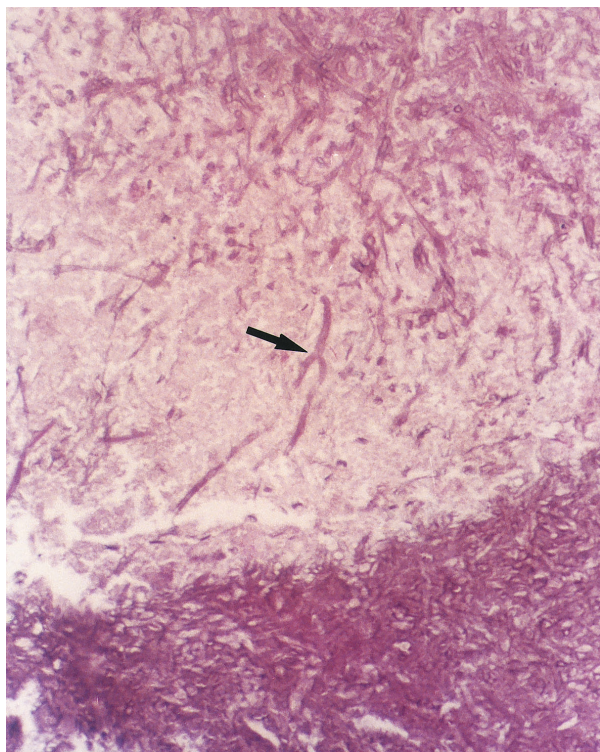
ing facial pain on the left side and occipital headaches for 2 months. Purulent rhinorrhea was also found. There was no history of sinus operations or trauma. Physical examination of the ear, nose, and throat only revealed mucopus in the left nasal cavity, and no underlying systemic disease was noted.

A sinus CT was performed which showed soft tissue density with calcification in the left sphenoid sinus (Fig. 2). Isolated sphenoid sinusitis was diagnosed clinically.

We arranged functional endoscopic sinus surgery for her. After resecting the inferior one-third of the middle turbinate, the natural ostium of the sphenoid sinus was accessed. Brownish cheesy materials were found in the sphenoid sinus. The materials were removed, irrigated, and sent for pathologic examination. The sphenoidotomy was extended with curret and back-bite forceps. The wound was packed with Surgicels and Kaltostat®. The packings were removed the next day.

Histological sections from the specimens demonstrated fungal hyphae. Typical septate hyphae with acute angulation were confirmatory for aspergillosis (Fig. 3).

No antifungal agent was used either orally or intravenously. Oral antibiotics (amoxicillin 1 g/day) were administered to prevent bacterial infection for 2



**Fig. 3** Histological examination demonstrates septate hyphae with dichotomous branching (arrow), an indication of *Aspergillus* infection (haematoxylin and eosin stain;  $\times 400$ ).

weeks along with local nasal treatment. No recurrence took place during the 6-month follow-up period.

## DISCUSSION

Aspergillosis is the most common fungal infection of the paranasal sinuses. The first clinical report of sinus mycosis was reported by Hernu and Plaingaud in 1791.<sup>(3)</sup> Arnico first described aspergillosis of the maxillary sinus in 1890.<sup>(4)</sup> The pathogenesis of a fungal infection of the paranasal sinuses is unclear, although, in general, mycotic spores are inhaled and most commonly seeded to the ethmoid and maxillary sinuses. Some authors indicated that the fungi became pathogenic under anaerobic conditions when the affected sinus ostium was occluded.<sup>(5)</sup>

After reviewing the available reports in the

English literature, we found elderly women were the most common victims of isolated sphenoid aspergillosis. Lavelle et al.<sup>(6)</sup> presented a 60-year-old woman with isolated left sphenoid aspergillosis. Miglets<sup>(2)</sup> presented two patients, one 69-year-old man and the other a 57-year-old woman. Yiotakis et al.<sup>(7)</sup> presented four patients, and all of them were elderly women (45, 43, 55 and 77 years old, respectively). Both patients reported in this article were elderly women (50 and 61 years old, respectively). None of these patients were immunocompromised. After reviewing the medical histories of our patients, we found both were postmenopausal without regular hormone supplementation. Since endocrine changes may have certain effects on nasal mucosa, although not definitely clarified in the literature, we speculated that the predilection of an *Aspergillus* infection of the sinus in these patients might be a result of hormone changes due to aging.

As previously reported, isolated sphenoid sinus inflammatory diseases most frequently manifest as headaches (from 50% to up to 98%) and a retro-orbital pain.<sup>(8)</sup> In these patients, the predominant symptoms were quite diverse including blood-tinged sputum, facial pain, and headaches. Alertness of physicians in clinical practice is of the essence for efficient diagnosis and treatment of such sphenoid lesions.

On the CT scans of both patients, central dense areas were detected within the sphenoid sinus. These are usually found in aspergillosis of the paranasal sinuses and are due to calcium phosphate and, to a lesser degree, calcium sulphate accumulation in necrotic areas, towards the center of the fungal mass.<sup>(9,10)</sup> This sign is almost pathognomic for *Aspergillus* sinus infections. The use of magnetic resonance imaging was suggested by Lawson et al.<sup>(8)</sup> and Mukherji et al.<sup>(11)</sup> as an adjunct for differential diagnosis of sphenoid sinus fungal infection, as well as granulomatous and chronic invasive fungal sinusitis. In our experience, fungal infection caused by *Aspergillus* should first be considered when detecting this sign on CT scans.

For isolated sphenoid sinusitis, functional endoscopic sinus surgery has become the most commonly performed procedure, and it has been proven effective. In most cases, a sphenoidotomy was done after resection of the inferior third of the middle turbinate.

However in some, the anterior walls of the sphenoid sinuses were sclerotic on CT scans, and markedly thickened intraoperatively. Consequently, the trans-posterior ethmoid approach would be a feasible alternative when sphenoidotomy is difficult.<sup>(12,13)</sup>

Fungal sinusitis has been classified into invasive and noninvasive forms. The noninvasive form has further been divided into aspergilloma and allergic fungal sinusitis.<sup>(7)</sup> The cases presented here are examples of aspergilloma. For aspergilloma, as experienced in these two patients, treatment with endoscopic sphenoidotomy and the establishment of adequate sinus drainage were sufficient. No residual disease or symptoms reappeared during the 6-month follow-up period. No post-operative antifungal agents were used. Systemic antifungal agents are only recommended when there are signs of invasion, such as mucosal involvement, extension to posterior ethmoidal cells, and involvement of orbit and meninges.

## REFERENCES

1. Mc Guirt WF, Harril JA. Paranasal sinus aspergillosis. *Laryngoscope* 1979;89:1563-68.
2. Miglets AW, Saunders WH, Ayers L. Aspergillosis of the sphenoid sinus. *Arch Otolaryngol* 1978;104:47-50.
3. Adams NS. Infections involving the ethmoid and maxillary and sphenoid sinuses in the orbit due to *Aspergillus fumigatus*. *Arch Surg* 1933;26:999-1009.
4. Zarnico C. Aspergillus Mykose der Kieferhöhle. *Dtsch Med Wechr* 1891;17:1222.
5. Milosev B, El-Mahgoub S, Aal OA, El-Hassan AM. Primary aspergilloma of paranasal sinuses in the Sudan. *Br J Surg* 1969;56:132-7.
6. Lavelle WG. Aspergillosis of the sphenoid sinus: case report. *Ear Nose Throat J* 1988;67:266-9.
7. Yiotakis I, Psarommatis I, Seggas I, Manolopoulos L, Ferekidis E, Adamopoulos G. Isolated sphenoid sinus aspergillomas. *Rhinology* 1997;35:136-9.
8. Lawson W, Reino AK. Isolated sphenoid sinus disease: an analysis of 132 cases. *Laryngoscope* 1997;107:1590-5.
9. Stammberger H, Jakse R, Beaufort F. Aspergillosis of the paranasal sinuses. X-ray diagnosis, histopathology and clinical aspects. *Ann Otol Rhinol Laryngol* 1984;93:251-6.
10. Saeed S, Brookes G. Aspergillosis of the paranasal sinuses. *Rhinology* 1995;33:46-51.
11. Mukherji SK, Figueroa RE, Ginsberg LE, Zeifer BA, Marple BF, Alley JG, Cooper LL, Nemzek WR, Yousem DM, Jones KR, Kupferberg SB, Castillo M. Allergic fungal sinusitis: CT findings. *Radiology* 1998;207:417-22.
12. Gilain L, Aidan D, Coste A, Peynegre R. Functional endoscopic sinus surgery for isolated sphenoid sinus disease. *Head Neck* 1994;16:433-7.
13. Turgut S, Özcan KM, Çelikkanat S, Özdem C. Isolated sphenoid sinusitis. *Rhinology* 1997;35:132-5.



## 單獨性蝶竇麴菌症：二例報告

李達人 黃祥富 黃啓哲 陳盈霖

麴菌廣佈於環境中，且是副鼻竇黴菌感染中最常見之致病原。雖然如此，單獨性蝶竇麴菌症於健康人身上發生的機會相當罕見。本文提出兩病患：一為53歲女性病患，因鼻涕倒流中帶血2週至門診求診；另一為61歲女性病患因左側臉腫有2個月至門診求診。於電腦斷層攝影上，可見中央高密度區，此被視為副鼻竇麴菌症感染的特徵。本文中兩例皆以鼻竇功能內視鏡手術處理，追蹤6個月皆無復發。回顧文獻，單獨性蝶竇麴菌症有好發於中老年女性病患之傾向，對此，吾人認為中老年齡婦女體內的荷爾蒙改變與此應有相關。於非侵犯型麴菌症中，抗黴菌藥物並不建議常規使用，手術治療扮演較重要之角色。(長庚醫誌 2002;25:464-8)

**關鍵字：**蝶竇，麴菌症。