

## Needling Revision with Subconjunctival 5-Fluorouracil in Failing Filtering Blebs

Shirley Hsueh-Li Chang, MD; Chiun-Ho Hou, MD

**Background:** 5-Fluorouracil, an antimetabolic agent, improves the success rate of trabeculectomies by inhibiting subconjunctival fibrosis. However, complications may be associated with early postoperative use. We investigated the outcome of needling revision with delayed subconjunctival 5-fluorouracil in failing filtering blebs after a trabeculectomy in patients with medically poorly controlled glaucoma.

**Methods:** We performed needling revision with subconjunctival 5-fluorouracil injection 5.0; 4.0 weeks after trabeculectomy with failing filtering blebs in 25 eyes of 24 patients. The diagnoses of these patients were primary angle-closure glaucoma (4), primary open-angle glaucoma (4), post-cornea-graft glaucoma (8), traumatic glaucoma (5), neovascular glaucoma (3) and pseudophakic glaucoma (1).

**Results:** Total success was achieved in 21 eyes (84%) including complete success in 10 (40%) and qualified success in 11 (44%) after 3.2; 1.2 needling revisions over an average 8.3; 7.0-month follow-up period from the last needling revision. The mean intraocular pressure was 16.0; 8.4 mmHg in the last visit compared with 26.0; 8.1 mmHg before the procedure. Major complications were transient hypotony (1), transient corneal epithelial defect (13) and hyphema (3).

**Conclusions:** This study supports the efficacy and safety of the delayed use of 5-fluorouracil with needling revision for managing failing filtering blebs following a trabeculectomy.

*(Chang Gung Med J 2002;25:97-103)*

**Key words:** fluorouracil, glaucoma, trabeculectomy, needling revision.

Since Gressel, et al. introduced 5-fluorouracil (5-FU) to glaucoma filtration surgery in an animal model and in humans in 1984,<sup>(1)</sup> many studies have proven the efficacy of subconjunctival injection of this drug in improving intraocular pressure control after filtration surgery.<sup>(2)</sup> However, the Fluorouracil Filtering Surgery Study Group (FFSSG) reported such complications such as conjunctival wound leak-

age, corneal epithelial defect, shallow anterior chamber, and hypotony.<sup>(3-5)</sup> Instead of a routine early postoperative 5-FU injection, the efficacy of a delayed injection until the filtering bleb failed or when failure was impending also proven.<sup>(6-11)</sup>

We investigated the effectiveness and complications of a subconjunctival injection of 5-FU in failing filtering blebs combined with needling revision.

---

From the Department of Ophthalmology, Chang Gung Memorial Hospital, Taipei.

Received: Jun. 28, 2001; Accepted: Sep. 20, 2001

Address for reprints: Dr. Shirley Hsueh-Li Chang; Department of Ophthalmology, Chang Gung Memorial Hospital, 5 Fu-Shin Street, Kweishan, Taoyuan 333, Taiwan, R.O.C. Tel.: 886-3-3281200 ext. 8666; Fax: 886-3-3287798; E-mail: hlchang@cgmh.org.tw

We also analyzed the contributing risk factors associated with successful outcome.

## METHODS

### Patient selection

We performed needling revision with subconjunctival 5-FU injections in 25 eyes of 24 patients (12 male and 13 female eyes) from October 1997 to April 2000. The mean age of these patients was 53.0  $\pm$  13.2 years, ranged from 31 to 72 years. The subtypes of glaucoma were primary angle-closure glaucoma in 4 eyes, primary open-angle glaucoma in 4, post-cornea-graft glaucoma in 8, traumatic glaucoma in 5, neovascular glaucoma in 3, and pseudophakic glaucoma in 1. Intraocular pressure was controlled medically with 2.52  $\pm$  0.82 kinds of medications before filtering surgery. Six eyes were phakic, 7 were aphakic, and the other 12 eyes were pseudophakic with posterior chamber intraocular lens.

These patients received a trabeculectomy (23 eyes) or a trabeculectomy combined with extracapsular cataract extraction and intraocular lens implantation (2 eyes) by the same surgeon. Intraoperative soaking with mitomycin C was applied in 11 of the 25 eyes. The scleral flap was sutured conventionally with 10-0 nylon in these 11 cases and adjustably with 9-0 nylon in the others without mitomycin C. They were followed up in our clinic from the day after the surgery, weekly for 4 visits and then monthly. Intraocular pressure was measured by pneumatic tonometry, Perkins applanation tonometry, electronic Tonopen, or Schiøtz tonometry according to the corneal condition of the patient. We needled the blebs with a subconjunctival 5-FU injection when a failing bleb was noted, which was defined as an intraocular pressure greater than 21 mmHg, combined with the appearance of vascularization or flattening of the blebs upon slit lamp examination. The duration between 5-FU needling revision and filtering surgery was 5.0  $\pm$  4.0 weeks, and ranged from 2 to 19 weeks.

### Technique of bleb needling

After instillation of several drops of 0.4% Novesin solution and preparation of the eyelid using a sterile lid speculum under an operating microscope, we introduced a 30-gauge needle attached to a 1-ml

syringe containing 0.2 ml of 2% xylocaine into the bleb about 10 mm away and 90° to the sclerotomy site. The 2% xylocaine was injected to the subconjunctival space for anesthesia. We then swept the needle back and forth in the subconjunctival space to dissect the fibrotic band. When the eyeball was softened and the bleb was diffused in appearance, we withdrew the needle and introduced another 30-gauge needle attached to another 1-ml syringe containing 5 mg 5-FU in 0.5 ml of distilled water through the same puncture site. With the bevel of the needle facing away from the scleral flap and the cotton applicator pressed on the flap, 5-FU was injected into the bleb. Care was taken not to make a buttonhole in the conjunctiva, while completing the above procedure with an aseptic technique. We applied gentamycin ophthalmic ointment and pressure-patched the eye with gauze after the procedure until the next day.

Patients were checked weekly and then monthly in the clinic according to the intraocular pressure (IOP) level, the appearance of the bleb, and the coexistence of the complications. If a failing filter bleb was noted or if the IOP was not being properly controlled during the follow-up, another 5-FU needling revision was given.

We defined complete success as an IOP level of less than 21 mmHg without medication and qualified success as an IOP level of less than 21 mmHg with medication. The total success group included both complete and qualified success groups. Failure was defined as an IOP greater than 21 mmHg for which additional surgery was required for IOP control. During the follow-up period, if transient elevation of the intraocular pressure was noted and then the pressure returned to within the normal limit with or without medication at a later visit, we still considered the patient to be in the success group.

Results were analyzed with unpaired and paired Student *t*-tests, ANOVA, chi-square test, Fisher's exact test, and the Kaplan-Meier life-table method.

## RESULTS

The mean number of needling procedures was 3.0  $\pm$  1.3 (average  $\pm$  standard deviation) in 25 eyes, and ranged from 1 to 5. Five eyes received only a single 5-FU needling revision. Intraocular pressure

**Table 1.** Characteristics of Successfully and Unsuccessfully Needled Eyes

	Complete Success	Qualified Success	Failure	<i>p</i> value
No. of Eyes	10 (40%)	11 (44%)	4 (16%)	
Age (years)	55.0 ; 14.9	53.87 ; 12.54	43.75 ; 8.62	0.343
Gonder M	5	5	2	0.975
F	5	6	2	
IOP before 5-FU (mmHg)	25.3 ; 5.66	27.0 ; 10.21	24.8 ; 8.58	0.856
Final IOP (mmHg)	11.5 ; 4.35	13.82 ; 3.92	32.5 ; 3.70	<0.001
Period (weeks)	3.5 ; 1.08	5.5 ; 5.11	5.5 ; 5.20	0.496
Number of needling	3.3 ; 1.34	2.82 ; 1.08	2.75 ; 2.06	0.668
Medications	2.10 ; 0.58	2.82 ; 0.87	2.75 ; 0.96	0.11
MMC (+/-)	3/7	6/5	2/2	0.509

**Abbreviations:** IOP before 5-FU: IOP before 5-FU needling revision; Final IOP: the mean IOP on the final visit; Period: the period from the trabeculectomy to first 5-FU needling revisions; medications: the number of medications  
 MMC (+/-): the number of cases with intraoperative mitomycin applied in each group.  
*p* value: *p* value of ANOVA or chi-square test.

before the 5-FU needling revision was 25.96 ; 8.10 mmHg with 0.76 ; 0.93 medications and the pressure was 15.88 ; 8.44 mmHg with 1.08 ; 1.15 medications on the final visit. The IOP significantly decreased ( $p < 0.001$ , paired two-tailed *t*-test), while the number of medications did not significantly differ. The follow-up period from the final needling revision was 8.32 ; 6.61 months.

The complete success group included 10 of the 25 eyes (40%) with a final IOP of 11.5 ; 4.35 mmHg (range, 4 to 17 mmHg) after 3.3 ; 1.34 needling revisions (Table 1). The qualified success group included 11 eyes (44%) with a final IOP of 13.82 ; 3.92 mmHg with 1.73 ; 0.79 concurrent medications. The number of needling revisions was 2.82 ; 1.08. Therefore, the total successful rate, including complete and qualified successes, was 84% (21 eyes).

Four eyes (16%) were in the failure group because of no lasting avascular blebs and persistent elevation of intraocular pressure (mean of 32.5 mmHg, with 34, 30, 29, 37 mmHg, respectively, on the final visits). They all received transsclera cyclophotocoagulation as advanced intervention for IOP control. The mean period between the final 5-FU needling revision and cyclophotocoagulation was 6.25 ; 5.85 months (3, 3, 4, and 15 months, respectively). The diagnosis in these 4 cases was post-corneal-graft glaucoma in 3 cases (75%) and traumatic glaucoma in 1 case (25%) (Table 2). However, the failure rate in the post-corneal-graft glaucoma

group did not significantly differ ( $p = 0.81$ , Fisher's exact test) from that of the other groups. No significant difference between primary and secondary glaucoma or between any 2 diagnostic groups was observed.

The number of medications before the trabeculectomy was 2.1 ; 0.58 (range, 1 to 3) in the complete success group, and was 2.8 ; 0.86 (range, 2 to 4) in the others which did not achieve complete success. A significant difference was seen between these 2 groups ( $p = 0.022$ , unpaired, two-tailed *t*-test). However, there was no significant difference between the total success group (2.48 ; 0.81) and failure group (2.75 ; 0.96) ( $p = 0.533$ ).

Mean ages of the complete success, qualified

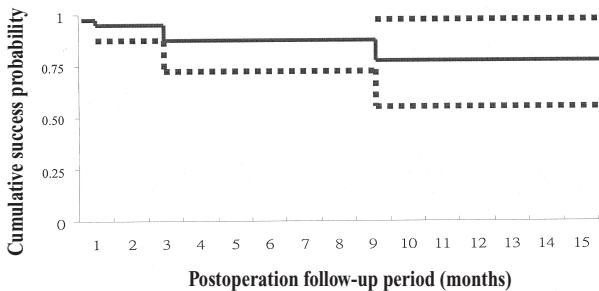
**Table 2.** Preoperative Diagnosis in Different Groups

	Complete Success	Qualified Success	Failure
POAG	1	3	0
PACG	3	1	0
Trauma	3	1	1
PCGG	2	3	3
NVG	1	2	0
Pseudophakia	0	1	0
Total	10	11	4

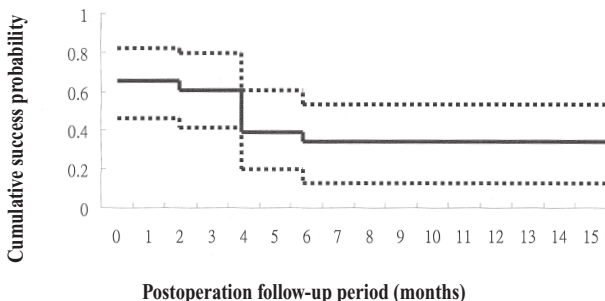
**Abbreviations:** POAG: primary open angle glaucoma; PACG: primary angle-closure glaucoma; Trauma: traumatic glaucoma; PCGG: post-corneal-graft glaucoma; NVG: neovascular glaucoma; Pseudophakia: pseudophakic glaucoma.

success and failure groups were 55; 14.88, 53.87; 12.54, and 43.75; 8.62 years, respectively. There were no significant differences in age among the groups ( $p=0.343$ , ANOVA). The IOP level before 5-FU needling revision, the period from the trabeculectomy to the 5-FU needling revision, and the number of the 5-FU needling revisions did not significantly differ among the groups, either. ( $p=0.856$ , 0.496, and 0.668, respectively; ANOVA). There were also no significant differences among the groups in gender, and whether mitomycin C was used during the trabeculectomy or not ( $p>0.05$ , chi-square test) (Table 1).

Complete success was achieved in 16 eyes (60%) and total success in 24 eyes (96%) in the first month after the final needling revision. The accumulated survival rate of complete success was 33.2% in the 9th month, while total success was 77.6% in the



**Fig. 1** Cumulative survival probability of total success. The solid line represents success probability. The dotted lines represent the 95% confidence intervals.



**Fig. 2** Cumulative survival probability of complete success. The solid line represents cumulative success. The dotted lines represent the 95% confidence intervals.

6th month. The Kaplan-Meier survival curve is illustrated in Figs. 1 and 2.

Complications developed in 14 eyes (56%): corneal epithelial defect in 13, hyphema in 3, and hypotony in one. No conjunctival wound leakage was noted after 5-FU needling revision. The epithelial defects were transient and healed within 1 to 8 weeks. The 3 eyes with epithelial defect were also combined with hyphema, and all instances of hyphema resolved within 4 weeks. The hypotony lasted for 2 weeks with an IOP of less than 0, but no choroidal detachment was detected using sonography. The visual acuity of this eye was counting fingers at 50 cm before the trabeculectomy and counting fingers at 20 cm on the final visit (22 months after surgery).

## DISCUSSION

5-Fluorouracil is a pyrimidine analogue. Its antiproliferative effect is mediated by inhibiting thymidylate synthetase, thus inhibiting DNA synthesis. It acts selectively on the S phase (synthesis) and the G2 phase (growth) corresponding with DNA and RNA synthesis, respectively, in the cell cycle.<sup>(12)</sup> Therefore, cells in the synthesis phase are affected. 5-FU inhibits the proliferation of fibroblasts and also damages proliferating fibroblasts. Lee, et al. studied the effect on cultured human fibroblasts from Tenon's tissue, and treatment resulted in morphological changes followed by cell death.<sup>(13)</sup> Thus subconjunctival fibrosis following filtering surgery, which results in bleb failure, is reduced by 5-FU.

As an adjunctive agent in filtering surgery, 5-FU is used both intraoperatively and postoperatively. The success rate of previous studies ranged from 68% to 95%.<sup>(2,3,6,7,14-18)</sup> We achieved a success rate of 84% in a mean follow-up period of 8.3; 6.6 months by delayed postoperative 5-FU injection. The success rate was similar to those of previous studies.

Heuer, et al. carried out one of the early clinical studies by early postoperative 5-FU injection in 1984.<sup>(14)</sup> Success rates were 69% to 89% in different diagnostic groups of glaucoma patients. The dosage regimen of early postoperative application recommended by the FFSSG is 10 mg of 5-FU daily in the first postoperative week followed by 5 mg per day in the second postoperative week.<sup>(3)</sup> The success rate

was 73% in the 1-year follow-up, but the total dose of the injected 5-FU reached 105 mg. However, the antiproliferation effect not only occurred to the fibroblasts but also to the surrounding proliferating tissue, i.e. the conjunctival and corneal epithelium. The resultant complication rate was high: 33% with conjunctival wound leakage and 85% with corneal epithelial defect.<sup>(3)</sup>

Delayed postoperative 5-FU injection greatly reduced the total amount of the injected dosage. In our study, the mean number of injections was 3; 1.32, and the average of the total injected dose was 15; 6.60 mg. Therefore the complication rate was reduced to no conjunctival wound leakage and 52% with corneal epithelial defect. Previous studies of delayed postoperative 5-FU injection also revealed similar success rates and reduced complication rates. In previous clinical trials by Krug, et al., Hefetz et al., and Mastropasqua et al., success rates were 90%, 83%, 42.8%; conjunctival wound leakage occurred in 0%, 7.1%, and 2.6% of patients; and corneal epithelial defect was seen in 60%, 71.5%, 15%, respectively.<sup>(6-8)</sup>

We combined transconjunctival needling revision before the 5-FU injection. We believe this is a fairly simple and efficient technique to interrupt subconjunctival scarring and restore the bleb space in a failed or failing filtering bleb. Anatomically, the site of failure may be localized to the intraocular, intrascleral, or subconjunctival region, and most of the fibrosis involves the subconjunctival tissue.<sup>(19)</sup> Subconjunctival fibrosis can be well dissected by controlling the power over the needle tip. The effect can also be well visualized and felt by the softening of the eyeball. Ewing, et al. successfully restored the function of failed blebs in 11 of 12 patients by needling revision with or without 5-FU injection.<sup>(9)</sup> Shin, et al. performed needling revision with adjunctive 5-FU in failed blebs with a success rate of 80% in 24 patients.<sup>(10)</sup> Application of 5-FU in encapsulated blebs by Hodge, et al. achieved success in 94% of 17 eyes.<sup>(11)</sup> The diagnoses of patients in these previous studies were mainly primary glaucoma.<sup>(9,10)</sup> Most of our patients had complicated glaucoma, with post-corneal graft glaucoma in 8, traumatic glaucoma in 5, and neovascular glaucoma in 3. Primary cases only numbered 8, around 30% of all, and they demonstrated a similar success rate. This illustrates

that failed blebs can be well treated by this method even in patients with complicated glaucoma.

The overall complication rate in this study was 56%, including corneal epithelial defect in 13, hyphema in 3, hypotony in 1, but with no conjunctival wound leakage. These complications were all transient and manageable. Those were also complications frequently encountered in previous studies. No disastrous complications occurred in our study, such as corneal stromal scarring, spontaneous bleb rupture, hypotony-induced maculopathy, or bleb infection seen in other studies.<sup>(2,3,6-11,20-23)</sup>

The only risk factor associated with failure in this study was the number of antiglaucoma medications used before filtering surgery. High-risk factors of bleb failure in other studies included being aphakic, previously failed filtering surgery, and neovascular and uveitic glaucoma which were not associated with failure in our study; other risk factors included being young, previous cataract surgery, on IOP > 40 mmHg, and being secondary to trauma,<sup>(24-26)</sup> none of which were seen in this study either. In the group achieving complete success, the number of medications before filtering surgery was 2.1; 0.58, and it was 2.8; 0.86 in those eyes in which complete success was not achieved. A significant difference exists between these 2 groups. Ariturk, et al. reported that subconjunctival inflammatory reaction increases as the number of antiglaucoma agents and treatment duration increase.<sup>(27)</sup> Long-term medical therapy using adrenaline or pilocarpine for more than a year was also associated with greater risk of surgical failure in trabeculectomy.<sup>(28)</sup> The use of more antiglaucoma agents may result in a greater inflammatory reaction in the conjunctiva and increased subconjunctival fibrosis, which can lead to the failure of this procedure.

Four eyes were in the failure group in our study. All of these 4 cases had previous ocular surgery. Three eyes had a diagnosis of post-corneal-graft glaucoma, while the other one belonged to the traumatic glaucoma group. However, the statistical analysis showed no significant difference among the diagnostic groups. This may be related to the limited number of cases in our study. Risk factors for failure of 5-FU injection identified in previous studies were the time elapsed since the last procedure involving a conjunctival incision, the number of previous proce-



dures involving conjunctival incisions, secondary angle-closure glaucoma, high preoperative intraocular pressure, trabeculectomy in an inferior location, and prolonged preoperative use of topical sympathomimetic agents.<sup>(5,11)</sup>

Even though the number of patients in our study is limited, we have demonstrated that needling revision with subconjunctival 5-FU injection is an effective and safe method for managing failing filtering blebs in patients with both primary glaucoma and complicated glaucoma. We also suggest that the number of antiglaucoma agents used before filtering surgery is associated with a greater risk of treatment failure. We expect that a larger patient group and further follow-up of this study will yield more information.

## REFERENCES

1. Gressel MG, Parrish RK, Folberg R. 5-Fluorouracil and glaucoma filtering surgery. I. An animal model. *Ophthalmology* 1984;91:378-83.
2. Loon SC, Chew P. A major review of antimetabolites in glaucoma therapy. *Ophthalmologica* 1999;213:234-45.
3. The Fluorouracil Filtering Surgery Study Group. Fluorouracil filtering surgery study one-year follow-up. *Am J Ophthalmol* 1989;108:625-35.
4. The Fluorouracil Filtering Surgery Study Group. Fluorouracil filtering surgery study three-year follow-up. *Am J Ophthalmol* 1993;115:82-92.
5. The Fluorouracil Filtering Surgery Study Group. Fluorouracil filtering surgery study five-year follow-up. *Am J Ophthalmol* 1996;121:349-66.
6. Krug JH, Melamed S. Adjunctive use of delayed and adjustable low-dose 5-fluorouracil in refractory glaucoma. *Am J Ophthalmol* 1990;109:412-8.
7. Hefetz L, Keren T, Naveh N. Early and late postoperative application of 5-fluorouracil following trabeculectomy in refractory glaucoma. *Ophthalmic Surg* 1994;25:715-9.
8. Mastropasqua L, Carpineto P, Ciancaglini M, Zuppari E, Lobefalo L, Gallenga PE. Delayed postoperative use of 5-fluorouracil as an adjunct in medically uncontrolled open angle glaucoma. *Eye* 1998;12:701-6.
9. Ewing RH, Stamper RL. Needle revision with and without 5-fluorouracil for the treatment of failed filtering blebs. *Am J Ophthalmol* 1990;110:254-9.
10. Shin DH, Juzych MS, Khatana AK, Parrow KA. Needling revision of failed filtering blebs with adjunctive 5-fluorouracil. *Ophthalmic Surg* 1993;24:242-7.
11. Hodge W, Saheb N, Balazsi G, Kasner O. Treatment of encapsulated blebs with 30-gauge needling and injection of low-dose 5-fluorouracil. *Can J Ophthalmol* 1992;27:233-6.
12. Hartman KU, Heidelberger C. Studies on fluorinated pyrimidines. XIII. Inhibition of thymidylate synthetase. *J Biol Chem* 1961;236:3006-13.
13. Lee DA, Tehrani ST, Kitada S. The effect of 5-fluorouracil and cytarabine on human fibroblasts from Tenon's capsule. *Invest Ophthalmol Vis Sci* 1990;31:1848-58.
14. Heuer DK, Parrish PK II, Gressel MG. 5-Fluorouracil and glaucoma filtering surgery. II. A pilot study. *Ophthalmology* 1984;91:384-94.
15. Egbert PR, Williams AS, Singh K. A prospective trial of intraoperative fluorouracil during trabeculectomy in a black population. *Am J Ophthalmol* 1993;116:612-6.
16. Ophir A, Ticho U. Filtering surgery with 5-fluorouracil: A second course. *Eye* 1990;4:819-22.
17. Ticho U, Ophir A. Regularizing the dose of 5-fluorouracil to prevent filtering bleb scarring. *Ann Ophthalmol* 1991;23:225-9.
18. Beckman RL, Sofinski SH, Greff LH. Bandage contact lens augmentation of 5-fluorouracil treatment in glaucoma filtration surgery. *Ophthalmic Surg* 1991;22:563-4.
19. Maumenee AE. External filtering operations for glaucoma. The mechanism of function and failure. *Trans Am Ophthalmol Soc* 1960;58:319.
20. Araie M, Shoji N, Shirato S, Nakano Y. Postoperative subconjunctival 5-fluorouracil injections and success probability of trabeculectomy in Japanese. Results of 5-year follow-up. *Jpn J Ophthalmol* 1992;36:158-68.
21. Franks WA, Hitchings RA. Complications of 5-fluorouracil after trabeculectomy. *Eye* 1991;5:385-9.
22. Wolner B, Liebmann JM, Sassani JW. Late bleb-related endophthalmitis after trabeculectomy with adjunctive 5-fluorouracil. *Ophthalmology* 1991;98:1053-6.
23. Stamper RL, McMenemy MG, Lieberman MF. Hypotonous maculopathy after trabeculectomy with subconjunctival 5-fluorouracil. *Am J Ophthalmol* 1992;114:544-53.
24. Chen CW, Huang HT, Lee CC. Trabeculectomy with simultaneous topical application of mitomycin-C in refractory glaucoma. *J Ocul Pharmacol* 1990;6:175-8.
25. Sturmer J, Broadway DC, Hitchings RA. Young patient trabeculectomy: Assessment of risk factors for failure. *Ophthalmology* 1993;100:928-39.
26. Whiteside MJ, Liebmann JM, Ritch R. Initial 5-fluorouracil trabeculectomy in young patients. *Ophthalmology* 1992;99:7-13.
27. Ariturk N, Oge I, Baris S, Erkan D, Sullu Y, Koc F. The effects of antiglaucomatous agents on conjunctiva used for various durations. *Internat Ophthalmol* 1996;20:57-62.
28. Broadway DC, Grierson I, O'Brien C, Hitchings RA. Adverse effects of topical antiglaucoma medication. II. The outcome of filtration. *Arch Ophthalmol* 1994;112:1446-54.

# 以針頭修整法合併五氟尿嘧啶結膜下注射 改善失敗的青光眼小樑切除術

張雪麗 侯鈞賀

**背景：**五氟尿嘧啶為一抗代謝藥物，能抑制結膜下纖維化，增進小樑切除術之成功率，但於術後早期使用五氟尿嘧啶亦可能使併發症之機會增加。本文研究藥物控制不良之青光眼病患，於小樑切除術後濾過失敗時，施以結膜下注射五氟尿嘧啶合併針頭修整之結果。

**方法：**我們使用針頭修整法合併五氟尿嘧啶結膜下注射於小樑切除術後房水濾過失敗之病患共24人，25隻眼。術前診斷為原發性隅角閉鎖性青光眼4人，原發性隅角開放性青光眼4人，角膜移植術後青光眼8人，外傷性青光眼5人，血管增生性青光眼3人，人工水晶體植入性青光眼1人。結膜下注射五氟尿嘧啶合併針頭修整實施時間，平均為小樑切除術後 $5.0 \pm 4.0$ 週。

**結果：**平均追蹤期為 $8.3 \pm 6.6$ 個月。共接受 $3.2 \pm 1.2$ 次注射，完全成功有10隻眼睛(佔40%)；部分成功的有11隻眼睛(佔44%)；所有成功的總和為21隻眼(佔84%)。注射前眼壓為 $25.98 \pm 8.10$ 毫米汞柱，最後一次回診平均眼壓為 $15.88 \pm 8.44$ 毫米汞柱。主要併發症為暫時性眼壓過低1人，角膜表皮缺損13人，前房出血3人。

**結論：**本研究支持五氟尿嘧啶在小樑切除術後作為輔助療法，延後注射的有效性及安全性。

(長庚醫誌 2002;25:97-103)

**關鍵字：**五氟尿嘧啶，青光眼，小樑切除術，針頭修整法。